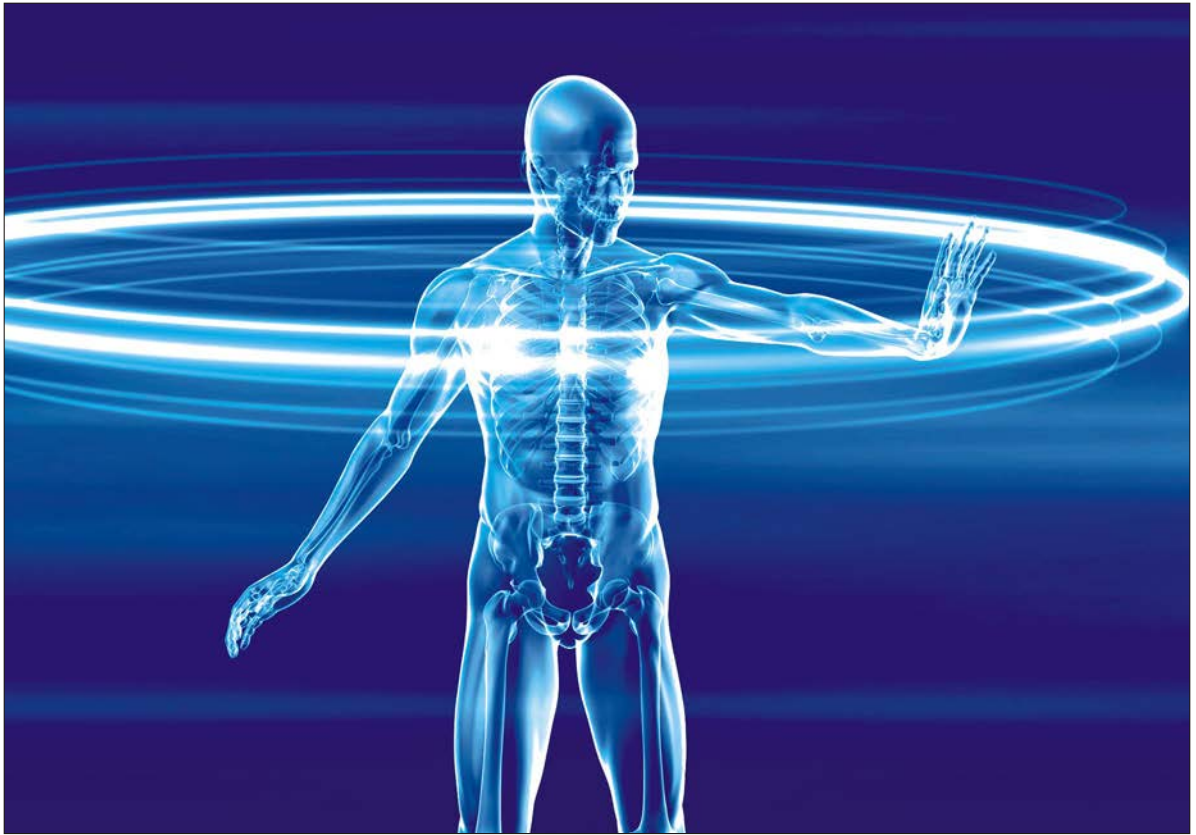

Research Journal of Immunology

ISSN 1994-7909

science
alert

ANSI*net*
an open access publisher
<http://ansinet.com>

Gastro Protective and Antioxidant Activity of *Solanum nigrum* Linn. against Aspirin and Cold Restraint Stress induced Ulcerated Rats

¹S. Saravanan, ²P. Dhasarathan, ³V. Indira and ¹R. Venkatraman

¹P.G. and Research Department of Chemistry, Sri Paramakalyani College, Alwarkurchi-627 412, India

²Department of Biotechnology, Prathyusha Institute of Technology and Management Thiruvallur-602 025, India

³Department of Biochemistry, Sri Parasakthi College, Courtallam-627 802, India

Corresponding Author: S. Saravanan, P.G. and Research Department of Chemistry, Sri Paramakalyani College, Alwarkurchi-627 412, India

ABSTRACT

Present study investigated gastroprotective and antioxidant activity of *Solanum nigrum* Linn. using aspirin and cold resistant stress induced ulcer rats. The collected plant leaves extracted with methanol by Soxhlet method for further analysis. Test animals were acclimatized in laboratory conditions and divided into six groups (Positive control (aspirin treated), negative control (normal), *S. nigrum* Extract (SNE) administered and aspirin, Cold Restraint Stress (CRS), *S. nigrum* with cold restraint stress and famotidine (standard drug) administered). The test animals were treated upto 20 days, after treatment gastric juice obtained from stomach used for biochemical and enzymatic analysis. The standard methodologies were adopted to found the parameters such as level of protein, carbohydrate, ulcer index, % of inhibition, ulcer severity, DPPH scavenging activity and reducing sugar etc. The gastric walls of all groups were used for histopathological studies. From the findings the groups that were treated to aspirin and CRS produced less gastric mucus secretion in gastric juice (101.39 and 91.67 mg g⁻¹, respectively). The groups pretreated with *S. nigrum* extract exhibited a percentage inhibition of about 77.85% in aspirin and 66.67% in CRS-treated, groups, respectively. However, in groups that were pretreated with famotidine the percentage inhibition was 88.91%. Higher percentage of inhibition (88.91%) observed in groups pretreated with Famotidine. The reduction capability of DPPH radicals was determined from the decreasing absorbance values at 517 nm with increasing concentration, which is induced by anti oxidants present in the extracts. The plant extracts remarkably change all the parameters screening in test animals. Biochemical, antioxidants, histological and enzymological results also show the gastro protective and antioxidant efficiency of test plant. In nutshell the plant methanolic extracts have potential drug against gastro protective and Ulcer.

Key words: *Solanum nigrum*, gastro protective effect, anti-ulcer, anti oxidant, histology

INTRODUCTION

Gastric ulcer disease is a chronic inflammation, raw eroded area in the lining of the stomach, where parietal cells are found that secrete hydrochloric acid and pepsin. The anatomic sites where ulcers, commonly found are stomach and duodenum, causing gastric and duodenal ulcer, respectively (Kanner and Lapidol, 2001). Pathophysiology of ulcer is due to an imbalance between aggressive factors (acid, pepsin, *Helicobacter pylori* and NSAIDs) and local mucosal defensive

factors (mucin bicarbonate, blood flow and prostagladins). Integrity of gastric mucosa is maintained through a homeostatic balance between these factors (Hoogerwerf and Pasricha, 2001). One major cause of gastric ulceration in human and experimental animals is the chronic use of NSAIDs in the treatment of mild to moderate pain.

Aspirin is one of such NSAIDs and its main undesirable side effect is that it will induce gastrointestinal ulcers, stomach bleeding and tinnitus, especially in higher dosage. Several drugs are widely used to prevent or treat gastric ulcer, which include H₂ receptor antagonists such as Cimetidine, Famotidine, Ranitidine and proton-pump inhibitors such as Sucralfate, Tetracycline and Pepto-Bismol. Due to problems associated with recurrence after treatment, there is the need to seek alternative drug sources against gastric ulcers.

Traditional systems of medicine continue to be widely practiced on many accounts. Population rise, inadequate supply of drugs, prohibitive cost of treatments, side effects of several allopathic drugs and development of resistance to currently used drugs for infectious diseases have led to increased emphasis on the use of plant materials as a source of medicines for a wide variety of human ailments (Arrieta *et al.*, 2001; Manjula *et al.*, 2009). Global estimates indicate that 80% of about 4 billion population cannot afford the products of the Western Pharmaceutical Industry and have to rely upon the use of traditional medicines, which are mainly derived from plant material (Brindhha *et al.*, 2008). There are scanty reports on its antibacterial activities of chosen test plant. In order to demonstrate the antibacterial efficacy, test were conducted against human pathogenic bacteria including those responsible for causing inflammation.

Solanum nigrum is an herbal plant which is distributed as a weed throughout dry parts of India. It has the properties such as emollient, diuretic and laxative (Al-Daihan, 2008). The leaves are used for the treatment of diabetes, heart problems and jaundice. This study was therefore undertaken to analyze gastro-protective effect and *in vitro* antioxidant activity of *S. nigrum* and its effect on acid-pepsin secretion mucus content, acidity in aspirin-induced ulcerogenesis and Cold Restraint Stress (CRS) induced ulcerated rats.

Plants also need to protect themselves from free radical damages with the help of their own metabolites, so they develop a number of different classes of antioxidants. In this study, those antioxidant activities of *S. nigrum* Linn. extracts were analyzed by various methods such as reducing power determination.

MATERIALS AND METHODS

Plant sample: In the present study, *Solanum nigrum* Linn. were selected as the plant sample and collected at Sri Paramakalyani Medicinal garden, Alwarkurichi (Tirunelveli district, Tamilnadu, India) in early morning during second week of January, 2010. The collected samples were immediately transported to the Chemistry Laboratory, Alwarkurichi for plant extraction and phytochemical screening. Animal study was carried out in Biotechnology Laboratory, Prathyusha Institute of Technology and Management, Tiruvallur using plant extracts. The leaves of *S. nigrum* were dried and coarsely powdered. It was then extracted using methanol as solvent in Soxhlet apparatus. The extract obtained was then filtered through Whatman filter paper No. 3 and was then evaporated at 40-50°C with reduced pressure. Dosage of about 500 mg kg⁻¹ b.wt. *S. nigrum* extract was given to the rats of group III and group V animals. Dose was administered orally everyday for 20 consecutive days.

Animals: Albino wistar rats weighed about 140-150 g were used in the present investigation. The rats were fed with standard laboratory rat pellet feed (Lipton Ltd., Mumbai) and water provided

to *ad libitum*. After acclimatization, the rats are divided into six groups (Each groups contains six animals) used for analysis.

- **Group I:** Serves as negative control, which was provided with normal feed with *ad libitum* water
- **Group II:** Serves as positive control, which was fed with normal feed and on the last day, aspirin (200 mg kg⁻¹ b.wt.) dissolved in 1% CMC was administered orally
- **Group III:** Pretreated orally with *S. nigrum* Linn. Extract (500 mg kg⁻¹ b.wt.) for consecutively 20 days and on the last day aspirin (200 mg kg⁻¹ b.wt.) dissolved in 1% CMC was administered orally
- **Group IV:** Provided with normal feed and on the last day, the animals were fasted for 6 h and then subjected to Cold Restraint Stress for 2 h
- **Group V:** Pretreated orally with *S. nigrum* extract (500 mg kg⁻¹ b.wt.) for consecutively 20 days and on the final day, the animals were fasted for 6 h and then subjected to Cold Restraint Stress for 2 h
- **Group VI:** Pretreated orally with famotidine for 20 consecutive days and on the final day, aspirin (200 mg kg⁻¹ b.wt.) dissolved in 1% CMC was administered orally

By the next day, animals of all the groups were fasted and were sacrificed. The stomach was cut along the greater curvature and the contents were collected and centrifuged at 3000 rpm for 10 minutes and the supernatant (gastric juice) was used for biochemical and enzymatic analysis. The gastric walls of all groups were used for histopathological studies, like Ulcer index determination, percentage inhibition and Non-Protein Sulphydryl Group (NPSH) estimations.

The biochemical estimations of total proteins, total carbohydrates, gastric mucus determination (Corney *et al.*, 1974), non-protein sulphydryl groups (Sedlak and Lindsay, 1968), total acidity (Cannon, 1969), volume and pH (Parmer and Desai, 1993), DPPH radical scavenging activity (0.0025 g of 2, 2-Diphenyl-1-picryl hydrazyl (DPPH) was dissolved in 25 mL of methanol. The content should be made and kept in dark condition, because DPPH is light sensitive and reducing sugar were analyzed by standard methods, ascorbic acid used as a standard for both tests.

The phytochemicals present in the extract was analyzed by Sofowara (1993), Ulcer index, percentage inhibition (Kaukmann and Grosmann, 1978) and ulcer severity (Varley *et al.*, 1991) were carried out to screen the efficiency.

The enzymatic analysis was performed by using hemoglobin method and the enzymes analyzed include pepsin, trypsin and Cathepsin (Anson, 1938).

Histological studies: The gastric wall cut along the greater curvature from each group of rats was fixed in 10% formalin for 24 h. The formalin fixed specimen was embedded in paraffin, sectioned and stained with hematoxylin and eosin. The histochemical sections were evaluated by light microscopy.

RESULTS

The present study suggests that pretreatment with *S. nigrum* extract ameliorated the ulcer index, histological and biochemical changes induced by aspirin and cold restraint stress gastric ulceration in rats. The level of proteins and carbohydrates were found in the treated animals were 361.05 and 195.71 mg dL⁻¹ in group I, 342.63 and 90.05 mg dL⁻¹ in group II, 345.79 and 123.57 mg dL⁻¹ in group III, 340.78 and 104.29 mg dL⁻¹ in group IV, 347.63 and 138.57 mg dL⁻¹ in group V, 354.21 and 167.86 mg dL⁻¹ in group VI (Table 1). It is proved that there is a little effect

Table 1: Effect of *Solanum nigrum* Linn extract on gastric mucosal factors in experimental gastric ulcer model

Parameters	Groups					
	I	II	III	IV	V	VI
Total proteins (mg dL ⁻¹)	361.05	342.63	345.79	340.78	347.63	354.21
Total carbohydrates (mg dL ⁻¹)	195.71	90.05	123.57	104.29	138.57	167.86
Gastric mucus content (mg g ⁻¹ of tissues)	136.11	101.39	116.67	91.67	113.89	133.33
NPSH Groups (nM g ⁻¹ of tissues)	427	158	315	132	307	438
Total acidity (mEq L ⁻¹)	31	45	35	47	36	32.3
Volume (mL)	1.9	2.54	2.19	2.67	2.38	2.07
pH	2.8	1.7	4.3	1.3	3.5	3.8
Ulcer index	0.0	3.472	0.769	4.615	1.538	0.385
% of inhibition	-	-	77.85	-	66.67	88.91
Severity of ulcer	0	+++	+	++++	+	+
Pepsin output (mEq tyr)	9.58	12.737	9.98	21.511	13.44	11.26
Trypsin output (mEq tyr)	10.52	18.98	14.24	23.05	14.89	11.26
Cathepsin output (mEq tyr)	1.45	11.95	8.57	16.982	11.52	9.78

∴ Nil value, +: Less severity of ulcer, +++: Moderate severity of ulcer, ++++: High severity of ulcer

in the amount of proteins and carbohydrates during ulceration. Protein malnutrition results when the body's needs for protein cannot be satisfied by the diet. Since all normal metabolic processes require proteins; all tissues will be affected by a state of protein deprivation. This protein deprivation due to stress and adequate usage of NSAIDs was overcome by an increase in protein level in the groups that were pretreated with *S. nigrum* Linn. extract.

The groups that were treated to induce ulcer produced less gastric mucus secretion in gastric juice, whereas the groups that were pretreated with plant extract and antiulcer drug showed an increase in gastric mucus secretion. The test animal secretion of gastric mucus was reduced in positive control aspirin treated group have 101.39 mg g⁻¹ tissue and cold resistant stress exposed group show 91.67 mg g⁻¹ compared with negative control group (136.11 mg g⁻¹ tissue) and Famotidine treated group (133.33 mg g⁻¹ tissue) (Table 1). Ulcer induced however, plant extract treated groups show moderate changes in between positive and negative control animal groups (116.67 and 113.89 mg g⁻¹ tissue of gastric mucus obtained in group III and group V, respectively). It reported that the gastric mucosa consists of mucin-type glycoprotein, which can be detected by the amounts of Alcian blue. Mucin is a viscous glycoprotein, with physicochemical properties producing relatively resistant acid barrier. In pretreated groups, there is an increase in gastric mucosal secretion indicating the anti secretory effect of *S. nigrum* Linn. extract and famotidine.

There is a decrease in the concentration of NPSH group in pretreated groups such as group III (315 nM g⁻¹), group V (307 nM g⁻¹) and group VI (438 nM g⁻¹) than that in ulcerated groups II (158 nM g⁻¹) and group IV (132 nM g⁻¹), when compared with normal animal (427 nM g⁻¹) (Table 1). Gastric mucosal NPSH group was measured to analyze the oxidant/antioxidant balance. The basal gastric secretion and titratable acidity were suppressed in pretreated groups than the ulcerated group (Table 1). Therefore, it appears this extract is more effective and possesses cyto secretory capacity. Suppression in the total acidity and the pH of the gastric juice of pretreated groups was higher than the ulcerated group that was reported. The normal animal (Untreated) gastric juice total acidity was 31 mEq L⁻¹ and pH was 2.8, aspirin administered animal gastric juice total acidity was 45 mEq L⁻¹ and pH was 1.7, plant extract with aspirin administered animal gastric juice total acidity was 35 mEq L⁻¹ and pH was 4.3, cold resistant stress induced animal gastric juice total acidity was 47 mEq L⁻¹ and pH was 1.3, plant extract with cold resistant stress induced animal

gastric juice total acidity was 47 mEq L⁻¹ and pH was 1.3 and famotidine administered animal gastric juice total acidity was 32.3 mEq L⁻¹ and pH was 3.8 (Table 1). This is due to the fact that the increased amount of gastric mucus secretion gets combined with low acid content; hence the pH is high in pretreated groups.

Ulcer index is in one of the better confirmation test for ulceration, next to the endoscopy/histopathology studies. The pretreated rats showed significant reduction in the ulcer index values, which suggests that the *S. nigrum* extract possesses cytoprotective activity. The groups pretreated with *S. nigrum* extract exhibited a percentage inhibition of about 77.85% in aspirin and 66.67% in CRS-treated, groups, respectively. However, in groups that were pretreated with famotidine the percentage inhibition was 88.91%. Higher percentage of inhibition (88.91%) observed in groups pretreated with Famotidine it cannot be used to arrive at a conclusion that famotidine has higher ulcer protection ability as many commercial drugs produced many side effects than the extract. Increase in the concentration of the extract may improve the percentage of inhibition without any side effects.

A histological study revealed that, the pretreatment with *S. nigrum* extract helped to preserve the cyto-architecture of the entire gastric mucosa of test animals. *S. nigrum* extract treatment not only maintenance of gastric mucosa helped but also the regeneration of gastric mucosa in the damaged regions. These findings confirmed the gastro protective activity of *S. nigrum* extract (Fig. 1-6). The normal animal gastric mucosa histological section was showed clear and proper arrangement of cells (Fig. 1). The cells were damaged and created opaque region in gastric mucosa of both (Aspirin and cold resistant stress) ulcer induced animal groups (Fig. 2, 3). The standard gastroprotective drug of famotidine effectively replaces damaged cells in ulcer induced animals gastric mucosa layer (Fig. 4). The plant extract administered animal shows replacement of ulcerative cells and moderately arrange proper layer in gastric mucosa (Fig. 5, 6).

The methanolic fraction of *S. nigrum* was found to contain 64.7 µg pyrocatechol equivalents of phenols. The phenolic compounds may contribute directly to the antioxidant actions. Oxidative stress plays a major role in the pathogenesis of various diseases including gastric ulcers. Oxidative stress can damage many biological molecules. Anti-oxidants have been found to play a significant

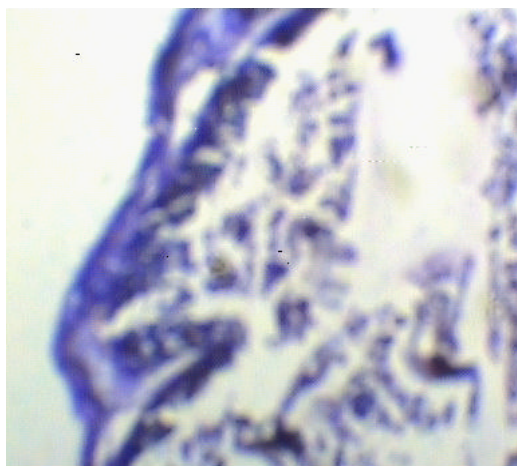


Fig. 1: Histological section of gastric mucosa from negative control animals

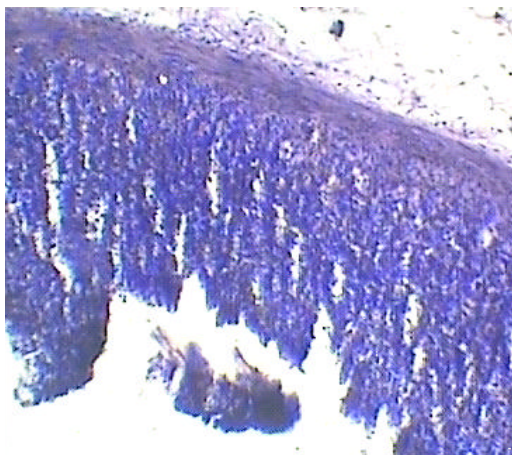


Fig. 2: Histological section of gastric mucosa from aspirin treated animals

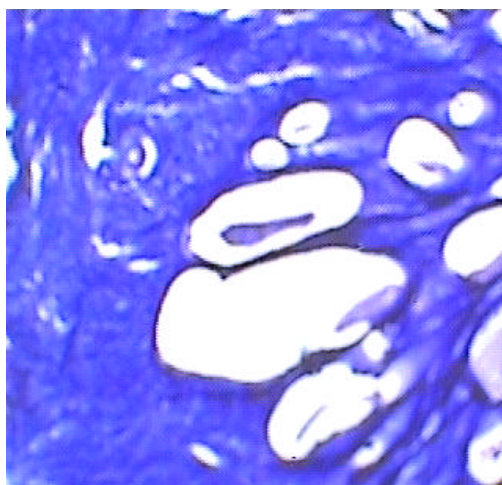


Fig. 3: Histological section of gastric mucosa from CRS treated animals

role in preventing gastric ulcers. It has appeared that antioxidants may be an important contributory factor in the protection of gastric mucosa. DPPH is a stable free radical at room temperature that accepts an electron or H_2 radical to become a stable diamagnetic molecule. The reduction capability of DPPH radicals was determined from the decreasing absorbance values at 517 nm with increasing concentration, which is induced by anti oxidants present in the extracts. The maximum (79.84%) percentage DPPH scavenging activity was obtained 1000 $\mu\text{g mL}^{-1}$ plant extract administered animal, followed by 800 $\mu\text{g mL}^{-1}$ (58.68%), 600 $\mu\text{g mL}^{-1}$ (33.06%), 400 $\mu\text{g mL}^{-1}$ (28.93%) and 200 $\mu\text{g mL}^{-1}$ (25.62%). The Fe^{3+} - Fe^{2+} transformation has been investigated (Table 2). The reducing power of methanol extract of plant was increased with the increased amount of the sample. The predominant amount of reducing sugar obtained in 1000 $\mu\text{g mL}^{-1}$ followed by 800, 600, 400 and 200 $\mu\text{g mL}^{-1}$ concentrations of extracts (Table 3).

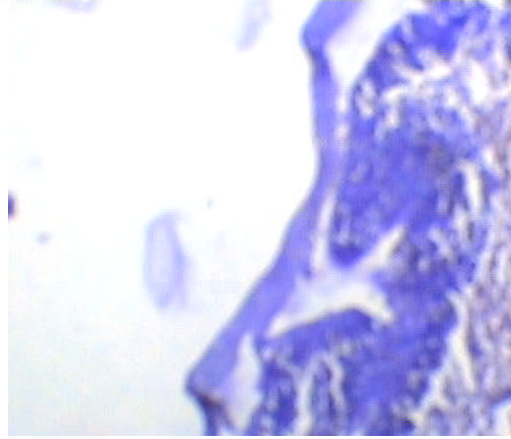


Fig. 4: Histological section of gastric mucosa from Famotodine +ASP treated animals

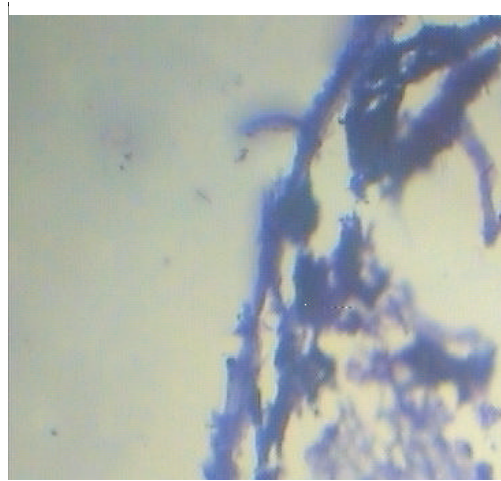


Fig. 5: Histological section of gastric mucosa from *Solanum nigrum* linn, +ASP treated animals

Table 2: DPPH scavenging activity of *S. nigrum* methanolic extract

Quantity of the fraction used ($\mu\text{g mL}^{-1}$)	DPPH scavenging activity (%)	
	SNE	Ascorbic acid
200	25.62	200
400	28.93	400
600	33.06	600
800	58.68	800
1000	79.84	1000

Phenolic compounds are known as powerful chain breaking anti oxidants, due to the presence of their hydroxyl groups. As a result of anti oxidant analysis, it was suggested that the increased amount of antioxidants present in the extract might be responsible for its gastro protective and antiulcer activity.

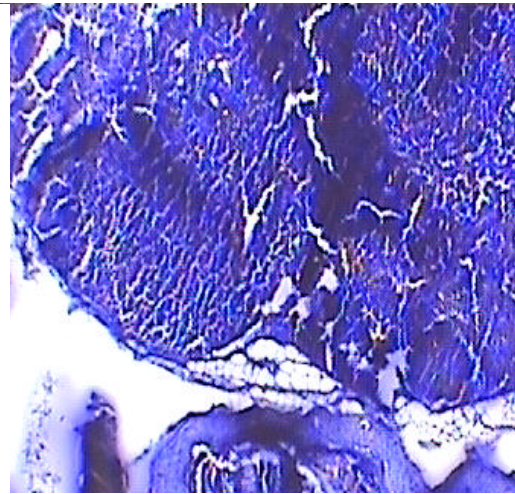


Fig. 6: Histological section of gastric mucosa from *Solanum nigrum* linn, + CRS treated animals

Table 3: Reducing power of *S. nigrum* methanolic extract

Quantity of the fraction used ($\mu\text{g mL}^{-1}$)	Reducing power (absorbance at 700 nm)	
	SNE	Ascorbic acid
200	0.498	1.022
400	0.723	1.056
600	1.038	1.202
800	1.121	1.258
1000	1.235	1.283

DISCUSSION

Peptic Ulcer Disease (PUD) is one of the common diseases. The causes of peptic ulcer disease are increased gastric acid secretion and reduced gastric cytoplasm. PUD occurs mainly due to consumption of Non Steroidal Anti Inflammatory Drugs (NSAIDs), infection by *Helicobacter pylori*, stress or due to pathological conditions such as Zollinger-Ellison syndrome. Non steroidal Anti-inflammatory drugs associated gastric ulceration occurs in 30% of users that led to hospitalization and also associate with high mortality. Hence, there is a need for more effective and less toxic antiulcer agents, plants extract are some of the most attractive sources.

In this study, the methanolic extract of *S. nigrum* was used for the treatment of ulcer. The reducing power of methanol extract of plant was increased with the increased amount of sample. Phenolic compounds are known as powerful chain breaking anti oxidants, due to the presence of their hydroxyl groups. It was suggested that the increased amount of antioxidant present in the extract might be responsible for its gastro protective and anti ulcer activity. The similar results of the present study found in ethanolic extract of Amla have the capacity to significantly inhibit the basal gastric secretion and ulcerogenicity induced by pylorus ligation, indomethacin and noxious chemicals and by hypothermic restraint stress in rats (Jose and Kuttan, 2000; Yesilada *et al.*, 2000). Pepsin is one of three principal protein-degrading, or proteolytic, enzymes in the digestive system, the other two being chymotrypsin and trypsin and HCl are important for the formation of pylorus ligated ulcers (John and Onabanjo, 1990; Tan *et al.*, 2000). The gastric protective effect of

the extract be related to an antacid effect or cytoprotective properties of the plants (Rifat-uz-Zaman *et al.*, 2004; Naseri and Mard, 2007). It is possible that the inhibitory effect of the plants is due, at least partly, to the presence of tannins, terpenes and fatty acids since these compounds were associated with anti-ulcerogenic activity in other plants (Campos *et al.*, 2003; Hiruma-Lima *et al.*, 2001; Sehirli *et al.*, 2008; Khanahmadi *et al.*, 2010).

Our findings are supported with Bandyopadhyay *et al.* (2000), as our results showed a significant reduction in non-protein sulfhydryls (NP-SH) content of gastric mucosa after 80% ethanol administration. This result suggests that *S. nigrum* extract has active substance(s) that increase the mucosal sulfhydryl groups content. In another hypothesis, this activity could be attributed to antioxidant compounds found in the alcoholic extract (Dias *et al.*, 2000; Mahmoud *et al.*, 2006; Akah *et al.*, 2007; Gill *et al.*, 2009). The results on histopathological investigation on the gastric mucosa of rats revealed that the pretreatment with *S. nigrum* extract absolutely inhibited the ethanol-induced congestion, hemorrhage, edema, necrosis, inflammatory and dysplastic changes, erosions and ulceration. Present results are in corroboration with the antigastric ulcer activity of the extract observed under the studies on pharmacological and biochemical evaluation.

CONCLUSION

The extracts of the leaves of *S. nigrum* is potentially an anti ulcerogenic agent that protects and strengthens the gastric mucosa. The exact mechanism was not known, but it could be due to secretion of large quantity of mucous by the gastric mucosa that acts as a mechanical barrier. From the results, percentage of inhibitory effect and ulcer index, it is confirmed and concluded that *S. nigrum* has the anti-ulcer activity. Moreover, there is a need to conduct toxicity studies, using the plant extract on both laboratory and target animal species, to justify clinical investigation in other animals and in humans.

REFERENCES

- Akah, P.A., L. John-Africa and C.S. Nworu, 2007. Gastoprotective properties of the leaf extracts of *Ocimum gratissimum* L. against experimental ulcers in rats. *Int. J. Pharmacol.*, 3: 461-467.
- Al-Daihan, S., 2008. Measurement of selected enzymatic activities in *Solanum nigrum*-Treated *Biomphalaria arabica* snails. *J. Applied Sci.*, 8: 881-885.
- Anson, M.L., 1938. The estimation of pepsin, trypsin, papain and cathepsin with hemoglobin. *J. Gen. Physiol.*, 22: 79-89.
- Arrieta, J., B. Reyes, F. Calzada, R. Cedillo-Riveva and A. Navarrete, 2001. Amoebicidal and giardicidal compound from the leaves of *Zanthoxylum liebmannianum*. *Fitoterapia*, 72: 295-297.
- Bandyopadhyay, S.K., S.C. Pakrashi and A. Pakrashi, 2000. The role of antioxidant activity of *Phyllanthus emblica* fruits on prevention from indomethacin induced gastric ulcer. *J. Ethnopharmacol.*, 70: 171-176.
- Brindha, P., G. Sridharan, V. Pradeep and S. Sasikumar, 2008. Antitumor activity and *in vivo* antioxidant status of *Hyptis suaveolens* against *Ehrlich ascites* carcinoma in swiss albino mice. *Ind. Drug*, 45: 10-10.
- Campos, A.R., A.I. Barros, F.A. Santos and V.S. Rao, 2003. Guarana (*Paullinia cupana* Mart.) offers protection against gastric lesions induced by ethanol and indomethacin in rats. *Phytother. Res.*, 17: 1199-1202.

- Cannon, D.C., 1969. Examination of Gastric and Duodenal. In: Clinical Diagnosis by Laboratory Methods, Davidson, I. and J.B. Henry (Eds.). WB Saunders Co., Philadelphia, pp: 762-84.
- Corney, S.J., S.M. Morrissey and R.J. Woods, 1974. Proceedings: A method for the quantitative estimation of gastric barrier mucus. *J. Physiol.*, 242: 116-117.
- Dias, P.C., M.A. Foglio, A. Possenti and J.E. de Carvalho, 2000. Antiulcerogenic activity of crude hydroalcoholic extract of *Rosmarinus officinalis* L. *J. Ethnopharmacol.*, 69: 57-62.
- Gill, N.S., M. Garg, R. Bansal, S. Sood, A. Muthuraman, M. Bali and P.D. Sharma, 2009. Evaluation of antioxidant and antiulcer potential of *Cucumis sativum* L. seed extract in rats. *Asian J. Clin. Nutr.*, 1: 131-138.
- Hiruma-Lima, C.A., J.S. Gracioso, W. Toma, A.B. Almeida and A.C.B. Paula *et al.*, 2001. Gastroprotective effect of aparisthman, a diterpene isolated from *Aparisthium cordatum*, on experimental gastric ulcer models in rats and mice. *Phytomedicine*, 8: 94-100.
- Hoogerwerf, W.A. and P.J. Pasricha, 2001. Agents Used for Control of Gastric Acidity and Treatment of Peptic Ulcer and Gastro Esophageal Reflux Disease. In: Goodman and Gilman's the Pharmacological Basis of Therapeutics, Hardman, J.G. and L.E. Limbird (Eds.). McGraw Hill, New York, pp: 1005-1020.
- John, T.A. and A.O. Onabanjo, 1990. Gastroprotective effects of an aqueous extract of *Entandrophragma utile* bark in experimental ethanol-induced peptic ulceration in mice and rats. *J. Ethnopharmacol.*, 29: 87-93.
- Jose, J.K. and R. Kuttan, 2000. Hepatoprotective activity of *Emblica officinalis* and chyavanaprash. *J. Ethnopharmacol.*, 72: 135-140.
- Kanner, J. and T. Lapidol, 2001. The stomach as a bioreactor: Dietary lipid peroxidation in gastric fluid and effects of plant derived anti-oxidants. *Free Rad. Biol. Med.*, 31: 1388-1395.
- Kaukmann, G.L. and M.I. Grosmann, 1978. Prostaglandin and imetidine inhibits the formation of ulcer produced by parental salicylates. *Gastroenterology*, 75: 1099-1102.
- Khanahmadi, M., S.H. Rezazadeh and M. Taran, 2010. *In vitro* antimicrobial and antioxidant properties of *Smyrniium cordifolium* Boiss. (Umbelliferae) extract. *Asian J. Plant Sci.*, 9: 99-103.
- Mahmoud, A.H., H.M. Motawa, H.E. Wahba and A.Y. Ebrahim, 2006. Study of some antioxidant parameters in mice livers affected with *Urtica pilulifera* extracts. *Asian J. Biochem.*, 1: 67-74.
- Manjula, M., V. Indira and P. Dhasarathan, 2009. Phytochemical characterization and antibacterial activity screening of *Achyranthes aspera*. *Asian J. Microbiol. Biotechnol. Environ. Sci.*, 11: 365-368.
- Naseri, M.K.G. and S.A. Mard, 2007. Gastroprotective effect of alhagi maurorum on experimental gastric ulcer in rats. *Pak. J. Med. Sci.*, 23: 570-573.
- Parmer, N.S. and J.K. Desai, 1993. A review of the methodology for the evaluation of gastric and duodenal ulcer agents. *Indian J. Pharmacol.*, 25: 120-135.
- Rifat-uz-Zaman, M.S. Akthar and M.S. Khan, 2004. Gastoprotective and antisecretory effect of *Nigella sativa* seed and its extracts in indomethacin treated rats. *Pak. J. Biol. Sci.*, 7: 995-1000.
- Sedlak, J. and R.H. Lindsay, 1968. Estimation of total protein bound and non protein sulfhydryl groups in tissue with Ellmans reagent. *Anal. Biochem.*, 25: 192-205.
- Sehirli, O., E. Tatlıdede, M. Yuksel, C. Erzik, S. Cetinel, B.C. Yegen and G. Sener, 2008. Antioxidant effect of alpha-lipoic acid against ethanol-induced gastric mucosal erosion in rats. *Pharmacology*, 81: 173-180.

- Sofowara, A., 1993. Recent trends in research into African Medicinal plants. *J. Ethnopharmacol.*, 38: 209-214.
- Tan, P.V., V.B. Penlap, B. Nyasse and J.D.B. Nguemo, 2000. Antiulcer actions of the bark methanol extract of *Voacanga africana* in different experimental ulcer models in rats. *J. Ethnopharmacol.*, 73: 423-428.
- Varley, H., A.H. Gowenlock and M. Bell, 1991. *Practical Clinical Biochemistry*. 5th Edn., CBS Publishers, New Delhi, India,.
- Yesilada, E., Y. Takaishi, T. Fujita and E. Sezik, 2000. Anti-ulcerogenic effects of *Spartium junceum* flowers on *in vivo* test models in rats. *J. Ethnopharmacol.*, 70: 219-226.