

## Delayed Primary Closure of Omphaloceles: A Minimal-Invasive Treatment Strategy

<sup>1</sup>Martin M. Kaiser, <sup>2</sup>Martina Kohl, <sup>1</sup>Kianusch Tafazzoli, <sup>3</sup>Andreas Paech,  
<sup>3</sup>Arndt P. Schulz and <sup>1</sup>Lucas M. Wessel

<sup>1</sup>Department of Pediatric Surgery,

<sup>2</sup>Department of Pediatrics,

<sup>3</sup>Department of General and Trauma Surgery, Hospital of the University Schleswig-Holstein,  
Campus Lübeck, Ratzeburger Allee 160, D-23538 Lübeck, Germany

**Abstract:** For omphaloceles, specially giant ones, different approaches of abdominal wall repair exist. Serious complications can follow staged repair as well as primary closure. We performed a delayed direct closure under stable conditions. Eight patients (gestational age: 26-37 weeks, birth weight: 710-3240 g) with omphalo-celes of different sizes were treated prospectively. The hernial sac was protected by a sterile dressing and gentle upward traction was performed without sedation or anaesthesia. This allowed spontaneous reduction of herniated viscera and liver, before the defect was closed. Seven defects were closed on day 2-14. No serious complications were observed. At follow-up 15-34 months cosmetic results were excellent without ventral hernia. One re-laparotomy for ileus due to adhesions was necessary. The preterm infant with 730 g birth weight died of severe intracranial haemorrhage before the defect could be closed. Present treatment proved to be safe and reliable, even in two giant omphaloceles. Multiple operative procedures as well as prosthetic material were avoided. No infection or abdominal-compartment syndrome occurred. Cosmetic results were very good, no secondary ventral hernia or other long-term complications developed.

**Key words:** Omphalocele, delayed repair, conservative treatment, compartment-syndrome

### INTRODUCTION

In omphaloceles, today's survival rate is close to 100% due to progresses in neonatal intensive care, pediatric surgery and anaesthesia; further on, severe anomalies detected ante-natally by ultrasound will mostly terminate pregnancy in these cases. As a side-effect, expectations towards optimal outcome are rising. In a re-evaluation of our 52 cases of abdominal wall defects between 1970-2000 (Kaiser *et al.*, 2000) we observed long term complications such as ventral wall hernias (20%) resulting in revisions (16 %) or unsatisfying cosmetic results (15%).

Present data and the well known complications reported in literature led us to formulate new aims for patients with omphalocele: Stabilisation of the newborn, time to rule out associated anomalies, a less invasive therapy without secondary surgical procedures and optimal functional and cosmetic results.

### MATERIALS AND METHODS

A prospective observational study included 8 patients from the Department of Pediatric Surgery at Lübeck University with omphaloceles between 11/ 2003 and 5/2005. Two om-phaloceles fulfilled criteria of giant omphaloceles, the others were small to midsize omphaloceles (Table 1).

In the neonatal intensive care unit the infants were placed in the incubator in prone position. All defects were evaluated by the attending pediatric surgeon. The hernial sac was dressed with gauze soaked with Lavasept<sup>RT</sup> (containing Polyhexanid) under sterile conditions without analgesics or sedation. A sterile glove was used as a cover. Upward traction of the sac was established through the umbilical cord, which was fixed with additional sutures to the top of the incubator (Fig. 1).

This allowed gravity to reduce the abdominal contents. Dressings were changed every day without

Table 1: Data of our eight patients

Sex/birth weight additional diseases	Size of OC	Eventrated organs	Feeding after birth	Days till closure	Enteral feeding after closure of OC
Male, 3610 g None	4 cm	Intestine	Immediately	2 d	6 h
Male, 3600 g Wiedemann-Beckwith- Syndrome, difficult pulmonal adaptation, ASD II	5 cm	Intestine	Immediately	2 d	25 h (22h MV ventilation)
Male, 2375 g	4 cm	Intestine	Immediately	2 d	6 h
Female, 2350 g	7 cm	Intestine+Liver	Immediately	7 d	14 h (due to 12 h mechanical ventilation)
Female, 2650	8 cm	Liver	Immediately	16 d	38 h (due to 36 h mechanical ventilation)
Female, 3745 g Meckel- Diverticulum, stenosis of colon	3 cm	Intestine	Immediately	2 d	48 h (due to anastomosis and colostomy)
Female, 700 g Severe intracerebral bleeding	3 cm	Intestine+Liver	-	-	-
Male, 2790 g	5 cm	Intestine	-	3	4 h

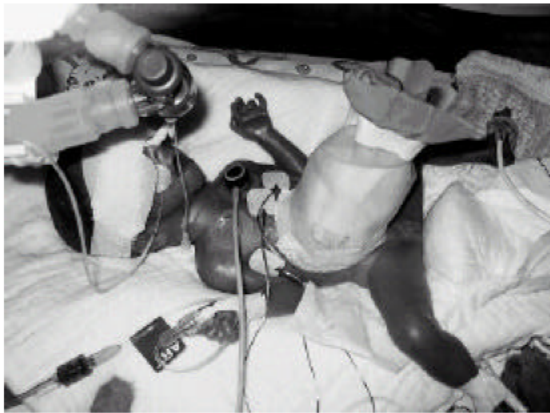


Fig. 1: Upward traction of the sac was established through the umbilical cord, which was fixed with additional sutures to the top of the incubator

sedation or anaesthesia. Oral feeding was begun soon after birth besides the very small baby. The decision for closure was made when after spontaneous reduction the eventrated organs could be reduced into the abdomen without forced tension and when this procedure was well tolerated by the conscious babies. Our preferred operative strategy was resection of the omphalocele sac and preparation of the rectus muscle for an almost physiologic closure of the abdominal wall. After discharge from the hospital children were followed as outpatients. Regular visits allowed recognizing the development of late complications such as gastroesophageal reflux, ventral hernia or unsightly scar formation.

### RESULTS

Four newborns were female, 4 male. Gestational age was between 26+2 and 37+3 weeks (median 36 weeks) with birth weight between 730 and 3240 g (median 2950 g). Associated anomalies included rotational anomalies of the

bowel and omphalomesenteric duct anomalies, stenosis of colon and 2 atrial septal defects. One patient suffered from Wiedemann-Beckwith-Syndrome (WBS).

Primary mechanical ventilation was necessary only in the premature infant with respiratory distress syndrome. Due to the unstable condition a surgical procedure was delayed despite spontaneous reduction of the herniated viscera; the baby died on the 14th day of life of extensive intracranial haemorrhage.

Closure of the omphalocele could be achieved on the 3rd to 14th day of life without increased tension. Duration of surgery was 60-120 min (median 105 min). Mechanical ventilation following abdominal closure was required for 0-36 h with a median of 6 h. The boy with WBS required ventilation of 22h due to muscular hypotonus and macroglossy, a small female baby with giant omphalocele had ventilation for 36 h. Feeding was started in four babies immediately after closure, in the giant omphaloceles after 14 h and 38 h, respectively. In the patient with WBS feeding was started due to mechanical ventilation after 25 h, in another patient a starving period of two days was necessary after resection of a Meckel's Diverticulum and creation of a colostomy due to colon stenosis. In all patients full oral feeding was achieved after 2 to 7 days.

No abdominal compartment syndrome, wound infection or other postoperative complications were observed. All babies could be discharged from hospital after 8 to 17 days after surgery.

One patient was readmitted 8 weeks later due to mechanical obstruction. He required a second operation because of a single intraabdominal adhesion. After a follow-up period of 7 to 26 months no child suffered from development of ventral hernia. All children developed well, tolerated their feeding excellently and thrived normally. Since no clinical symptoms suggestive of gastroesophageal reflux disease were reported, no further diagnostic procedures to rule out reflux were performed.

The cosmetic result rated by parents and the authors was good and very good in 6 patients and good in 1 case due to an unsuccessful reconstruction of an umbilicus.

## DISCUSSION

All treatment strategies in omphaloceles include certain disadvantages. Problems in conservative treatment are unrecognized further intestinal anomalies, incarceration of herniated viscera or sepsis. Insufficient development of the abdominal cavity made secondary closure sometimes difficult (Kaiser *et al.*, 2000; Smith *et al.*, 1981; Yazbeck, 1986). After primary closure the extent of visceroperitoneal disproportion with increased pressure could lead to abdominal compartment syndrome (Kawar *et al.*, 2003) and long-term complications as gastro-oesophageal reflux disease (Jolley *et al.*, 1999), ventral hernias or poor cosmetic appearance. Two-or-more-step-procedures such as creating a silo or using prosthetic material required multiple operations which prolonged hospital stay. Infections could endanger secondary closure and lead to sepsis. Comparing to initial non-operative management, creation of a silo chimney led to significantly more complications (Nuchtern *et al.*, 1995).

In our 5 patients with smaller omphalocele (diameter 3-5 cm) favorable results could be achieved. We saw no problems with infection or sepsis, the babies could adapt to life without sedation or anaesthesia, oral feeding could begin immediately. There were almost no additional costs for material. After elective closure-which meant saving resources-the mechanical ventilation was 0 to 4 h besides one patient with WBS. The others recovered fast and without problems. We saw no hernias or cosmetic problems.

The two giant omphaloceles were closed on day 7 and 14 in a single operation. Post-operative ventilation was 12 h and 36 h. In follow-up, no secondary procedure was necessary and scar formation was little without development of a ventral hernia. Other recently published treatments of closing giant omphaloceles with prosthetic material (Zama *et al.*, 2004) or creating a silo (Pacilli *et al.*, 2005; Yokomori *et al.*, 1992) required serial operations. We took advantage of maintaining an intact membrane without foreign material, avoiding the use of prosthetic material with increased risk of wound dehiscence, infection and sepsis (Yokomori *et al.*, 1992; Zama *et al.*, 2004). Late complications in these publications included ventral hernias and extensive scarring.

With External silo reduction or DECRO (Delayed External Compression Reduction of an Omphalocele) two

approaches comparable to ours, almost no complications were reported in three (Barlow *et al.*, 1987) and six patients (Brown and Wright, 1998). Time until reduction was three to five days and four to seven days, respectively. However, compression of the hernia carried the potential risk of pulmonary compromise. Impaired perfusion with consecutive damage of liver and intestine was observed in one of three cases during daily sequential sac ligation under sedation (Hong *et al.*, 1994). Despite earlier closure of the defect than in our two cases, enteral feeding was delayed and time until discharge from hospital was longer. We generally initiated enteral feeding soon after birth to avoid complications due to prolonged bowel rest. Enteral feeding 14 and 38 h, respectively after closure of the giant omphaloceles was tolerated. Full feeding was established 2 to 7 days postoperatively as compared to 18.8 days with DECRO (Brown and Wright, 1998). Time to discharge after closure was 30.5 days depending on birth weight (Brown and Wright, 1998) comparing to 12 and 17 days at our institution. External compression took 30 and 40 days till closure and was also judged by the authors to be effective, inexpensive and a low-risk method (DeLuca *et al.*, 1996).

Our approach was even feasible in a very small baby, comparable to a case-report (Hendrickson *et al.*, 2003). Unfortunately our baby died due to cerebral haemorrhage - without any stress through transport, anaesthesia or operation.

Active enlargement (Patkowski *et al.*, 2005) in 8 neonates with "large" omphaloceles led to reduction in 2-6 days; mechanical ventilation and paralyzing the babies during the whole procedure was necessary. This prolonged mechanical ventilation carried the risk of pneumonia and RDS, delayed enteral feeding could lead to infections from central venous lines. Lazaro da Silva's technique (Pereira *et al.*, 2004) or the translation of muscular layers (Wijnen *et al.*, 2005) are extensive methods which can leave huge scares and should be reserved for very difficult cases.

In this present small series of 6 patients there were no cosmetic problems or functional gastro-intestinal disorders as quoted in 37% and 51 % of patients, respectively on long-term follow-up (Kaiser *et al.*, 2000; Smith *et al.*, 1981). The only complication related to gastrointestinal function was adhesion ileus in one patient, which represents a possible complication of any abdominal surgical procedure.

## CONCLUSION

Delayed direct closure of omphalocele is feasible, allows to stabilize these neonates and to diagnose associated malformations. Further on, it avoids possible

complications of implanted foreign material and serial surgical procedures. With our approach early and late complications were minimal. No long-term mechanical ventilation or paralysis was necessary. The possibility of very early enteral feeding reduced complications of parenteral nutrition and supported early postoperative discharge from the hospital. We therefore, recommend this treatment as an alternative for small and mid-size omphaloceles, but also judge it as a promising approach for the repair of giant omphaloceles.

#### REFERENCES

- Barlow, B., A. Cooper, R. Gandhi and M. Niemirska, 1987. External silo reduction of the unruptured giant omphalocele. *J. Pediatr. Surg.*, 22: 75-76.
- Brown, M.F. and L. Wright, 1998. Delayed External Compression Reduction of an Omphalocele (DECRO): An alternative method of treatment for moderate and large omphaloceles. *J. Pediatr. Surg.*, 33: 1113-1115, 1115-1116.
- DeLuca, F.G., B.F. Gilchrist, E. Paquette, C.W. Wesselhoeft and F.I. Luks, 1996. External compression as initial management of giant omphaloceles. *J. Pediatr. Surg.*, 31: 965-967.
- Hendrickson, R.J., D.A. Partrick and J.S. Janik, 2003. Management of giant omphalocele in a premature low-birth-weight neonate utilizing a bedside sequential clamping technique without prosthesis. *J. Pediatr. Surg.*, 38: E14-16.
- Hong, A.R., D.L. Sigalet, F.M. Guttman, J.M. Laberge and D.P. Croitoru, 1994. Sequential sac ligation for giant omphalocele. *J. Pediatr. Surg.*, 29: 413-415.
- Jolley, S.G., M.L. Lorenz, M. Hendrickson and J.P. Kurlinski, 1999. Esophageal pH monitoring abnormalities and gastroesophageal reflux disease in infants with intestinal malrotation. *Arch. Surg.*, 134: 747-752; 752-743.
- Kaiser, M.M., F. Kahl, C. Von Schwabe and H. Halsband, 2000. [Omphalocele and gastroschisis. Outcome--complications--follow-up--quality of life]. *Chirurg*, 71: 1256-1262.
- Kawar, B. and L. Siplovich, 2003. Abdominal compartment syndrome in children: the dilemma of treatment. *Eur. J. Pediatr. Surg.*, 13: 330-333.
- Nuchtern, J.G., R. Baxter and E.I. Hatch, 1995. Nonoperative initial management versus silon chimney for treatment of giant omphalocele. *J. Pediatr. Surg.*, 30: 771-776.
- Pacilli, M., L. Spitz, E.M. Kiely, J. Curry and A. Pierro, 2005. Staged repair of giant omphalocele in the neonatal period. *J. Pediatr. Surg.*, 40: 785-788.
- Patkowski, D., J. Czernik and S.M. Baglaj, 2005. Active enlargement of the abdominal cavity-a new method for earlier closure of giant omphalocele and gastroschisis. *Eur. J. Pediatr. Surg.*, 15: 22-25.
- Pereira, R.M., E.S. Tatsuo, A.C. Simoese Silva, J.T. Guimaraes, R.M. Paixao and J.C. Lanna *et al.*, 2004. New method of surgical delayed closure of giant omphaloceles: Lazaro da Silva's technique. *J. Pediatr. Surg.*, 39: 1111-1115.
- Smith, S. and E.S. Golladay, 1981. Modern management of omphalocele and gastroschisis. *J. Ark. Med. Soc.*, 77: 379-385.
- Wijnen, R.M., F. Van Eijck, F.H. Van der Staak and R.P. Bleichrodt, 2005. Secondary closure of a giant omphalocele by translation of the muscular layers: A new method. *Pediatr. Surg. Int.*, 21: 373-376.
- Yazbeck, S., 1986. The giant omphalocele: A new approach for a rapid and complete closure. *J. Pediatr. Surg.*, 21: 715-717.
- Yokomori, K., M. Ohkura, Y. Kitano, T. Hori and T. Nakajo, 1992. Advantages and pitfalls of amnion inversion repair for the treatment of large unruptured omphalocele: Results of 22 cases. *J. Pediatr. Surg.*, 27: 882-884.
- Zama, M., S. Gallo, L. Santecchia, E. Bertozzi, A. Zaccara, A. Trucchi, A. Nahom, P. Bagolan and C. De Stefano, 2004. Early reconstruction of the abdominal wall in giant omphalocele. *Br. J. Plast. Surg.*, 57: 749-753.