

Asian Journal of
Biological
Sciences

Hepatoprotective Activity of *Bridelia retusa* against Paracetamol-induced Liver Damage in Swiss Albino Mice

¹V.B. Ghawate, ²R.S. Bhambar, ³S.M. Bairagi and ⁴V.S. Jadhav

¹Department of Pharmaceutical Sciences, Bhagwant University, Ajmer, Rajasthan, India

²MGV's College of Pharmacy, Pachwati, Nasik, Maharashtra, India

³Department of Pharmacology, MES College of Pharmacy, Sonai, Ahmednagar, Maharashtra, India

⁴Department of Pharmacognosy, MES College of Pharmacy, Sonai, Ahmednagar, Maharashtra, India

Corresponding Author: V.B. Ghawate, Department of Pharmaceutical Sciences, Bhagwant University, Ajmer, Rajasthan, India

ABSTRACT

The present study is aimed at evaluating the hepatoprotective effect of *Bridelia retusa* bark extracts by paracetamol-induced liver damage in swiss albino mice. The degree of protection was measured by using biochemical parameters such as Serum Glutamate Oxalate Transaminase (SGOT), Serum Glutamate Pyruvate Transaminase (SGPT), Alkaline Phosphatase (ALP), bilirubin and total protein. Further the effect of extract was assayed by using Lipid Peroxidation (LPO), Glutathione (GSH), Superoxide Dismutase (SOD) and Catalases (CAT) were estimated. The Phytochemical investigation of butanol extract showed presence gallic acid and catechin. Treatment with *Bridelia retusa* bark extract showed significant reduction in values of SGOT, SGPT, ALP and total bilirubin almost comparable to the Silymarin. The hepatoprotection confirmed by histopathological examination of the liver tissue from the result it can be concluded that *Bridelia retusa* possesses hepatoprotective effect against paracetamol-induced liver damage in mice may be due to presence of gallic acid and catechin.

Key words: *Bridelia retusa*, hepatoprotection, HPLC, paracetamol, silymarin

INTRODUCTION

Recently the herbals play important role in treating various disease. Modern medicine does not have suitable cure for the liver disorder, asthma and cardiovascular disorders.

Bridelia retusa (Euphorbiaceae). A small or moderate sized tree, spinus when young and has gray bark. Leaves are used in Ayurveda formulation for the treatment of urinary tract infections and bark is given orally to women to develop sterility and as contraceptive (Jain *et al.*, 2004). The root and the bark are valuable astringent. Stem bark and roots were used for rheumatism and as astringent agents (Jayasinghe *et al.*, 2003). The paste of leaves of *Bridelia retusa*, *Curculigo orchoides* and oil of castor, coconut and gingelly applied externally to cure wounds. (Ayyanar and Ignacimuthu, 2005). The *Bridelia retusa* combination with other plants used traditionally to cure hepatitis (Trivedi, 2006).

The *Bridelia retusa* bark also used to cure dysentery (Kshirsagar and Singh, 2001). Different active component isolated from the *Bridelia retusa* bark like new bisabolane sesquiterpenes, 4-[(E)-6-methyl-4-oxohept-2-en-2-yl] benzoic acid (21), 4-[(R)-6-methyl-4-oxohept-5-en-2-yl] benzoic acid (22), 4-[(R)-6-methyl-4-oxoheptan-2-yl] benzoic acid (23) and

(-)-isochaminic acid (24), together with the known 4-[(R)-6-methyl-4-oxoheptan-2-yl] benzoic acid (ar-todomatuic acid), 5-allyl-1, 2, 3-trimethoxy-benzene (elemicin) (25), (+)-sesamin (26) and 4-isopropylbenzoic acid (cubic acid). All these compounds showed marked fungicidal activity against *Cladosporium cladosporensis* (a plant-pathogenic fungus), except for elemicin (Jayasinghe *et al.*, 2003). The presence of isoflavone was isolated from *Bridelia retusa* leaves extract and its structure elucidated by spectroscopical study. These isoflavone showed strong antimicrobial activity against Gram-positive and Gram negative bacteria (Adhav *et al.*, 2002) Liver is vital organ play important role in metabolism and excretion. Mortality rate is upto 20,000 per year due to liver disorders (Sharma and Sharma, 2010).

Hepatocellular carcinoma is one of the most common tumors in the world. Paracetamol causes liver toxicity by reaction metabolite N-acetyl-p-benzo Quinoneimine (NAPQI). This causes oxidative stress and glutathione depletion (Shah and Deval, 2011). It is a well known analgesic and antipyretic agent which produces hepatic necrosis at higher doses. Paracetamol widely use in India as an analgesic and antipyretic. Therefore, in the present study hepatoprotective effect of extracts has been evaluated against paracetamol induced liver damage.

MATERIAL AND METHOD

Drugs and chemicals: Paracetamol was procured from Merck (India) Ltd. Mumbai. Silymarin was obtained Cadila pharma India. Standard kit of Serum Glutamate Oxaloacetate Transaminase (SGOT), Alkaline Phosphate (ALP), Serum Glutamate Pyruvate Transaminase (SGPT), Total bilirubin was obtained from span diagnostics. All other reagents were used for experiment were of high analytical grade.

Plant and material: The *Bridelia retusa* were collected from Western Ghat of Maharashtra and authenticated by J. Jayanthi scientist, Botanical Survey of India, Pune and herbarium (voucher no. BRIRVIGI) deposited in BSI pune.

Preparation of extract: The fresh bark was cleaned, shed dried and then powdered. Firstly the dried coarse powder of bark defatted with petroleum ether later it was subjected to successive extraction in a soxhlet apparatus using Chloroform, Butanol and 70% Acetone. The extracts were subjected to preliminary phytochemical screening. The suspension of extract and paracetamol were prepared using tween 80 (0.5%) and subjected for Hepatoprotective activity against paracetamol-induced liver damage.

Phytochemical evaluation of extract: The successive extraction process showed presence of different metabolites including tannin, flavonoids, phenolics, saponins and triterpenoids were confirmed using conventional phytochemical tests.

The presence of gallic acid and catechin, in butanol bark extract of *Bridelia retusa* was confirmed by HPLC using catechin and gallic acid (Sigma-Aldrich chemie, Steinheim, Germany) as standard marker. A Younglin (S.K) Gradient system UV detector (UV1000 Spectra System), Luna C18 reverse-phase column (250×4.6 mm i.d. particle size 5 µm) was used. The acetonitrile: water (80:20) used for mobile phase with flow rate 0.3 mL min⁻¹ at 25°C and the detection of wavelength was set at 280 nm. The data were analyzed using Autochro-3000 software.

Experimental animals: Swiss albino mice weighing 25-30 g were housed in standard laboratory condition 12 h light and dark cycle with standard food and water ad libitum.

Acute oral toxicity: The protocol for experimental study was approved by IAEC and as per the OECD revised guideline no 423 and CPCSEA the oral toxicity study was carried out (OECD, 2005).

Evaluation of hepatoprotective activity: Nine groups of mice containing five animals in each group were prepared. Group I, which is served as normal control, received 5% CMC p.o. for 7 days. Group II, received 5% CMC p.o. for 7 days. Group III, received Silymarin suspended in 5% CMC (100 mg kg⁻¹, p.o.) for 7 days. Group IV received *Bridelia retusa* bark butanol extract (BRBB) 100 mg kg⁻¹ for 7 days. Group V received butanol extract (BRBB) 200 mg kg⁻¹ for 7 days. Group VI received *Bridelia retusa* bark 70% acetone extract (BRBA) 100 mg kg⁻¹ for 7 days. Group VII received 70% acetone extract (BRBA) 200 mg kg⁻¹ for 7 days. Group VIII received *Bridelia retusa* bark chloroform extract (BRBC) 100 mg kg⁻¹ for 7 days and Group IX received chloroform extract (BRBC) 200 mg kg⁻¹ for 7 days. After 7 days single dose of Paracetamol 250 mg kg⁻¹ p.o. administered to all group except normal control and then animals were kept for fasting for 18 h (Nayak *et al.*, 2011; Qadir *et al.*, 2014).

Under the light anesthetic ether the animals were sacrificed and the blood sample was collected from retro orbital plexus for biochemical investigation. i.e., SGOT, SGPT, ALP and total Bilirubin estimation. For 30 min blood was allowed to coagulate and serum was separated by centrifugation at 2500 rpm for 10 min.

All the animals were humanely sacrificed, liver was aseptically removed and processed for histological investigation and liver tissue (100 mg) was added to 500 µL of 500 mM Tris buffer (pH 7.4) and was homogenized. The homogenate was entrifuged at 10,000 rpm for 15 min at 4°C and theupper layer was collected and stored at -80°C for SOD, GSH, LPO and catalase assays.

Histopathological studies: One animal from each group was utilized for histopathological study. The livers were fixed in 10% formalin for 24 h. The formalin fixed liver stained with haematoxylin-eosin for microscopic observation.

Statistical analysis: Results were expressed as Mean±SD. Statistical analysis of the data was done using one-way analysis of variance (ANOVA) followed by Dunnett's test and significance determined by using p<0.05.

RESULT

The preliminary phytochemical screening showed the presence of different secondary metabolites like tannins, flavonoids, phenolics, saponins and triterpenoids. Further HPLC analysis of Butanol extract confirmed the presence of important constituent, gallic acid (R_t = 2.4 min), catechin (R_t = 5.1 min) (Fig. 1).

Administration of paracetamol (250 mg kg⁻¹, p.o.) induced a marked increase in the level of serum hepatic biochemical markers, Serum Glutamate Oxaloacetate Transaminase (SGOT), Alkaline Phosphate (ALP), Serum Glutamate Pyruvate Transaminase (SGPT), Total Bilirubin as compared to normal controls, indicating liver damage. Pretreatment of mice with BRBB extract (100 and 200 mg kg⁻¹) before paracetamol administration causes significant change in values of SGOT, SGPT, ALP and total Bilirubin in a dose dependent manner as compared to BRBA and BRBC extract. However butanol extract showed (100 and 200 mg kg⁻¹) showed the highest Hepatoprotective activity (Table 1).

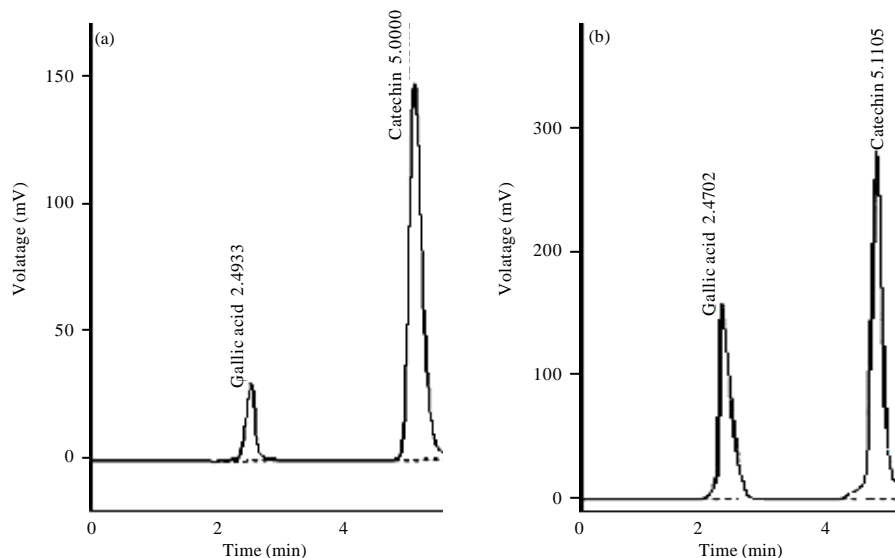


Fig. 1(a-b): HPLC chromatogram of (a) Authentic standard gallic acid and catechin and (b) Gallic acid and catechin identified in BRBB extract of *Bridelia retusa*

Table 1: Effect of *Bridelia retusa* extract on mice serum parameters after paracetamol administration

<i>Bridelia retusa</i> extract	ALP	Bilirubin	SGOT	SGPT
Vehicle	103.9±2.52**	0.59±0.02**	56.58±1.63**	63.40±1.24**
Control	201.1±2.54	1.81±0.04	97.34±1.07	112.40±2.13
STD	122.5±1.77**	0.62±0.02**	63.32±0.77**	67.08±1.17**
BRBB100	147.8±1.48**	0.78±0.02**	79.70±0.72**	87.56±1.09**
BRBB200	137.6±1.57**	0.68±0.02**	71.12±0.83**	75.94±1.12**
BRBA100	165.9±2.00**	0.81±0.01**	87.64±1.19**	96.84±1.70**
BRBA200	158.3±2.10**	0.77±0.01**	82.58±1.84**	90.36±1.76**
BRBC100	196.4±2.47	1.76±0.02	96.72±1.09	108.40±2.27
BRBC200	192.9±2.10	1.72±0.01	92.41±1.72	106.10±1.89

Data is presented as Mean±SEM (n = 5), **p<0.01

Bark extract of *Bridelia retusa* showed the levels of enzymatic antioxidant namely Superoxide Dismutase (SOD), Catalase (CAT), Lipid Peroxidase (LPO) and Reduced Glutathione (GSH) in the liver of control and experimental animals (Table 2). It shows that paracetamol treated mice significantly decrease in activities of hepatic enzymatic antioxidants. Treatment with BRBB extract significantly increased the activities of enzymatic antioxidants in liver when compared with paracetamol treated mice.

The hepatoprotective effect of extract was confirmed by histological examination of the liver tissue of control and treated animals. Control group showed normal parenchymal architecture no significant necrosis observed. In paracetamol treated mice liver section showed necrosis, cloudy swelling, fatty degeneration, heavy haemorrhage and irregular appearance due to cell death were seen. The above changes were reduced in the liver of mice treated *Bridelia retusa* bark extract (Fig. 2).

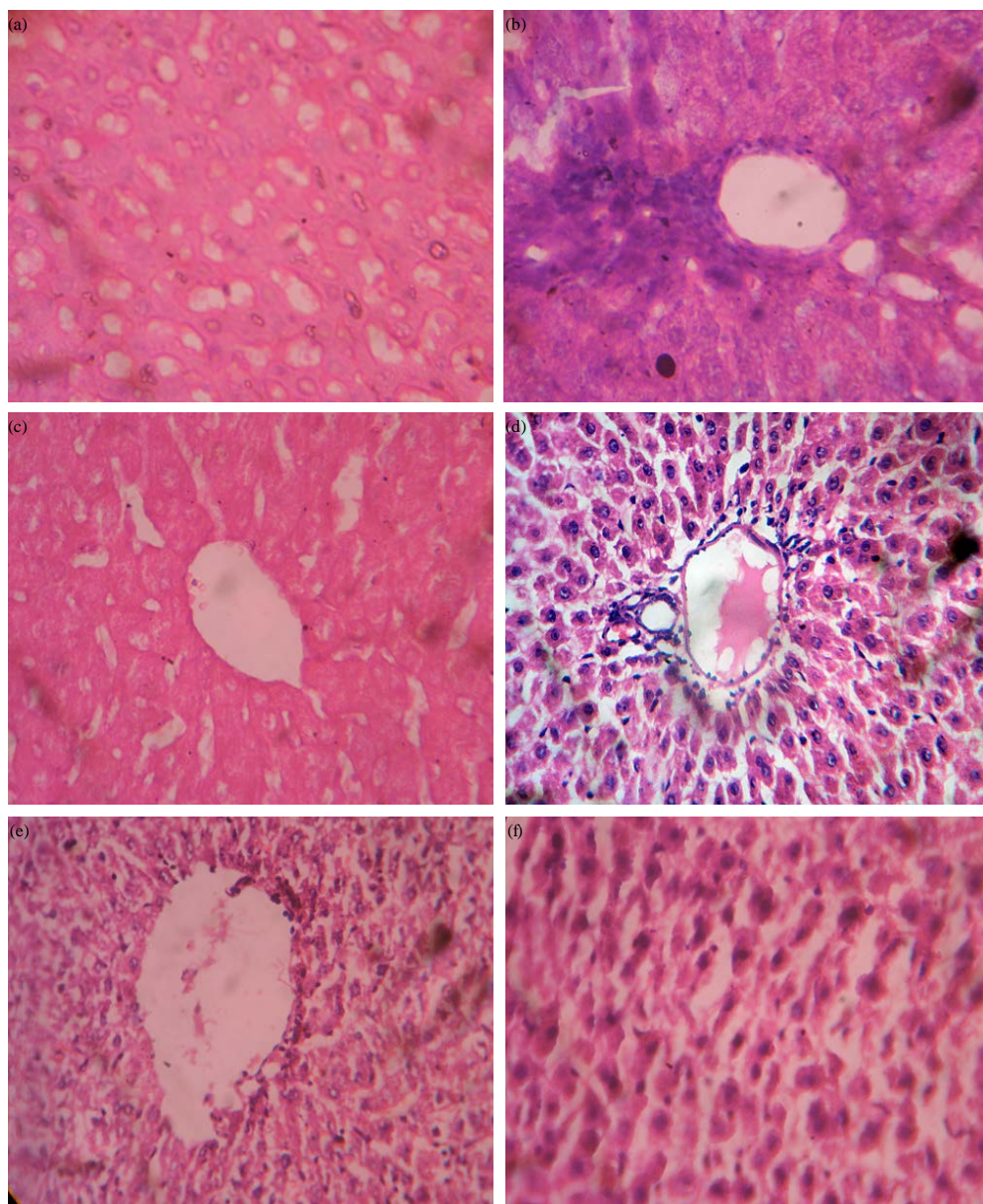


Fig. 2(a-f): Representative photographs from the liver showing the protective effect of *Bridelia retusa* on paracetamol-induced hepatic injury in mice, (a) Control rat liver. Normal hepatic parenchyma., (b) Paracetamol-treated liver showing necrosis, cloudy swelling, fatty degeneration, heavy haemorrhage and irregular appearance due to cell death were seen, (c) Control group showed normal parenchymal architecture no significant necrosis observed, (d) BRBA treated liver showing mild inflammation, mild degeneration, mild necrosis and mild fatty degeneration, (e) BRBB treated liver showing moderated inflammation, mild degeneration, mild necrosis and mild fatty degeneration and (f) BRBC treated liver showing mild inflammation, mild degeneration, mild necrosis and mild fatty degeneration

Table 2: Influence of oral administration of *Bridelia retusa* extract to paracetamol treated animals on antioxidant enzymes activities

<i>Bridelia retusa</i> extract	SOD	GSH	LPO	CAT
Vehicle	11.52±0.25**	4.48±0.10**	1.54±0.03**	13.85±0.25**
Control	3.01±0.05	0.30±0.01	6.26±0.25	3.96±0.07
STD	10.70±0.25**	4.25±0.11**	1.89±0.06**	13.12±0.19**
BRBB100	8.34±0.22**	3.43±0.14**	2.88±0.10**	10.43±0.26**
BRBB200	9.15±0.12**	3.81±0.05**	2.22±0.08**	12.16±0.15**
BRBA100	6.80±0.19**	1.99±0.05**	3.46±0.13**	9.41±0.29**
BRBA200	7.70±0.21**	2.52±0.11**	3.10±0.11**	10.12±0.25**
BRBC100	3.38±0.05	0.59±0.11	5.91±0.12	4.22±0.154
BRBC200	3.69±0.17	0.62±0.1	5.96±0.08	3.62±0.24

Data is presented as Mean±SEM (n = 5), **p<0.01

DISCUSSION

Paracetamol causes potential complication of hepatotoxicity. It is widely prescribed in general medicine and an assessment of its relative toxicity is important. Common cause of paracetamol toxicity due to its metabolism in liver (Gu *et al.*, 2005).

Paracetamol at therapeutic level metabolized via glucuronide and sulfate conjugation reactions result in water soluble metabolites that are excreted via the kidney. Metabolism of paracetamol takes place by microsomal P-450 enzyme and a reactive intermediate is formed namely N-acetyl-P-benzoquinone imine (NAPQI). Glutathione reduced this metabolite (Bessems and Vermeulen, 2001).

NAPQI induces peroxidation of polyunsaturated fatty acid leading to liver damage and elevated level of serum marker enzymes such as SGPT, SGOT, ALP and total bilirubin from hepatocytes in the serum (Srinivasan *et al.*, 2007).

When large dose of paracetamol are ingested large quantity of metabolite formed and more severe Glutathione depletion occurs with large amount of reactive metabolite unbound. These intermediate then covalently bind with cellular protein. This process disrupts homeostasis and initiates apoptosis leading to tissue necrosis and organ dysfunction. Glutathione depletion permit lipid peroxidation suggested to closely relating to paracetamol liver damage. Therefore antioxidant supplement protect against paracetamol toxicity.

The reduction in level of SGPT and SGOT by BRBB extract showed stabilization of plasma membrane and healing of hepatic tissue damage caused by paracetamol as compared to other extracts. This result showed that serum level of transaminases return to normal with the healing of hepatic parenchyma and regeneration of hepatocytes (Thabrew *et al.*, 1987).

Pathological alteration in biliary flow is reflects by the ALP which is the prototype of these enzymes (Ploa and Hewitt, 1989).

The BRBB extract induced the suppression of the increased ALP activity with subsequent depletion of raised bilirubin states that the extracts have potential to stabilize biliary dysfunction in paracetamol treated liver. The BRBB extract showed hepatoprotective activity by reducing paracetamol-induced elevated level of SGPT, SGOT, ALP and total bilirubin. Thus administration of butanol extract revealed potent hepatoprotective activity against toxic effect of paracetamol which is also supported by histological studies. The phytochemistry of extract has been elucidated, the presence of gallic acid and catechin which has definite hepatoprotective role (Ryle *et al.*, 1983).

CONCLUSION

It may be concluded that the result of this study demonstrated that *Bridelia retusa* extract protect against paracetamol-induced liver damage in mice. These result shows that the protective effect of extract may be due to presence of gallic acid, catechin and their ability to decrease the metabolic activation of paracetamol. The present study justifies the traditional use of *Bridelia retusa* in treatment of liver disease and also point out that *Bridelia retusa* vindicate further detailed investigation as a promising hepatoprotective agent. Further studies are required to obtain a better understanding of the mechanism of its action.

REFERENCES

- Adhav, M., C.M. Solanki, B. Patel and A. Gharia, 2002. Evaluation of isoflavanone as an antimicrobial agent from leaves of *Bridelia retusa* (L) spreng, Veg. Orient. J. Chem., 18: 479-486.
- Ayyanar, M. and S. Ignacimuthu, 2005. Traditional knowledge of Kani tribals in Kouthalai of Tirunelveli hills, Tamil Nadu, India. J. Ethnopharmacol., 102: 246-255.
- Bessemers, J.G.M. and N.P.E. Vermeulen, 2001. Paracetamol (acetaminophen)-induced toxicity: Molecular and biochemical mechanisms, analogues and protective approaches. Crit. Rev. Toxicol., 31: 55-138.
- Gu, J., H. Cui, M. Behr, L. Zhang and Q.Y. Zhang *et al.*, 2005. *In vivo* mechanisms of tissue-selective drug toxicity: Effects of liver-specific knockout of the NADPH-cytochrome P450 reductase gene on acetaminophen toxicity in kidney, lung and nasal mucosa. Mol. Pharmacol., 67: 623-630.
- Jain, A., S.S. Katewa, B.L. Chaudhary and P. Galav, 2004. Folk herbal medicines used in birth control and sexual diseases by tribals of southern Rajasthan, India. J. Ethnopharmacol., 90: 171-177.
- Jayasinghe, L., B.M. Kumarihamy, K.H.R. Jayarathna, N.W.M. Udishani, B.M. Bandara, N. Hara and Y. Fujimoto, 2003. Antifungal constituents of the stem bark of *Bridelia retusa*. Phytochemistry, 62: 637-641.
- Kshirsagar, R.D. and N.P. Singh, 2001. Some less known ethnomedicinal uses from Mysore and Coorg districts, Karnataka state, India. J. Ethnopharmacol., 75: 231-238.
- Nayak, S.S., R. Jain and A.K. Sahoo, 2011. Hepatoprotective activity of *Glycosmis pentaphylla* against paracetamol-induced hepatotoxicity in Swiss albino mice. Pharm. Biol., 49: 111-117.
- OECD, 2005. Guideline on acute oral toxicity. Organization for Economic Co-operation and Development (OECD), Paris, France, October 2005.
- Ploa, G.L. and W.R. Hewitt, 1989. Detection and Evaluation of Chemically Induced Liver Injury. In: Principals and Methods of Toxicology, Wallace Hyes, A. (Ed.). 2nd Edn., Raven Press, New York, pp: 399-628.
- Qadir, M.I., M.S. Al Murad, M. Ali, M. Saleem and A.A. Farooqi, 2014. Hepatoprotective effect of leaves of aqueous ethanol extract of *Cestrum nocturnum* against paracetamol-induced hepatotoxicity. Bangladesh J. Pharmacol., 9: 167-170.
- Ryle, P.R., J. Chakraborty and A.D. Thomson, 1983. Biochemical mode of action of a hepatoprotective drug: Observations on (+)-catechin. Pharmacol. Biochem. Behav., 18: 473-478.
- Shah, V.N. and K. Deval, 2011. Hepatoprotective activity of leaves of *Parkinsonia aculeate* linn against paracetamol induced hepatotoxicity in rats. Int. J. Pharm., 1: 59-66.

- Sharma, B. and U.K. Sharma, 2010. Hepatoprotective activity of some indigenous plants. *Int. J. Pharm. Tech. Res.*, 2: 568-572.
- Srinivasan, R., M.J.N. Chandrasekar, M.J. Nanjan and B. Suresh, 2007. Antioxidant activity of *Caesalpinia digyna* root. *J. Ethnopharmacol.*, 113: 284-291.
- Thabrew, M., P.D. Joice and W. Rajatissa, 1987. A comparative study of the efficacy of *Pavetta indica* and *Osbeckia octandra* in the treatment of liver dysfunction. *Planta Medica*, 53: 239-241.
- Trivedi, P.C., 2006. Herbal Medicine Traditional Practice. Jaipur Press, India, ISBN 13: 9788179101520, pp: 40.