ISSN 1996-3351

Asian Journal of Biological Sciences

http://knowledgiascientific.com

Knowledgia SCIENTIFIC
A Place to Publish Outstanding Research

OPEN ACCESS Asian Journal of Biological Sciences

ISSN 1996-3351
DOI: 10.3923/ajbs.2020.201.209

Research Article
Ethanolic Leaf Extract of *Ocimum gratissimum* Abrogates Methotrexate-induced Liver Injury in Albino Rats

[1]Elias Adikwu, [2]Bonsome Bokolo and [3]Othuke Bensandy Odeghe

[1]Department of Pharmacology and Toxicology, Faculty of Pharmacy, Niger Delta University, Amassama, Nigeria
[2]Department of Pharmacology, Faculty of Basic Medical Sciences, Niger Delta University, Amassama, Nigeria
[3]Department of Biochemistry, Faculty of Science, Madonna University, Okija, Nigeria

Abstract

Background and Objective: Limited treatment options made hepatotoxic effect of methotrexate (MTX) a serious health challenge. In folklore, *Ocimum gratissimum* is used for the treatment of liver disease. The current study assessed the hepatoprotective effect of the ethanolic leaf extract of *Ocimum gratissimum* (EEOG) against MTX-intoxicated albino rats. **Materials and Methods:** Forty eight healthy adult albino rats were randomized into 8 groups of 6 rats per group. Rats were pretreated orally with 50, 100 and 200 mg kg^{-1} of EEOG daily for 5 days and 20 mg kg^{-1} of MTX intraperitoneal on the 5th day. On the 6th day, rats were weighed, sacrificed and blood was collected. Serum was extracted and evaluated for liver function indices. Liver was excised and assessed for biochemical parameters and pathology. **Results:** The MTX-treated rats showed significant ($p<0.001$) alterations in superoxide dismutase, glutathione, catalase, malondialdehyde, glutathione peroxidase, aminotransferase, alanine aminotransferase, alkaline phosphatase, total bilirubin, conjugated bilirubin, lactate dehydrogenase and glutamyl transferase levels when compared to control. The liver of MTX-treated rat showed hepatocyte necrosis. However, the above alterations were mitigated significantly ($p<0.001$) and in a dose dependent manner in EEOG pretreated rats. **Conclusion:** Methotrexate-induced hepatotoxicity in albino rats was abrogated by the ethanolic leaf extract of *Ocimum gratissimum*.

Key words: Hepatotoxicity, methotrexate, *Ocimum gratissimum*, prevention, rat

Citation: Elias Adikwu, Bonsome Bokolo and Othuke Bensandy Odeghe, 2020. Ethanolic leaf extract of *Ocimum gratissimum* abrogates methotrexate-induced liver injury in albino rats. Asian J. Biol. Sci., 13: 201-209.

Corresponding Author: Elias Adikwu, Department of Pharmacology and Toxicology, Faculty of Pharmacy, Niger Delta University, Amassama, Nigeria
Tel: 07068568868

Competing Interest: The authors have declared that no competing interest exists.

Data Availability: All relevant data are within the paper and its supporting information files.

INTRODUCTION

The liver is an indispensable organ that plays streams of vital functions in the maintenance and regulation of homeostasis in humans. It is involved in almost all the biochemical pathways associated with nutrient supply, growth, energy provision, defense and drug metabolism[1]. The liver plays a very important part in the pharmacokinetics of many chemotherapeutic agents; especially their activation, degradation and excretion thereby predisposing it to injury. Chemotherapeutic agent-induced liver injury or dysfunction can manifest as abnormal serum liver clinical chemistry or alteration in liver histology. Imaging perspective in cancer chemotherapy associated hepatotoxicity revealed sinusoidal obstructive syndrome, fatty liver, acute hepatitis, hepatic necrosis and portal vein thrombosis[2].

Methotrexate (MTX) is an essential anti-cancer drug which clinical use has reduced mortality associated with a wide range of diseases including systemic lupus erythematosus, rheumatoid arthritis and psoriasis[3]. The therapeutic use of MTX is usually limited by severe hepatotoxicity which has serious and significant safety concern. MTX can induce a wide range of hepatic injuries, including liver necrosis, cirrhosis, atrophy, fatty liver and periportal fibrosis[4]. The underlying mechanism by which MTX causes hepatotoxicity has not been fully identified, however, several distinct mechanisms have been proposed. These mechanisms include deregulation of cellular antioxidant defense via oxidative stress and direct liver damage[5]. Also, liver mitochondria damage via depletion of mitochondria antioxidant defense has been reported[6]. Furthermore, MTX can inhibit dihydrofolate reductase resulting in the depletion of reduced folate. The net result is the effective inhibition of DNA and RNA synthesis which portend serious danger to rapidly dividing cells including hepatocytes[7]. MTX is usually excreted in the urine unchanged, however, a small proportion is hydroxylated or metabolised to polyglutamate derivative; which is retained by the hepatocytes as MTX polyglutamates for a long period. This can result to decrease hepatocellular folic acid level which can lead to hepatocyte necrosis[8].

The use of medicinal plant for the treatment of ailments is a therapeutic practice that has been in existence before the development of orthodox medicine. Plants are good sources of remedies for different diseases in most developing countries[9]. *Ocimum gratissimum* (OG) is an herbaceous plant which belongs to the Labiatae family. It is indigenous to tropical areas especially India and West Africa. In Nigeria, it is found in Savannah and coastal areas[10]. Traditionally, OG is widely used in many countries as condiment and for culinary purpose because of its aromatic flavor. In addition to the aforementioned uses, in folklore, the benefits of different parts of OG including the leaves, stem and root have been fully harnessed for the treatment of different ailments in many part of the world[10]. A number of studies have subjected different components of OG to phytochemical analyses and discovered essential constituents which include tannins, flavonoids, terpenoids, alkaloids, saponins, steroids and glycosides[11]. Isolates from different parts of OG have shown lots of *in vitro* and *in vivo* pharmacological activities which could be harnessed for therapeutic applications. Furthermore, some animal studies suggested that extract from OG can be used to prevent or treat hepatopathies[12]. Due to the paucity of drugs for the treatment of liver toxicity associated with MTX[13] the use of OG may be beneficial in the treatment of MTX associated hepatotoxicity. Therefore the current study was designed to evaluate the hepatoprotective effect of the ethanolic leaf extract of OG (EEOG) against methotrexate-intoxicated rats.

MATERIALS AND METHODS

Drug and extract: Methotrexate 20 mg kg^{-1} (Zuvius Life sciences, India)[14] and 50, 100 and 200 mg kg^{-1} of ethanolic leaf extract of *Ocimum gratissimum* dissolved in corn oil[15] were used for this study. All other chemicals used for this study are of analytical grade.

Preparation of *Ocimum gratissimum* extract: The fresh leaves of *Ocimum gratissimum* (OG) were collected in April, 2018 in Akwa Ibom State and were authenticated by Dr.(Mrs) Eshieth of the Department of Botany, University of Uyo, Akwa Ibom State. The leaves of OG were washed and air-dried at room temperature. Thereafter, the dried leaves were powdered and 250 g of the powder was macerated in 1500 mL of ethanol for 48 h and then filtered with Whatman No. 1 filter paper. Using a rotary evaporator, the filtrate was concentrated at 40°C and the concentrated extract was further evaporated to dryness using hot oven at 40°C. The weight of the dried extract was gotten using electronic weighing balance.

Phytochemical evaluation of ethanolic leave extract of *Ocimum gratissimum*: Phytochemical screening for terpenoids, alkaloids carbohydrate, tannins, saponins protein, glycosides, steroids and flavonoids were performed using established procedures[16,17].

Experimental animals and drug administration: Forty eight adult albino rats of average weight 200-230 g were used for this study. Standard rat chow and water were provided

ad libitum. The rats were housed in cages of 6 per cage and maintained under standard laboratory condition (12 h light, temperature 25±1°C). Rats were allowed to acclimatize to laboratory condition for one week prior to the commencement of the study in the animal house of the Department of Pharmacology and Toxicology, Madonna University, Elele, Nigeria. This study was performed over the period of 2 weeks. This study was approved by the Ethics Committee of Department of Pharmacology and Toxicology, Faculty of Pharmacy, Madonna University, Elele, Nigeria, with ethical approval No. 2018/2256. The albino rats were randomized into 8 groups A-H of 6 rats each. Rats in groups A and B were administered with water and corn oil as placebo and solvent control, respectively for 5 days. Rats in groups B-D were administered orally with EEOG 50, EEOG 100 and EEOG 200 mg/kg/day for 5 days, respectively. Rats in group E were administered with 20 mg kg^{-1} of MTX intraperitoneally (ip) on the 5th day. Rats in groups F-H were orally pretreated with EEOG 50, EEOG 100 and EEOG 200 mg/kg/day for 5 days, respectively and were administered with 20 mg kg^{-1} of MTX ip on the 5th day.

Sacrifice of animal, biochemical and oxidative stress marker analyses: On the 6th day, rats were weighed and anesthetized using inhalational diethyl ether. Blood was collected from the heart and serum was extracted. Liver was excised, rinsed in ice-cold saline and homogenized in 0.1 M Tris-HCl buffer, pH 7.4 at 4°C. Liver homogenate was centrifuged at 1500 rmp for 20 min and the supernatant was used for biochemical and oxidative stress marker assay. Serum and liver samples were analyzed for aspartate aminotransferase (ALT), alanine aminotransferase (AST), alkaline phosphatase (ALP), gamma glutamyl transferase (GGT), total bilirubin (TB), conjugated bilirubin (CB) and lactate dehydrogenase (LDH) using commercial test kits (Randox Laboratories UK). Liver superoxide dismutase (SOD), catalase (CAT), malondialdehyde (MDA), glutathione peroxidase (GPX) and total protein were evaluated using commercial test kits according to manufacturer's specification.

Relative liver weight was calculated using the formula below:

$$\text{Relative liver weight} = \frac{\text{Liver weight}}{\text{Body weight}} \times 100$$

Histological analysis: After rats were sacrifice, liver samples were removed, rinsed and fixed in 10% phosphate buffered formalin. The fixed liver samples were embedded in paraffin blocks and sections of 5 µm were prepared and stained with Hematoxylin and Eosin (H and E). Stained sections were examined with the aid of a microscope.

Statistical analysis: Values are expressed as mean±standard error of mean (SEM). The differences between the groups were tested for significance using one-way analysis of variance (ANOVA) followed by Tukey's multiple comparison test. Significance was set at $p<0.05$, $p<0.01$ and $p<0.001$.

RESULTS

Phytochemical constituents of ethanolic leaf extract of *Ocimum gratissimum*: Phytochemical analysis of the ethanolic leaf extract of *Ocimum gratissimum* showed the presence of high concentrations of phenol, carbohydrate, proteins and terpenoids with moderate amounts of reducing sugar, glycosides, tannins and flavonoids. Low concentration of alkaloids, steroids, saponins and oil were found. Resins and acidic compounds were absent (Table 1).

Effects on serum liver function parameters, body and liver weights of albino rats: The effects of EEOG 50 mg kg^{-1}, EEOG 100 mg kg^{-1}, EEOG 200 mg kg^{-1} and MTX 20 mg kg^{-1} on body and liver weights of treated rats were not significant ($p>0.05$) when compared to control (Table 2). Also, the effects of EEOG 50 mg kg^{-1}, EEOG 100 mg kg^{-1} and EEOG 200 mg kg^{-1} were not significant ($p>0.05$) on serum AST, ALT, ALP, GGT, TB, CB and LDH levels when compared to control (Table 3). On the other hand, MTX 20 mg kg^{-1} treated rats showed marked and significant ($p<0.001$) elevations in serum AST, ALT ALP, GGT, TB, CB and LDH levels when compared to control (Table 3). In contrast, the serum levels of these parameters were significantly restored in a dose-dependent fashion in rats pretreated with EEOG. The

Table 1: Phytochemical constituents of ethanolic extract of *Ocimum gratissimum*

Phytochemicals	Amount
Carbohydrate	+++
Phenol	+++
Proteins	+++
Terpenoids	+++
Reducing sugars	++
Glycosides	++
Tannins	++
Saponins	+
Flavonoids	++
Alkaloids	+
Steroids	+
Oils	+
Resins	-
Acidic compounds	-

+++: High concentration, ++: Moderate amount, +: Low concentration, -: Absent

Table 2: Effects of *Ocimum gratissimum* extract and methotrexate on body and liver weights of albino rats

Groups (mg kg^{-1})	Initial body weight (g)	Final body weight (g)	Liver weight (g)	Relative liver weight (%)
Control (placebo)	235.2±12.7	243.7±10.1	8.22±0.13	3.37±0.07
EEOG 50	220.2±12.7	226.9±11.4	8.03±0.26	3.54±0.08
EEOG 100	210.4±16.4	220.7±10.1	8.16±0.23	3.70±0.23
EEOG 200	225.2±10.6	230.6±11.8	7.99±0.10	3.47±0.14
MTX 20	220.8±11.3	227.0±14.7	8.06±0.14	3.55±0.10
EEOG 50+MTX 20	210.8±10.4	226.4±12.0	8.19±0.13	3.62±0.15
EEOG100+MTX 20	228.4±14.6	235.2±13.1	7.92±0.02	3.37±0.68
EEOG 200+MTX 20	220.0±11.2	227.4±11.5	7.98±0.10	3.51±0.20

EEOG: Ethanolic leaf extract of *Ocimum gratissimum*, MTX: Methotrexate, Values are expressed as Mean±SEM (n = 6)

Table 3: Effects of treatments with *Ocimum gratissimum* extract and methotrexate on serum liver function parameters of albino rats

Groups (mg kg^{-1})	AST (U L^{-1})	ALT (UL^{-1})	ALP (U L^{-1})	GGT (U L^{-1})	CB (g dL^{-1})	TB (g dL^{-1})	LDH (U L^{-1})
Control (placebo)	50.7±6.23	55.5±6.00	64.0±4.32	0.81±0.08	3.71±0.43	7.90±0.31	63.2±7.38
EEOG 50	51.5±5.88	54.2±5.87	62.5±7.17	0.70±0.05	3.66±0.38	7.77±0.38	60.7±7.58
EEOG 100	49.5±4.42	53.5±5.52	61.6±5.94	0.71±0.03	3.66±0.43	7.63±0.46	61.9±10.0
EEOG 200	48.5±4.34	51.1±7.69	60.2±6.50	0.70±0.04	3.64±0.43	7.70±0.43	60.6±5.82
MTX 20	220.6±15.6^{a}	202.4±20.3^{a}	270.5±10.6^{a}	2.92±0.06^{a}	16.2±0.43^{a}	30.9±3.30^{a}	257.0±17.4^{a}
EEOG 50+MTX 20	140.1±21.3^{b}	116.8±11.7^{b}	200.4±11.1^{b}	1.90±0.22^{b}	10.3±0.24^{b}	21.5±2.75^{b}	181.4±10.6^{b}
EEOG 100+MTX 20	85.3±7.56^{c}	69.3±6.36^{c}	125.1±12.1^{c}	1.39±0.23^{c}	6.54±0.24^{c}	13.3±1.49^{c}	109.9±9.05^{c}
EEOG 200+MTX 20	53.5±6.81^{d}	43.0±5.93^{d}	65.6±6.58^{d}	0.73±0.01^{d}	3.40±0.12^{d}	8.19±1.25^{d}	70.6±5.68^{d}

EEOG: Ethanolic leaf extract of *Ocimum gratissimum*, MTX: Methotrexate, Values are expressed as Mean±SEM (n = 6), ^{a}Differ significantly from control at (p<0.001), ^{b}Differ significantly from MTX at p<0.05, ^{c}Differ significantly from MTX at p<0.01, ^{d}Differ significantly from MTX at p<0.001 (ANOVA). AST: Alanine aminotransferase, ALT: Aspartate aminotransferase, ALP: Alkaline phosphatase, GGT: Gamma glutamyl transferase, CB: Conjugated bilirubin, TB: Total bilirubin and LDH: Lactate dehydrogenase

Table 4: Effects of treatments with *Ocimum gratissimum* extract and methotrexate on liver tissue biochemical parameters of albino rats

Groups (mg kg^{-1})	AST (U L^{-1})	ALT (U L^{-1})	ALP (U L^{-1})	GGT (U L^{-1})	LDH (U L^{-1})
Control (placebo)	240.6±14.3	241.6±10.6	223.1±27.4	14.3±0.44	228.5±10.3
EEOG 50	233.4±12.8	238.4±11.7	218.9±29.3	14.2±0.42	212.6±12.6
EEOG 100	231.7±13.3	234.4±10.2	220.6±25.8	14.2±0.32	221.2±10.4
EEOG 200	228.6±10.7	229.1±13.0	219.2±29.8	14.1±0.13	222.7±13.2
MTX 20	835.7±15.8^{a}	982.9±15.0^{a}	859.3±38.6^{a}	55.8±1.99^{a}	982.1±16.9^{a}
EEOG 50+MTX 20	426.2±15.5^{b}	481.8±13.0^{b}	500.0±11.0^{b}	35.7±0.22^{b}	400.3±15.9^{b}
EEOG 100+MTX 20	333.9±10.7^{c}	350.7±10.8^{c}	349.3±13.0^{c}	21.6±0.11^{c}	357.9±17.1^{c}
EEOG 200+MTX 20	254.3±15.0^{d}	265.7±10.1^{d}	240.4±8.01^{d}	15.5±0.21^{d}	237.6±10.6^{d}

EEOG: Ethanolic leaf extract of *Ocimum gratissimum*, MTX: Methotrexate, Values are expressed as Mean±SEM (n = 6), ^{a}Differ significantly from control at (p<0.001), ^{b}Differ significantly from MTX at p<0.05, ^{c}Differ significantly from MTX at p<0.01, ^{d}Differ significantly from MTX at p<0.001 (ANOVA). AST: Alanine aminotransferase, ALT: Aspartate aminotransferase, ALP: Alkaline phosphatase, GGT: Gamma glutamyl transferase, LDH: Lactate dehydrogenase

parameters were significantly restored at p<0.05 in rats treated with EEOG 50 mg kg^{-1}+MTX 20 mg kg^{-1} when compared to MTX-treated rats. On the other hand, significant restorations in these parameters were obtained at p<0.01 in EEOG 100 mg kg^{-1}+MTX 20 mg kg^{-1} treated rats and at p<0.001 in EEOG mg kg^{-1} 200+MTX 20 mg kg^{-1} treated rats when compared to MTX-treated rats (Table 3).

Effect on liver biochemical parameters of albino rats: Normal (p>0.05) liver levels of AST, ALT, ALP, GGT and LDH were obtained in rats treated with EEOG 50 mg kg^{-1}, EEOG 100 mg kg^{-1} and EEOG 200 mg kg^{-1} when compared to control. The liver levels of the aforementioned parameters were significantly (p<0.001) elevated in MTX 20 mg kg^{-1} treated rats when compared to control (Table 4). However, increases in liver AST, ALT ALP, GGT and LDH levels obtained in MTX 20 mg kg^{-1} treated rats were restored in a dose-dependent manner in EEOG pretreated rats (Table 4). The above parameters were restored significantly (p<0.05) in rats treated with EEOG 50 mg kg^{-1}+MTX 20 mg kg^{-1} when compared to MTX-treated rats. However, significant restorations were obtained at p<0.01 in EEOG 100 mg kg^{-1} +MTX 20 mg kg^{-1} treated rats and at p<0.001 in EEOG mg kg^{-1} 200+MTX 20 mg kg^{-1} treated rats when compared to MTX-treated rats (Table 4).

Effects on liver oxidative stress markers of albino rats: Furthermore, the liver levels of SOD, CAT, GSH and GPX were normal (p>0.05) in rats treated with EEOG 50 mg kg^{-1}, EEOG 100 mg kg^{-1} and EEOG 200 mg kg^{-1} when compared to control (Table 5). In contrast, the liver levels of SOD, CAT, GSH and GPX were significantly (p<0.001) decreased whereas MDA levels were significantly (p<0.001) increased in MTX 20 mg kg^{-1} administered rats when compared to control (Table 5).

However, the liver levels of the aforementioned parameters were significantly restored in a dose-dependent manner in rats treated with EEOG 50 mg kg^{-1}+MTX 20 mg kg^{-1} ($p<0.05$), EEOG 100 mg kg^{-1}+MTX 20 mg kg^{-1} ($p<0.01$) and EEOG 200 mg kg^{-1}+MTX 20 mg kg^{-1} ($p<0.001$) when compared to MTX-treated rats (Table 5).

Effect on liver histology of albino rats: Furthermore, the Hand E stained section of the control liver showed normal hepatocytes (Fig. 1a) Also, normal hepatocytes were observed in the liver of rats treated daily with EEOG 50 mg kg^{-1}, EEOG 100 mg kg^{-1} and EEOG 200 mg kg^{-1}, respectively (Fig. 1b-d). On the contrary, the liver of

Table 5: Effects of *Ocimum gratissimum* extract and methotrexate on liver oxidative stress indices of albino rats

Groups (mg kg^{-1})	SOD (U/mg protein)	CAT (U/mg protein)	GSH (µg/protein)	MDA (nmol/mg protein)	GPX (U/mg protein)
Control (placebo)	41.4±4.21	57.7±5.00	20.2±2.11	0.18±0.08	19.0±2.93
EEOG 50	42.1±5.68	58.7±4.37	21.5±3.07	0.16±0.08	19.5±2.93
EEOG 100	43.6±5.10	59.6±5.96	22.0±2.49	0.15±0.09	20.9±3.73
EEOG 200	43.3±4.52	60.6±5.62	22.8±2.25	0.13±0.01	20.7±2.30
MTX 20	13.8±1.95[a]	20.0±4.15[a]	5.66±0.31[a]	0.88±0.04[a]	5.82±0.49[a]
EEOG 50 +MTX 20	20.6±2.75[b]	30.6±2.25[b]	7.73±0.14[b]	0.54±0.05[b]	7.85±0.16[b]
EEOG 100+MTX 20	28.4±3.81[c]	41.8±4.29[c]	9.30±0.50[c]	0.36±0.29[c]	11.4±0.55[c]
EEOG 200+MTX 20	40.2±4.45[d]	54.5±4.98[d]	15.0±2.17[d]	0.20±0.09[d]	16.0±2.44[d]

EEOG: Ethanolic leaf extract of *Ocimum gratissimum*, MTX: Methotrexate. Values are expressed as Mean±SEM (n = 6), [a]Differ significantly from control at ($p<0.001$), [b]Differ significantly from MTX at $p<0.05$, [c]Differ significantly from MTX at $p<0.01$, [d]Differ significantly from MTX at $p<0.001$ (ANOVA). SOD: Superoxide dismutase, CAT: Catalase, GSH: Reduced glutathione, MDA: Malondialdehyde, GPX: Glutathione peroxidase

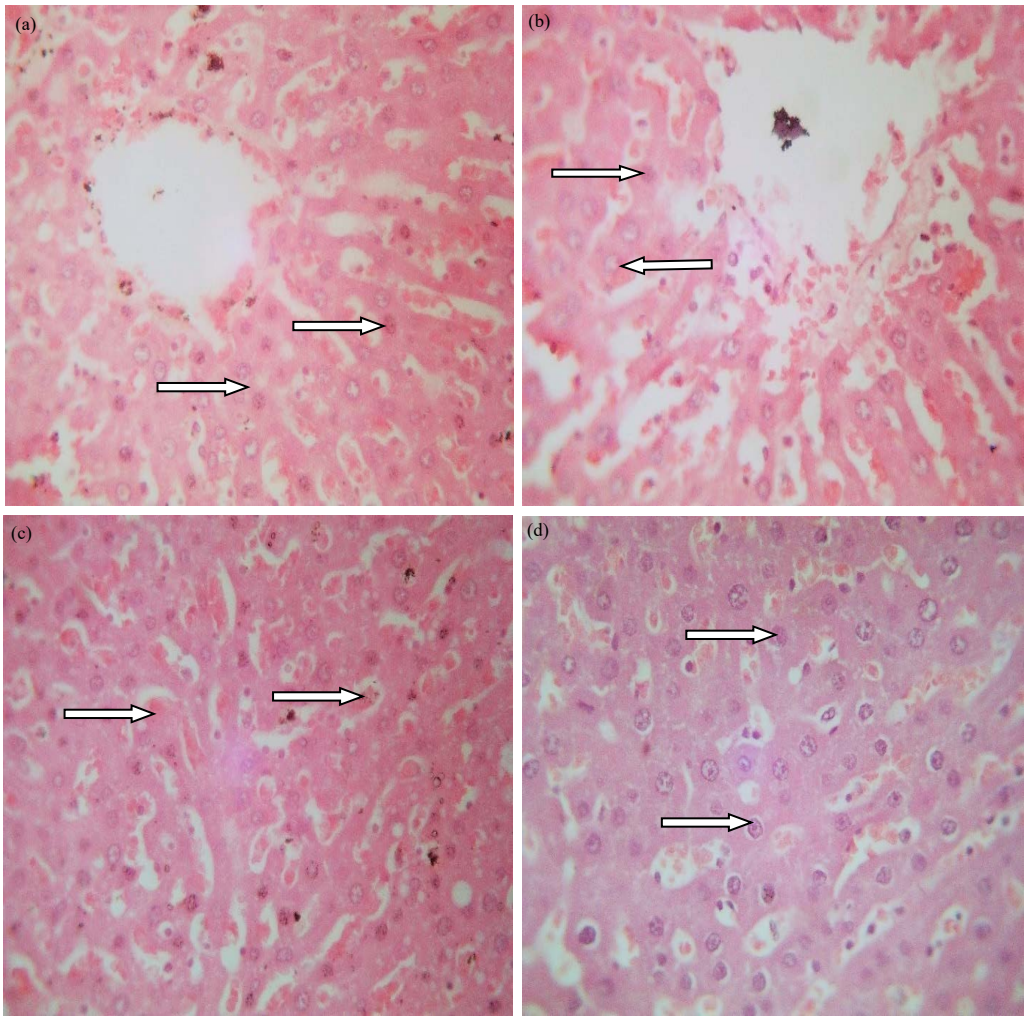

Fig. 1(a-h): Continued

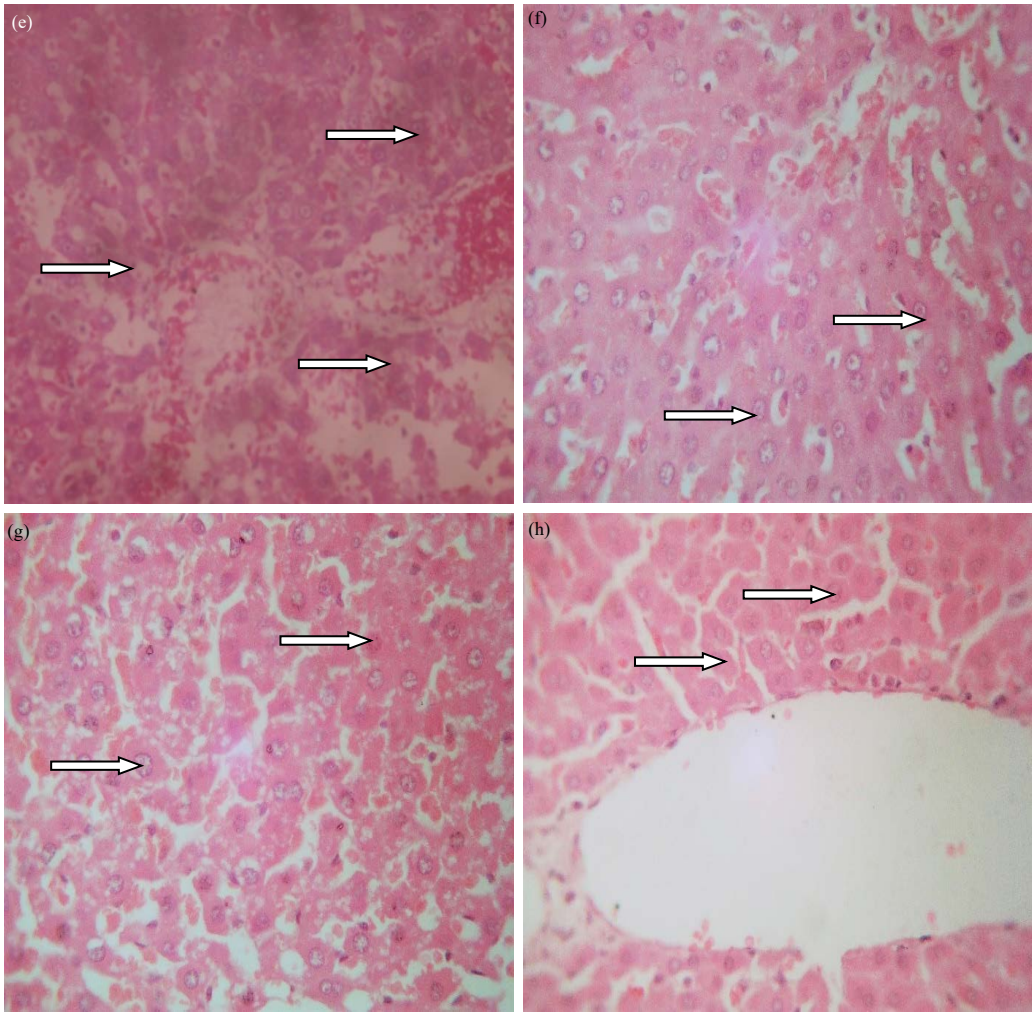

Fig. 1(a-h): Above are H and E stained sections of the liver. (a-d) Normal hepatocytes were observed in the control liver and the liver of rats treated with EEOG 50 mg kg^{-1}, EEOG 100 mg kg^{-1} and EEOG 200 mg kg^{-1}, respectively, (e) MTX 20 mg kg^{-1} treated rats showed hepatocyte necrosis, (f-h) Rats treated with EEOG 50 mg kg^{-1}+MTX 20 mg kg^{-1}, EEOG 100 mg kg^{-1}+MTX 20 mg kg^{-1} and EEOG mg kg^{-1} 200+MTX 20 mg kg^{-1}, respectively showed normal hepatocytes

MTX 20 mg kg^{-1} treated rat showed hepatocyte necrosis (Fig. 1e). On the other hand, the liver of rats treated with EEOG 50 mg kg^{-1} +MTX 20 mg kg^{-1} showed normal hepatocytes. Also, rats treated with EEOG 100 mg kg^{-1}+MTX 20 mg kg^{-1} and EEOG mg kg^{-1} 200+MTX 20 mg kg^{-1}, respectively showed normal hepatocytes (Fig. 1f-h).

DISCUSSION

Methotrexate (MTX) is a folic acid antagonist that is widely used as a cytotoxic chemotherapeutic agent for several malignancies and various inflammatory diseases. However, the use of MTX is associated with adverse effects of which hepatotoxicity is of great concern[18]. Some medicinal plants used in folklore for the treatment of liver diseases could be considered as alternative therapeutic approach for the treatment of liver diseases in humans[19]. Therefore, the present study assessed if the ethanolic leaf extract of *Ocimum gratissimum* (EEOG) can protect the liver of MTX-intoxicated albino rats. In the present study, the phytochemical evaluation of EEOG showed the presence of carbohydrate, protein, tannins, saponins, terpenoids, steroids, flavonoids, phenols and alkaloids. This finding is consistent with previous studies[20]. The safety profile of xenobiotics can be correlated with their effects on body and organ weights[21]. The administration of EEOG had no deleterious effects on

body and liver weights. Serum levels of AST, ALT, ALP, GGT, LDH, CB and TB are often used to assess hepatic damage. Liver injury causes membrane damage or necrosis, which allows the above parameters to circulate and be detected in the serum. Higher serum concentrations of the aforementioned parameters are indications of hepatic membrane damage[22]. Normal levels of AST, ALT, ALP, GGT, LDH, CB and TB were obtained in rats treated with EEOG. In contrast, the administration of MTX caused significant liver toxicity marked by elevated serum levels of AST, ALT, ALP, GGT, LDH, CB and TB. These observations are consistent with previous report[23]. However; the levels of the above parameters were restored in a dose-dependent manner in rats pretreated with EEOG. The observations in MTX-administered rats are clear signs of hepatic injury probably due to hepatic membrane damage leading to the leakage of the aforementioned parameters into the blood[24].

Oxidative stress represents a disturbance in the equilibrium status of prooxidant/antioxidant reactions in living organisms characterized by oxidant generation and antioxidant depletion. The reduction in the excess activities of free radicals in normal healthy cells is accomplished by a radical scavenging antioxidant defense system, consisting of superoxide dismutase (SOD), catalase (CAT) and reduced glutathione (GSH). Oxidative stress can occur as a consequence of increased free radical production or a reduction in antioxidant defense. Oxidative stress-induced decrease in antioxidant defense can activate the expression of a wide range of genes that can mediate the pathogenic effect of free radicals[25]. In the current study, MXT-treated rats showed decreased liver antioxidant defense marked by decreased liver activities of SOD, CAT, GSH and GPX. This observation is consistent with some reports[5]. However, there were up-regulations in the liver levels of SOD, CAT, GPX and GSH in rats pretreated with EEOG in a dose-dependent manner. Malondialdehyde (MDA) is the primary and major reactive aldehyde produced from the peroxidation of biological lipids. It is used as an indicator of tissue damage and the destruction of lipid layers involving lipid peroxidation cascades[26]. The current study observed marked lipid peroxidation in the liver of MTX-administered rats characterized by elevated levels of MDA. Similar findings have been previously reported[27]. However, this study observed decreased lipid peroxidation marked by decreased MDA levels in the liver of EEOG pretreated rats in a dose-dependent manner. In the current study, examination of the liver of MTX-administered rats showed hepatocyte necrosis. Similar observations have been previously reported[28]. This observation is probably due to MTX-induced lipid peroxidation which might have caused damage to micromolecules in the liver. Lipid peroxidation has been implicated in the pathogenesis of numerous diseases as well as in drug-associated toxicity[29].

In contrast, examination of the liver of rats pretreated with EEOG showed the absence of hepatocyte necroses. The underlying mechanism by which MTX causes hepatotoxicity has not been fully identified; however, several distinct mechanisms have been proposed. These included the direct toxic effect of MTX on the liver and the induction of oxidative stress. Also, the inhibition of folic nucleic acids synthesis, thereby blocking the synthesis of nucleic acids, amino acids and proteins has been proposed. These actions can damage organelles and membranes of hepatic parenchymal cells thereby, interfering with their functions and allowing leakage of enzymes[30]. In this study, the observed hepatoprotective effect of EEOG can be correlated with report on the anti-hepatotoxic activity of the aqueous extract of OG against CCl_4-induced hepatotoxicity in albino rats[31]. In the current study, the abrogative effect of EEOG against MTX-induced liver toxicity can be attributed to its ability to inhibit MTX-induced oxidative stress by scavenging and neutralizing free radicals before reaching their target sites. This activity can be attributed to the phytochemical constituents of EEOG. EEOG contains tannins, flavonoids and phenols which have long been recognized to have antioxidant activities[32]. Also, flavonoids, tannins and polyphenols can stabilize and preserve the integrity of hepatocyte membrane, facilitating hepatocyte regeneration and hepatocellular protein synthesis[33,34].

CONCLUSION

The finding in this study showed that *Ocimum gratissimum* has potential as remedy for methotrexate-associated hepatotoxicity however; further study is required for the elucidation of the phytochemical constituent that is associated with the observed effect.

SIGNIFICANCE STATEMENT

This study discovered that *Ocimum gratissimum* can be beneficial in abrogating methotrexate associated hepatotoxicity. Findings in this study will help researchers to uncover critical areas of treating methotrexate associated hepatotoxicity that were not explored. Thus, a new theoretical mechanism of methotrexate-induced hepatotoxicity as well as the abrogative potential of *Ocimum gratissimum* may be arrived at.

ACKNOWLEDGMENT

The authors appreciate Dr. Obuma Yibala of the Department of Medical Laboratory Sciences, Niger Delta University, Amassama, Nigeria for histological analysis of the liver tissues.

REFERENCES

1. Sharma, A., K.K. Chakraborti and S.S. Handa, 1991. Anti-hepatotoxic activity of some Indian herbal formulations as compared to silymarin. Fitoterapia, 62: 229-235.
2. Sharma, A., R. Houshyar, P. Bhosale, J.I. Choi, R. Gulati and C. Lall, 2014. Chemotherapy induced liver abnormalities: An imaging perspective. Clin. Mol. Hepatol., 20: 317-326.
3. Moghadam, A.R., S. Tutunchi, A. Namvaran-Abbas-Abad, M. Yazdi and F. Bonyadi *et al*., 2015. Pre-administration of turmeric prevents methotrexate-induced liver toxicity and oxidative stress. BMC Compl. Alternat. Med., Vol. 15. 10.1186/s12906-015-0773-6.
4. Hoekstra, M., A.E. van Ede, C.J. Haagsma M.A.F.J. van de Laar and T. Huizinga *et al*., 2003. Factors associated with toxicity, final dose and efficacy of methotrexate in patients with rheumatoid arthritis. Ann. Rheum. Dis., 62: 423-426.
5. Ali, N., S. Rashid, S. Nafees, S.K. Hasan and S. Sultana, 2014. Beneficial effects of chrysin against methotrexate-induced hepatotoxicity via attenuation of oxidative stress and apoptosis. Mol. Cell. Biochem., 385: 215-223.
6. Tabassum, H., S. Parvez, S.T. Pasha, B.D. Banerjee and S. Raisuddin, 2010. Protective effect of lipoic acid against methotrexate-induced oxidative stress in liver mitochondria. Food Chem. Toxicol., 48: 1973-1979.
7. Farrow, A.C., G.R. Buchanan, R.J. Zwiener, W.P. Bowman and N.J. Winick, 1997. Serum aminotransferase elevation during and following treatment of childhood acute lymphoblastic leukemia. J. Clin. Oncol., 15: 1560-1566.
8. Tian, H. and B.N. Cronstein, 2007. Understanding the mechanisms of action of methotrexate: Implications for the treatment of rheumatoid arthritis. Bull. NYU Hosp. Jt. Dis., 65: 168-173.
9. Bahadori, M.D., H. Valizadeh and M.M. Farimani, 2016. Chemical composition and antimicrobial activity of the volatile oil of *Salvia santolinifolia* Boiss. from southeast of Iran. Pharm. Sci., 22: 42-48.
10. Prabhu, K.S., R. Lobo, A.A. Shirwaikar and A. Shirwaikar, 2009. *Ocimum gratissimum*: A review of its chemical, pharmacological and ethnomedicinal properties. Open Complement. Med. J., 1: 1-15.
11. Alexander, P., 2016. Phytochemical screening and mineral composition of the leaves of *Ocimum gratissimum* (scent leaf). Int. J. Applied Sci. Biotechnol., 4: 161-165.
12. Sahoo, D. and A. Kumar, 2013. Secondary metabolites of *Ocimum gratissimum* and their biological activities. Int. Res. J. Pharm., 8: 10-28.
13. Khoury, T., A.A. Rmeileh, L. Yosha, A.A. Benson, S. Daher and M. Mizrahi, 2015. Drug induced liver injury: Review with a focus on genetic factors, tissue diagnosis and treatment options. J. Clin. Transl. Hepatol., 3: 99-108.
14. Erdogan, E., Y. Ilgaz, P.N. Gurgor, Y. Oztas, Y. Topal and E. Oztas, 2015. Rutin ameliorates methotrexate induced hepatic injury in rats. Acta. Cir. Bras., 11: 778-784.
15. Adedosu, O.T., J.A. Badmus, O.K. Afolabi and O.F. Yakubu, 2012. Effect of methanolic leaf extract of *Ocimum gratis simum* (Linn) leaves on sodium arsenite-induced toxicity in rats. J. Pharm. Toxicol., 7: 259-266.
16. Harborne, J.B., 1973. Phytochemical Methods: A Guide to Modern Techniques of Plant Analysis. 1st Edn., Chapman and Hall, London, UK., ISBN: 978-94-009-5921-7, Pages: 271.
17. Trease, G.E. and W.C. Evans, 1989. A Text-book of Parmacognosy. Bailliere Tinall Ltd., London, pp: 53.
18. Jahovic, N., H. Cevik, A.O. Sehirli, B.C. Yegen and G. Sener, 2003. Melatonin prevents methotrexate-induced hepatorenal oxidative injury in rats. J. Pineal Res., 34: 282-287.
19. Samudram, P., H. Rajeshwari, R. Vasuki, A. Geetha and P.S. Moorthi, 2008. Hepatoprotective activity of bi-herbal ethanolic extract on CCl_4 induced hepatic damage in rats. Asian J. Biochem., 3: 308-314.
20. Adikwu, E. and B. Bokolo, 2018. Ethanolic leaf extract of *Ocimum gratissimum* ameliorates methotrexate-induced nephrotoxicity in albino rats. Asian J. Med. Sci., 9: 37-43.
21. Jamshidzadeh, A., R. Heidari, F. Abazari, M. Ramezani and F. Khodaei *et al*., 2016. Antimalarial drugs-induced hepatic injury in rats and the protective role of carnosine. Pharm. Sci., 22: 170-180.
22. Akhtar, N., M.K. Srivastava and R.B. Raizada, 2009. Assessment of chlorpyrifos toxicity on certain organs in rat, *Rattus norvegicus*. J. Environ. Biol., 30: 1047-1053.
23. Shehab, N.G., E. Abu-Gharbieh and F.A. Bayoumi, 2015. Impact of phenolic composition on hepatoprotective and antioxidant effects of four desert medicinal plants. BMC Complement. Altern. Med., Vol. 15. 10.1186/s12906-015-0919-6.
24. Malhi, H. and G.J. Gores, 2008. Cellular and molecular mechanisms of liver injury. Gastroenterology, 134: 1641-1654.
25. Nita, M. and A. Grzybowski, 2016. The role of the reactive oxygen species and oxidative stress in the pathomechanism of the age-related ocular diseases and other pathologies of the anterior and posterior eye segments in adults. Oxid. Med. Cell Long., Vol. 23. 10.1155/2016/3164734.
26. Ohkawa, H., N. Ohishi and K. Yagi, 1979. Assay for lipid peroxides in animal tissues by thiobarbituric acid reaction. Anal. Biochem., 95: 351-358.

27. Kose, E., H.I. Sapmaz, E. Sarihan, N. Vardi, Y. Turkoz and N. Ekinci, 2012. Beneficial effects of montelukast against methotrexate-induced liver toxicity: A biochemical and histological study. Scient. World J., Vol. 2012. 10.1100/2012/987508.
28. Ozogul, B., A. Kisaoglu, M.I. Turan, D. Altuner, E. Sener, N. Cetin and C. Ozturk, 2013. The effect of mirtazapine on methotrexate-induced toxicity In rat liver. ScienceAsia, 39: 356-336.
29. Deavall, D.G., E.A. Martin, J.M. Horner and R. Roberts, 2012. Drug-induced oxidative stress and toxicity. J. Toxicol., Vol. 2012. 10.1155/2012/645460.
30. Tousson, E., Z.T. Zaki, W.A. Abu-Shaeir and H. Hassan, 2014. Methotrexate-induced hepatic and renal toxicity: Role of L-carnitine in treatment. Biomed. Biotechnol., 2: 85-92.
31. Arhoghro, E.M., K.E. Ekpo and G.O. Ibeh, 2009. Effect of aqueous extract of scent leaf (*Ocimum gratissimum*) on carbon tetrachloride (CCl_4) induced liver damage in albino Wister rats. Afr. J. Pharm. Pharmacol., 3: 562-567.
32. Njoku, O.U., P.E. Joshua, C.V. Agu and N.C. Dim, 2011. Antioxidant properties of *Ocimum gratissimum*. N. Y. Sci. J., 4: 98-103.
33. Safer, A.M., M. Afzal, N. Hanafy and S. Mousa, 2015. Green tea extract therapy diminishes hepatic fibrosis mediated by dual exposure to carbon tetrachloride and ethanol: A histopathological study. Exp. Ther. Med., 9: 787-794.
34. Pezeshki, A., S. Safi, A. Feizi, G. Askari and F. Karami, 2016. The effect of green tea extract supplementation on liver enzymes in patients with nonalcoholic fatty liver disease. Int. J. Prev. Med., Vol. 7. 10.4103/2008-7802.173051.