ISSN 1996-3351

Asian Journal of Biological Sciences

http://knowledgiascientific.com

Knowledgia SCIENTIFIC
A Place to Publish Outstanding Research

OPEN ACCESS Asian Journal of Biological Sciences

ISSN 1996-3351
DOI: 10.3923/ajbs.2020.23.32

Research Article
Histogenesis of the Vomeronasal Organ in New Zealand White Rabbits

Neama Talha, Dalia Ibrahim, Mahmoud Awad and Yasser Ahmed

Department of Histology, Faculty of Veterinary Medicine, South Valley University, Qena, Egypt

Abstract

Background and Objective: Vomeronasal organ (VNO) mediates the chemosensory communication. The VNO is well developed in the rabbit, however, the information about its embryonic development is lack. The current study aimed to summarize the developmental phases of the VNO development in the rabbits. **Materials and Methods:** Pregnant rabbit does were euthanized and their fetuses were collected at 14, 17, 23, 25 and 30 days of gestation. The VNO were dissected from fetuses and processed for histological examination. **Results:** On day 14 of gestation; the olfactory placodes began as 2 epidermal thickenings, latero-ventral to the nasal septum. The 2 epithelia of the VNO lumen were a slit-like shape. On day 17, the VNO was kidney-shaped with a lateral concavity. It showed a thin lateral and thick medial wall. Blood sinuses and few nerve bundles appeared in lamina propria. On day 23, the outline of the VNO showed a crescent-shaped lumen. A few less-developed vomeronasal glands appeared in the lamina propria of the lateral and medial sides of the nasal cavity, where blood sinuses started to occupy larger spaces. On day 25, the VNO was partially enclosed by J-shaped hyaline cartilage and its lumen was oval in the coronal section. On day 30, the VNO grew reaching the adult size and its surrounding structures were enclosed in the J-shaped hyaline cartilage. **Conclusion:** This study described the histological changes of VNO in rabbit embryos. That can be beneficial for understanding the physiology of the VNO in the rabbit and other species.

Key words: Rabbits, embryo, vomeronasal organ, epithelium, cartilage, histological development, olfactory organ

Citation: Neama Talha, Dalia Ibrahim, Mahmoud Awad and Yasser Ahmed, 2020. Histogenesis of the vomeronasal organ in New Zealand white rabbits. Asian J. Biol. Sci., 13: 23-32.

Corresponding Author: Yasser Ahmed, Department of Histology, Faculty of Veterinary Medicine, South Valley University, Qena, Egypt

Competing Interest: The authors have declared that no competing interest exists.

Data Availability: All relevant data are within the paper and its supporting information files.

INTRODUCTION

The olfactory system or sense of smell of terrestrial vertebrates is part of the sensory system used for smelling. It is divided into 2 systems: The main olfactory system, which is involved in social communication and the accessory olfactory system which is related to the reproductive functions[1]. The VNO is a component of the accessory olfactory system[2,3], which is involved in the process of pheromones[4]. The mammalian VNO is an auxiliary olfactory sense organ or chemoreceptor organ important for many species and plays a key role in social and sexual functions. The function of VNO has been linked to the detection of pheromones that are chemical messages signaling information to other members of the same species and are important in mammalian reproduction[5,6]. The mammalian VNO is a paired tubular structure, located bilaterally along the base of the nasal septum. During the ontogeny, it originates from the medial wall of the nasal pit[7]. The development of the mammalian VNO has been studied in different species such as hamster[8], mouse[9], humans[10], sheep[11] in, goats[12], rats[7], human[13], in camel[14] and bovine[15]. The VNO is partially enclosed with a J-shaped ring of the vomeronasal cartilage. The VNO consists of 3 components; a duct, which is covered by non-sensory and sensory epithelium, parenchyma that is made up of connective tissue, arteries, veins, nerves and glands and a cartilage and bone enclosing all these structures[16].

The olfactory system is well developed in rabbits[17]. Thus, the rabbit is the animal model used for chemosensory-communication studies[18]. Rabbits are born deaf and blind depending on their VNOs in their social and innate behavior[19]. The newly born mammals and especially those without a functional visual or auditory system like rabbits need their sense of smell to enable them to recognize their mothers, nests or other features of their environment. Several studies have referred to increase acknowledgment of the value of the developmental approach to understanding odor perception and olfactory function[20-23]. However, there is a lack of information so the histological development of the VNO in embryonic rabbits. The study aimed to design, categorize, define and demonstrate the onset of appearance, origin and developmental sequence of rabbit VNO and its associated structures.

MATERIALS AND METHODS

Study area: The present study was carried out at a private rabbit farm in Aswan city, Egypt. The laboratory work was carried out in the laboratory of Histology Department, Faculty of Veterinary Medicine, South Valley University, Egypt. The experimental work lasted three months from 1 September to 31 December, 2018.

Animals: New Zealand white pregnant rabbit does (n = 20) were fed on pelleted commercial complete feed diet according to NRC recommendations. Does were fed *ad libitum* twice daily at 8 am and 4 pm. Clean drinking water was available all day. The average temperature was 27-32 and the average was 24-31%.

Sampling and fixation: Pregnant rabbit does were humanely euthanized in different pregnant stages; 14, 17, 23, 25 and 30 days and their fetuses were collected and rapidly perfused by physiological saline, followed by 10% neutral buffered formalin. After perfusion, the rostral part of the skull containing the intact nasal cavity was dissected out and immersed in 10% formalin.

Sample processing for light microscopic observation: Fixed specimens were dehydrated in ascending grades of alcohols, cleared in 2 changes of methyl benzoate and embedded in paraffin wax. Specimens were processed to prepare paraffin blocks. Sections (5 mm thick) were stained with hematoxylin and eosin (Hx and E) for general histological examination. Periodic acid schiff (PAS) and alcian blue (AB) for detection of mucin and Safranin-O (SO) for detection of the primordia of cartilage cells. Paraffin sections were examined and photographed with a light microscope at different magnification.

RESULTS

14th day of gestation: The VNO was located on the medial wall of the right and left olfactory pits and showed ductal structure. Its lumen was slit-like being surrounded by a thick epithelium (Fig.1a, b). The thickness of the epithelium was different between the lateral and medial walls in the VNO. The thick characteristic sensory epithelium (SE) was roughly divided into 3 layers. The 1st layer was the apical layer and the most superficial where the supporting cells (SC) were present. The 2nd layer was the basal layer where the basal cells (BC) located adjacent to the basement membrane. The 3rd layer was the intermediate layer which intervenes between the apical and basal layer and consists of neuro-receptor cells (NrC) (Fig. 1c, d). There was no appearance of goblet cells, no glands no nerve bundles in lamina propria (Fig. 1a, b). The vomeronasal cartilage (VNC) showed immature cartilage cells when stained with SO stain (Fig. 1c, d).

17th day of gestation: At this age, the vomeronasal complex preceded its growth (Fig. 2a, b). The VNO was

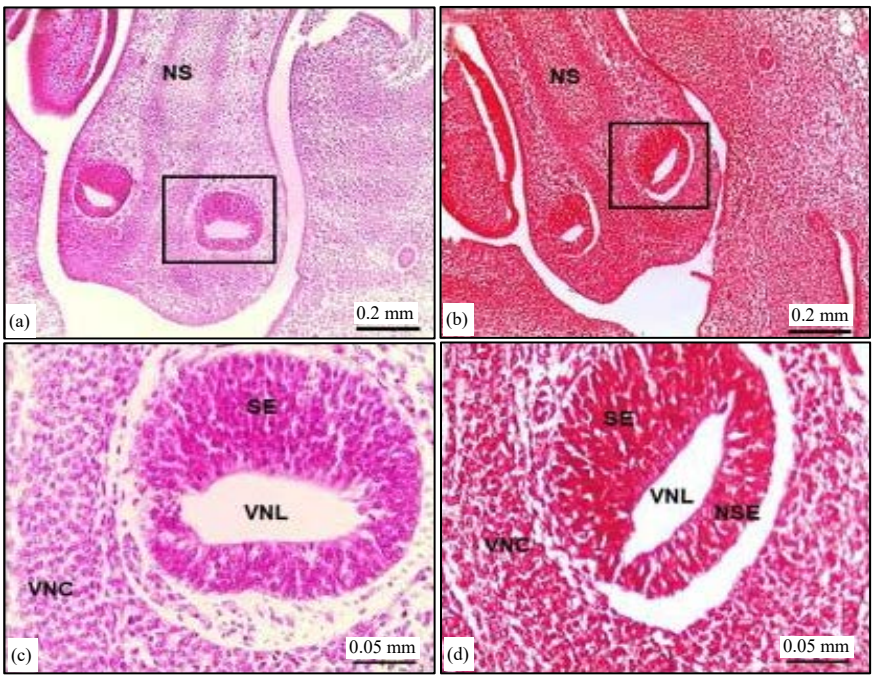

Fig. 1(a-d): Paraffin sections of the VNO from 14 days-old-rabbit-embryos, (a, b) Histological structure of the VNO at the nasal septum (NS) stained with Hx and E and Safranin-O, showing the primordia of the cartilage and (c, d) Higher magnification of VNO in the frame of (a, b), respectively

VNL: Vomeronasal lumen, SE: Sensory epithelium, NSE: Non-sensory epithelium, VNC: Vomeronasal cartilage

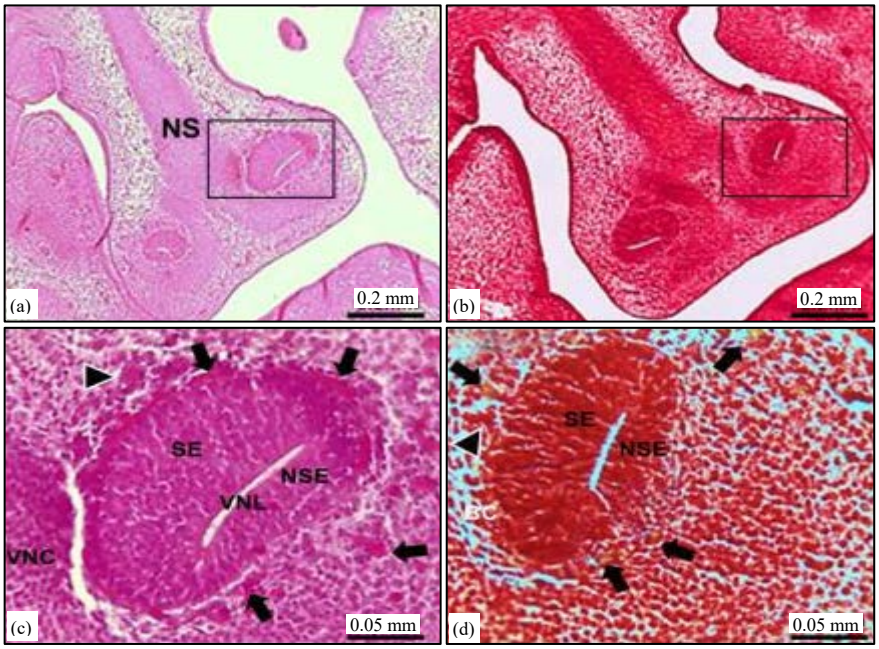

Fig. 2(a-d): Paraffin sections of the VNO from 17 days-old-rabbit-embryos, (a, b) Histological structure of the VNO at the nasal septum (NS) stained with Hx and E and Safranin-O and (c, d) Higher magnification of VNO in the frame of (a, b), respectively

Arrows: First appearance of blood sinuses, Arrowheads: Nerve bundles, VNL: Vomeronasal lumen, SE: Sensory epithelium, NSE: Non-sensory epithelium, VNC: Vomeronasal cartilage

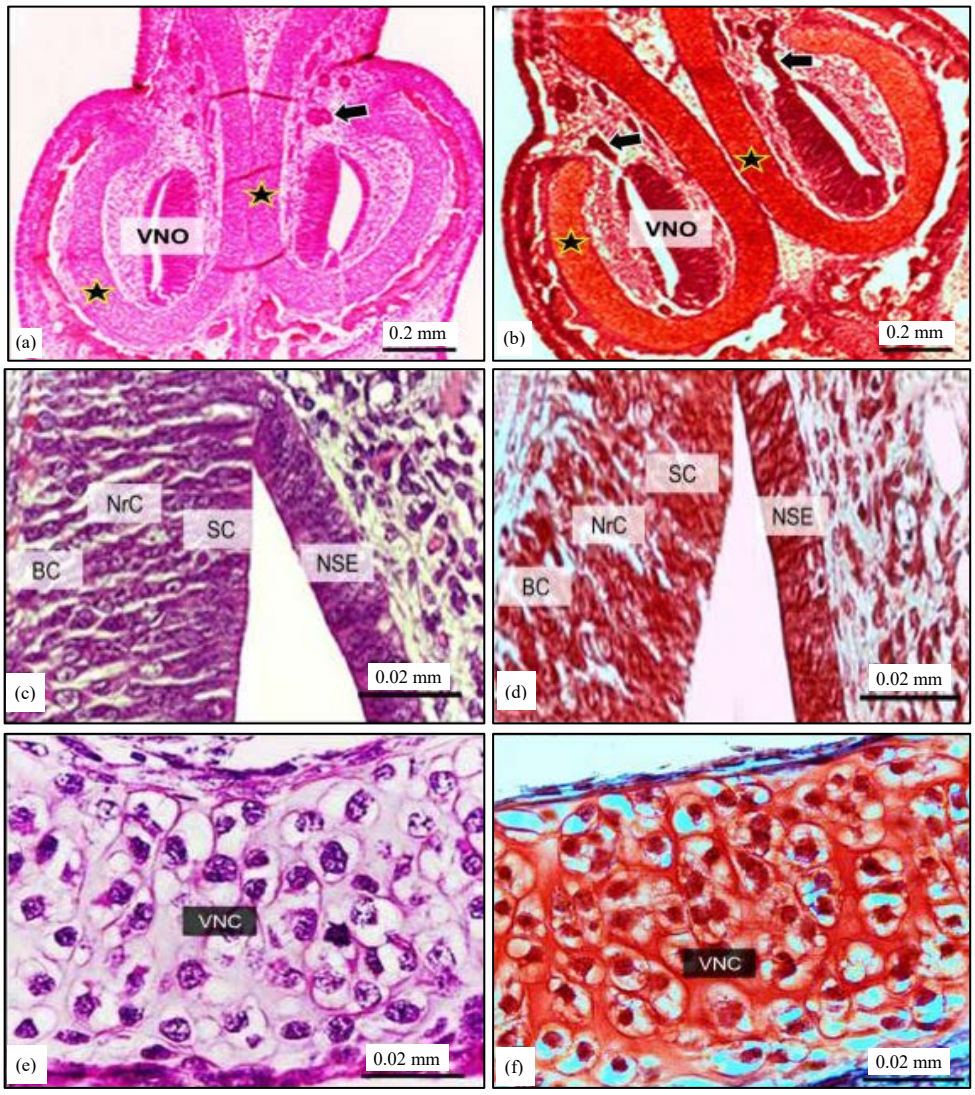

Fig. 3(a-f): Paraffin sections of the VNO from 23 days-old-rabbit-embryos, (a, b) Histological structure of the VNO stained with Hx and E and Safranin-O, (c, d) A higher magnification stained with Hx and E and Safranin-O and (e, f) Vomeronasal cartilage of hyaline type (VNC) stained with Hx and E and Safranin-O

Stars: VNO is incompletely surrounded with J-shaped vomeronasal cartilage, Arrows: First appearance of the primordia of vomeronasal glands at the dorsal boundaries of the vomeronasal lumen, BC: Basal cells, NrC: Neuroreceptor, SC: Supporting cells, NSE: Non-sensory epithelium

kidney-shaped with its concavity laterally located. The lateral wall was thin and had smaller and densely-crowded cells, while the medial wall was thicker and had more flattened cells. Blood sinuses appeared toward the basal portion of the medial and lateral vomeronasal epithelia (Fig. 2c, d). There was no appearance of goblet cells, no glands, but few nerve bundles appeared at lamina propria (Fig. 2c, d). The VNC was C-shaped showing cartilage cells that were still at the immature state when stained with SO stain (Fig. 2c, d).

23rd day of gestation: The outline of the VNO in this age showed a crescent-shaped lumen and most of the organ was protected by almost mature cartilaginous capsule. The primordia of the vomeronasal glands (VNG) appeared in the lamina propria of the ventrolateral and dorsomedial side of the VNO (Fig. 3a, b). Blood sinuses occupied a larger space in lamina propria than the previous age. The VNO was lined with 2 types of epithelia: The sensory epithelium (SE) and the non-sensory epithelium (NSE). The SE was a pseudostratified epithelium containing 3 morphologically

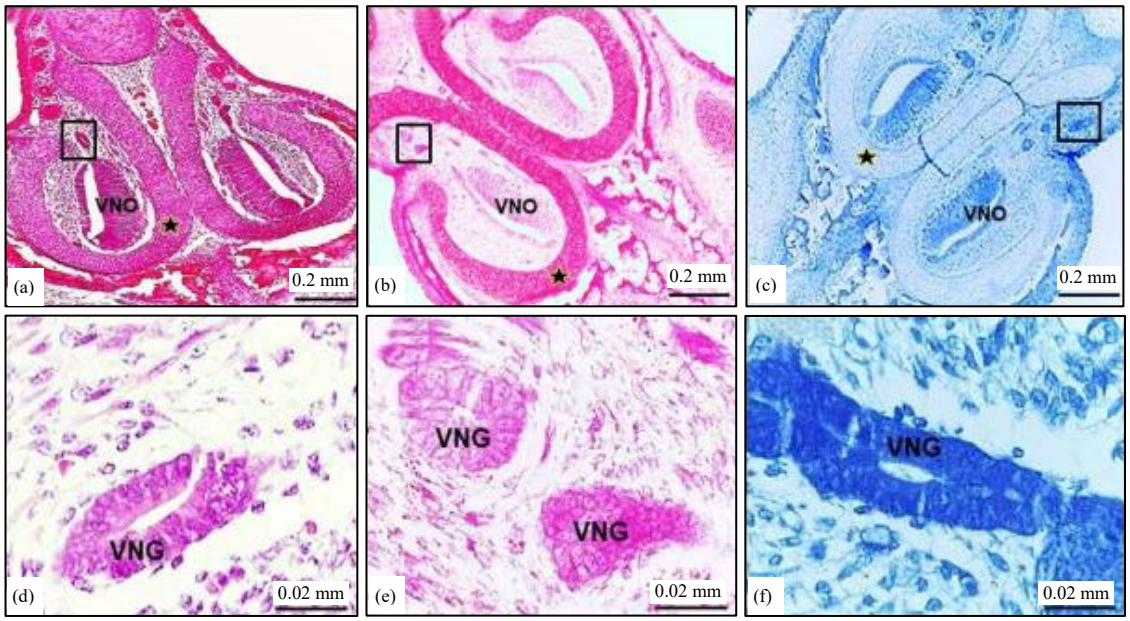

Fig. 4(a-f): Paraffin sections of the VNO from 23 days-old-rabbit-embryos, (a-c) Histological structure of the VNO stained with Hx and E, PAS and AB and (d-f) High magnification of the frame in (a-c)
Stars: VNO is incompletely surrounded with J-shape vomeronasal cartilage, VNG: Vomeronasal glands

identifiable cell types SC, NrC and BC. The SCs were columnar in shape occupying the whole thickness of the epithelium. They had spindle-shaped dark nuclei situated in the upper part of the epithelium. The NrCs were detected in the whole thickness of the epithelium and they were lighter in staining than the SCs. Their nuclei were pale and covered most of the middle and lower parts of the epithelial thickness. The BCs were located at the lower part of the epithelium. They appeared ovoid in section and their nuclei were relatively large and darkly-stained (Fig. 3c, d). The VNC showed cartilage cells they were still at the immature state and appeared more condensed than the previous age when stained with Hx and E and SO stain (Fig. 3e, f). The VNG showed a positive reaction when stained with Hx and E (Fig. 4a, d), PAS stain (Fig. 4b, e) and AB stain (Fig. 4c, f).

25th day of gestation: The VNO appeared as a tube located bilaterally at the base of the nasal septum. The VNO was partially enclosed by J-shaped hyaline cartilage, which appeared incomplete at its dorsolateral region. The lumen was oval in shape in the coronal section (Fig. 5a, b). The SE appeared with its pseudostratified nature and the three cell types started to be more obvious. The SC nuclei appeared at the upper part of the epithelium with their darkly stained nuclei with more apparent cytoplasm in between. The receptor neurons appeared to be at different stages of maturity as noted by the density of nuclei i.e., some of them with light nuclei and visible nucleoli and others with relatively darker nuclei (Fig. 5c, d). No goblet cells appeared. The VNC showed cartilage cells they were still at the immature state and appeared more condensed than the previous age when stained with Hx and E and SO stain (Fig. 5e, f). The VNG showed a positive reaction when stained with Hx and E (Fig. 6a, d), PAS stain (Fig. 6b, e) and AB stain (Fig. 6c, f).

30th day of gestation: At this age, A result that came the VNO grew to adult size with its surrounding structures. The lumen increased in size, the glands and blood sinuses became more developed and all were enclosed in the J-shaped hyaline cartilage. The lumen of VNO was wider than the previous age (Fig. 7a, b). SCs were more organized in their arrangements all over the epithelial thickness with their nuclei occupying the upper region of the epithelium. Their nuclei became more lightly stained. The neurons became more developed appeared at different stages of maturity, with highly differentiated cells predominating. The nuclei increased in size and became more rounded with prominent nucleoli. More BCs could be detected at this age (Fig. 7c, d). The

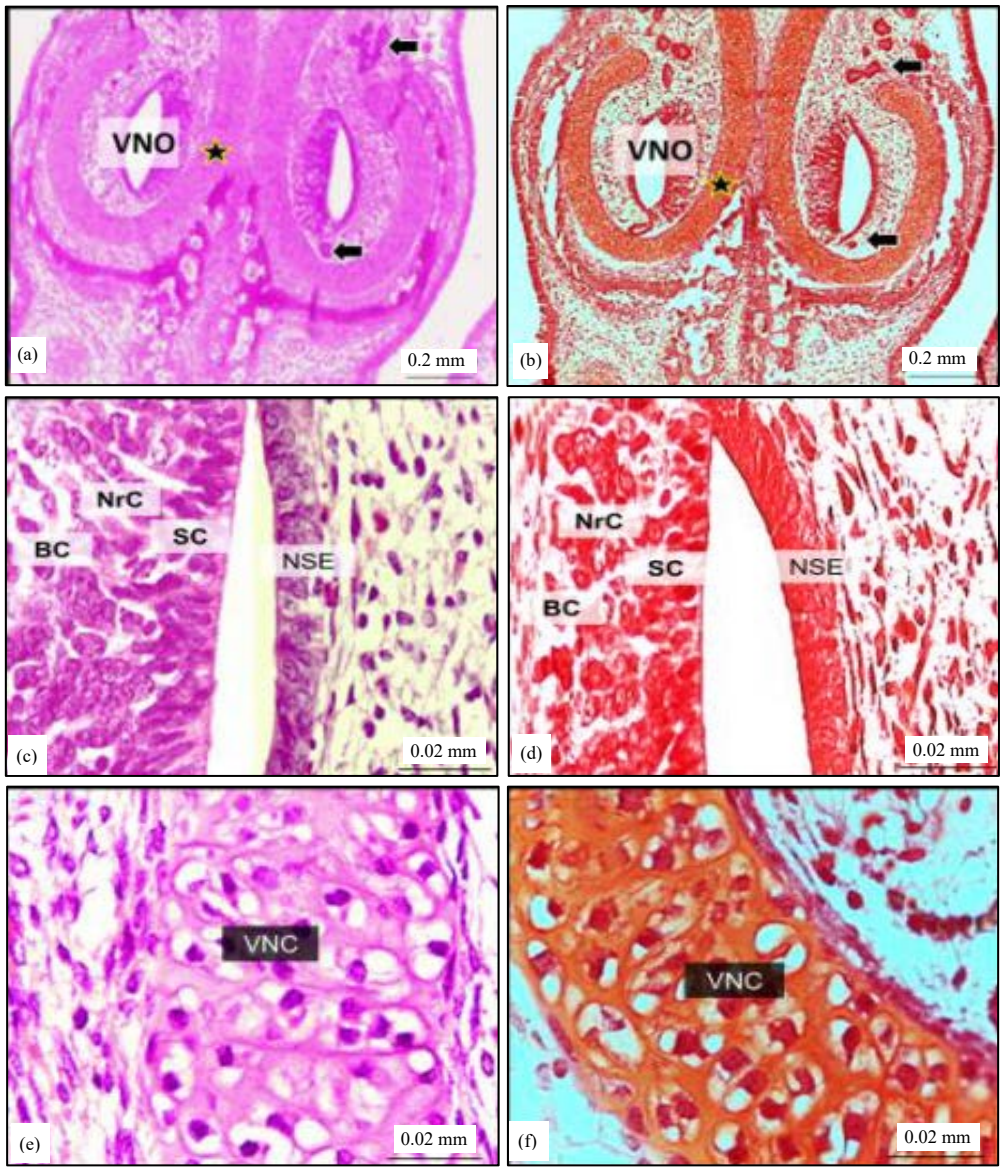

Fig. 5(a-f): Paraffin sections of the VNO from 25 days-old-rabbit-embryos, (a, b) Histological structure of the VNO stained with Hx and E and Safranin-O, (c, d) A higher magnification stained with Hx and E and Safranin-O and (e, f) Vomeronasal cartilage of the organ (VNC) stained with Hx and E and Safranin-O

Stars: VNO surrounded by a J-shaped vomeronasal cartilage, Arrows: Vomeronasal glands were determined at the dorso-ventral commissure of the vomeronasal lumen some of them were luminized and others were obliterated, BC: Basal cells, NrC: Neuroreceptor, SC: Supporting cells, NSE: Non-sensory epithelium

VNC showed cartilage cells they were still at the immature state and appeared more condensed than the previous age when stained with Hx and E and SO stain (Fig. 7e, f). The VNG showed a positive reaction when stained with Hx and E (Fig. 8a, d), PAS stain (Fig. 8b, e) and AB stain (Fig. 8c, f). The VNG appeared more mature than the previous age lined by cuboidal cells with basally-located flattened nuclei (Fig. 8d-f).

DISCUSSION

It is fully believed by earlier investigators that the VNO is embryologically-derived from the olfactory placode. The primordium of VNO is detected as a thickening in the epithelium of the medial wall of the olfactory pit. The organ was enclosed via the immature VNC, which appeared but densely arranged in small amorphous cells. The medial and

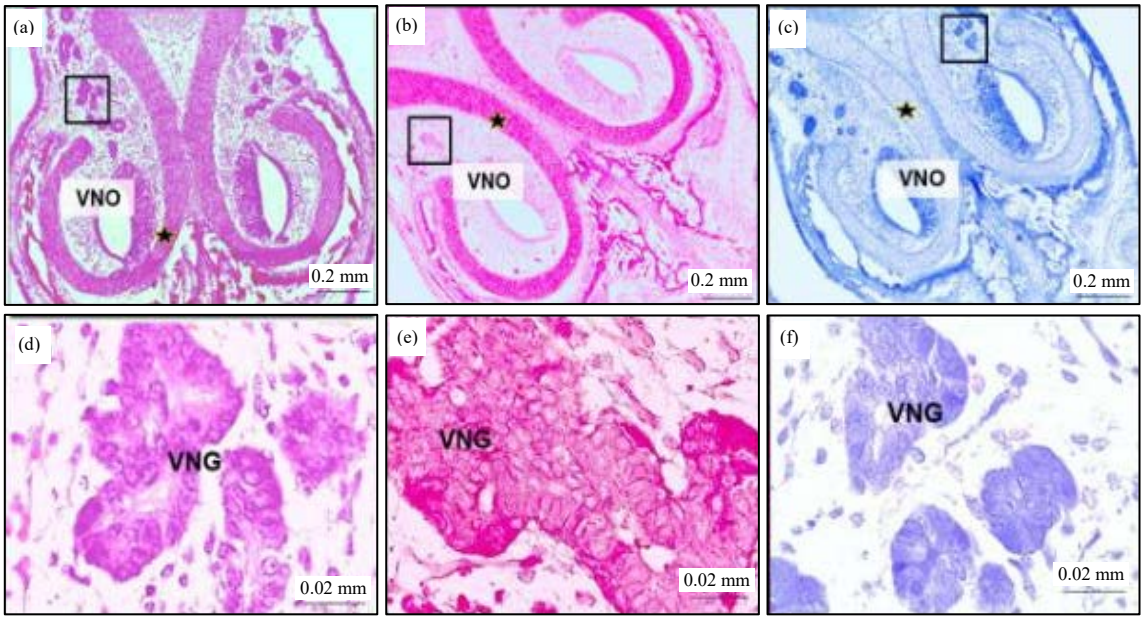

Fig. 6(a-f): Paraffin sections of the VNO from 25 days-old-rabbit-embryos, (a-c) Histological structure of the VNO stained with Hx and E, PAS and AB and (d-f) High magnification of the frame in (a-c)

Stars: VNO surrounded incompletely with J-shape vomeronasal cartilage, conspicuous compound acinar vomeronasal glands (VNG) lined by cuboidal cells with basal located flatten nuclei

lateral sides of the nostrils showed the miniature of nasal cartilages. This thick epithelium invaginates to form first the vomeronasal groove. Then by fusion of the lips of this groove a tubular structure, opening rostrally into the proper olfactory pit at 14th days age of rabbit embryo. The result came in agreement with a study has been published in hamster[8], where, it was mentioned that the VNO was embryologically derived from the olfactory placode. The tubular structures differentiated on the day 12 of gestation in the rat and mouse[24] and on the day 11 in the golden hamster[25]. In humans, during the 5th week, the ectoderm in the upper one-third of each enlarging nasal sac become thickened and developed into the olfactory epithelium[25]. On 17 day-old rabbit embryos, the VNO appeared as an arrangement of bilateral undifferentiated epithelial thickenings. That is in a disagreement with Vidic *et al.*[26], who stated that the VNO appears as 2 blinds epithelial-like tubes in the ventral aspect of the nasal septum at nasal vestibule at 16th prenatal day of the rat. On the other hand, current findings were in an accordance with De Lahunta and Noden[27] in domestic animals. The structure of the vomeronasal complex included the VNO, the underlying connective tissue, VNGs, nerves and blood supply. In the present study, it was found that the first sign of the developing VNO, appears by the 14th day of gestation, this age is considerably much later than the one described in hamster[8]. The olfactory nerve fibers also reach permanent features earlier than the vomeronasal fibers[28]. In this study, vomeronasal nerve fibers firstly appeared at the age of day 17 of gestation. Some evidences even have been suggested in utero-olfaction in hamsters[29], although no conclusive results are provided until birth when new borns show exceptional olfactory acuity[30]. The present results also showed that the development of the VNO in the rabbits tended to progress rapidly in the latter half of the gestation period. The laminar organization in VNO was established during the early postnatal stages. On the embryonic day 16 (E16) of the rat, the vomeronasal axons reached into the dorsocaudal region of the olfactory bulb (OB) and the underlying cells aggregated in the primordial VNO. On E18 of the rat, the laminar organization of VNO was detected. Between E20 and postnatal day 1 (P1), rat extremely developed and each cellular layer was distinguished. In goat VNO of fetal day 48 (F48) and F64, the layer structure could not be distinguished[12]. On F88, the layer structure was crudely formed. These morphological observations on F88 were similar to those on the E18 rat. Immediately before birth (F125), the layer structure was distinguished, which was similar to that observed in the adult goat[12]. Goat VNO

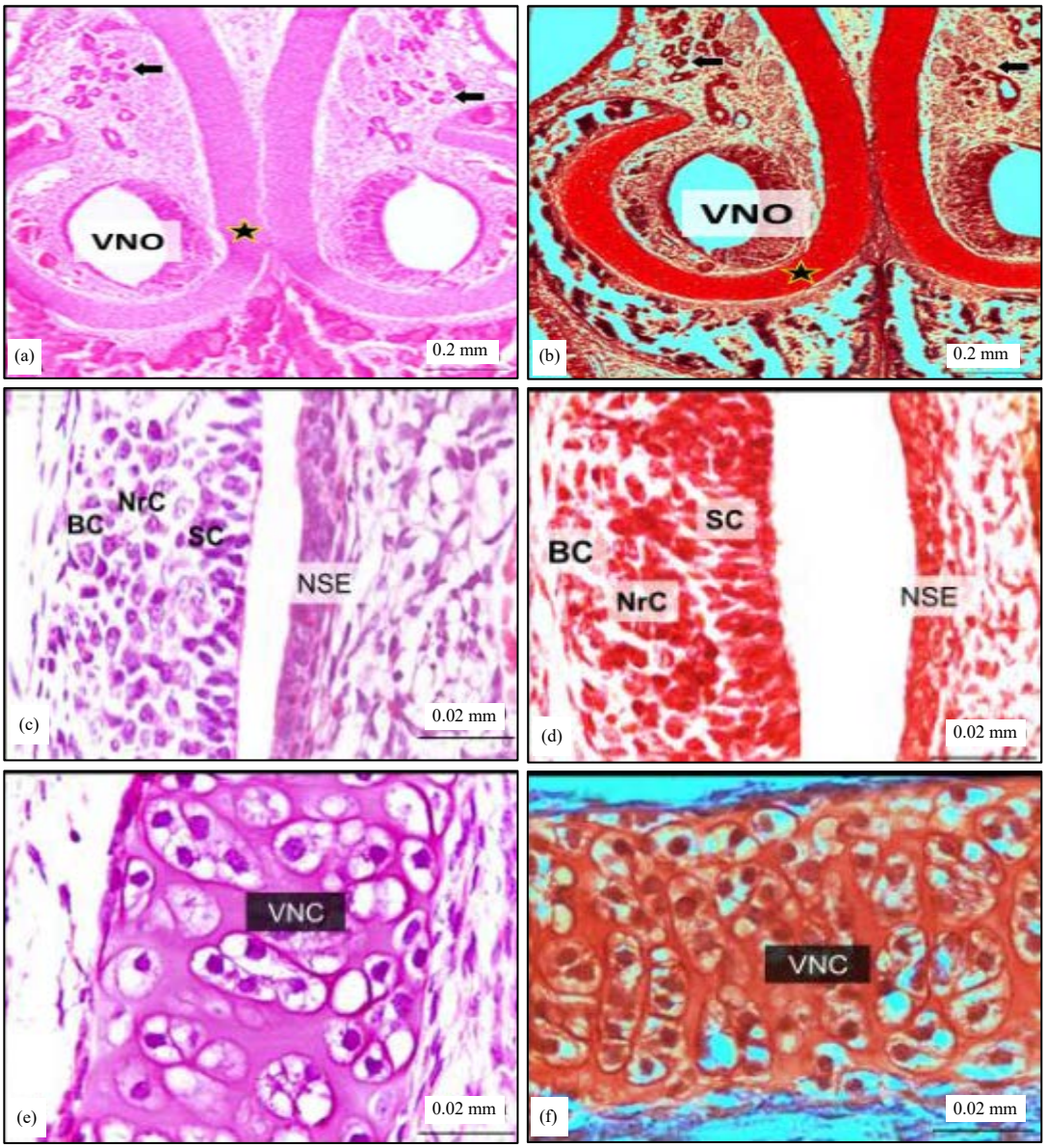

Fig. 7(a-f): Paraffin sections of the VNO from 30 days-old-rabbit-embryos, (a, b) Histological structure of the VNO stained with Hx and E and Safranin-O, (c, d) A higher magnification stained with Hx and E and Safranin-O and (e, f) Vomeronasal cartilage of the organ (VNC) stained with Hx and E and Safranin-O

Stars: VNO with central lumen and surrounded incompletely with J-shaped vomeronasal cartilage, Arrows: Numerous and mature vomeronasal glands, BC: Basal cells, NrC: Neuroreceptor, SC: Supporting cells, NSE: Non-sensory epithelium

development drastically progressed between F125 and P1 as well as between E23 and the P1 rabbit. In the goat, the pregnancy period about 150 days[31], considerably longer than that (30 days) of the rabbits and the growth of the embryo or fetus is comparatively moderate in the first half of pregnancy period and remarkable in the latter half. The morphology of the vomeronasal system of the sheep from SE to OB is essentially the same in the 14 weeks before birth as in the adult and accordingly appears to be just as capable of supporting function as the adult system[11]. In the present study VNC cells firstly were detected at 14 days of gestation in an immature state, while VNG was seen firstly on the day 23 of gestation. The VNC and VNG also differentiate 2-4 days earlier in the golden hamster than the rat. These data are in good agreement with their gestation period[7].

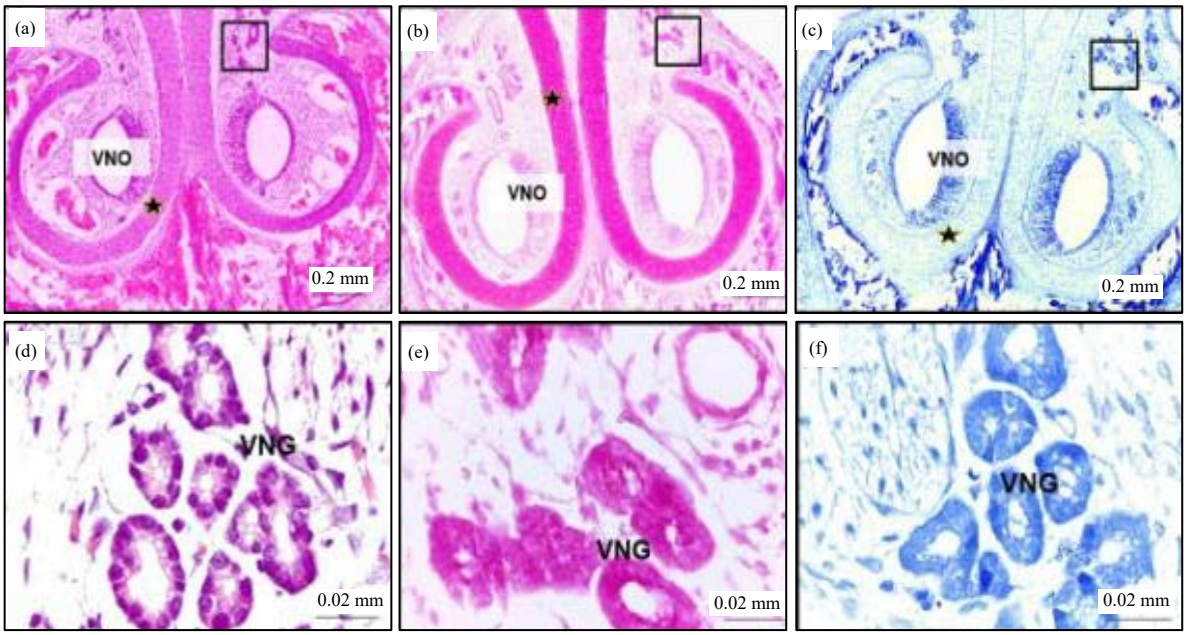

Fig. 8(a-f): Paraffin sections of the VNO from 30 days-old-rabbit-embryos, (a-c) Histological structure of the VNO stained with Hx and E, PAS and AB and (d-f) High magnification of the frame in (a-c)

Stars: VNO is surrounded incompletely with J-shape vomeronasal cartilage, conspicuous compound acinar vomeronasal glands (VNG) with well maturated nuclei

CONCLUSION

In conclusion, the current study reported the histological developmental stages of the VNO in prenatal rabbits. Further studies are required to cover more developmental stages not covered in the current study. Also, molecular biological studies should be undertaken to understand the gene expression changes associated with the morphological development of VNO.

ACKNOWLEDGMENT

The current research was funded by a grant from the South Valley University, Egypt.

SIGNIFICANCE STATEMENTS

This study discovered the histological changes of VNO in the rabbit embryos. That can be beneficial for understanding the development of the VNO in the rabbit. This study will help the researcher to uncover the physiological role of the VNO in human. Thus, a new theory on this VNO developmental physiology and possibly other combinations, may be arrived at.

REFERENCES

1. Keller, M., M.J. Baum, O. Brock, P.A. Brennan and J. Bakker, 2009. The main and the accessory olfactory systems interact in the control of mate recognition and sexual behavior. Behav. Brain Res., 200: 268-276.
2. Abbasi, M., 2007. The vomeronasal organ in buffalo. Ital. J. Anim. Sci., 6: 991-994.
3. Keverne, E.B., 1999. The vomeronasal organ. Science, 286: 716-720.
4. Charra, R., F. Datiche, V. Gigot, B. Schaal and G. Coureaud, 2013. Pheromone-induced odor learning modifies Fos expression in the newborn rabbit brain. Behav. Brain Res., 237: 129-140.
5. Estes, R.D., 1972. The role of the vomeronasal organ in mammalian reproduction. Mammalia, 36: 315-341.
6. Vaccarezza, O.L., L.N. Sepich and J.H. Tramezzani, 1981. The vomeronasal organ of the rat. J. Anat., 132: 167-185.
7. Garrosa, M., M.J. Gayoso and F.J. Esteban, 1998. Prenatal development of the mammalian vomeronasal organ. Microsc. Res. Tech., 41: 456-470.
8. Taniguchi, K. and K. Mochizuki, 1982. Comparative developmental studies on the fine structure of the vomeronasal sensory and the olfactory epithelia in the golden hamster. Jpn. J. Vet. Sci., 44: 881-890.

9. Andrea, D., 1998. Prenatal differentiation of mouse vomeronasal neurones. Eur. J. Neurosci., 10: 392-396.
10. Sherwood, R.J., J.C. McLachlan, J.F. Aiton and J. Scarborough, 1999. The vomeronasal organ in the human embryo, studied by means of three-dimensional computer reconstruction. J. Anat., 195: 413-418.
11. Salazar, I., M. Lombardero, N. Aleman and P.S. Quinteiro, 2003. Development of the vomeronasal receptor epithelium and the accessory olfactory bulb in sheep. Microsc. Res. Tech., 61: 438-447.
12. Takigami, S., Y. Wakabayashi, S. Ohsako, S. Ohkura and H. Okamura *et al*., 2004. Fetal development of vomeronasal system in the goat. Dev. Brain Res., 149: 113-120.
13. Smith, T.D. and K.P. Bhatnagar, 2000. The human vomeronasal organ. Part II: prenatal development. J. Anat., 197: 421-436.
14. Ibrahim, D., F. Abdel-Maksoud, K. Taniguchi, Y. Yamamoto, K. Taniguchi and N. Nakamuta, 2015. Immunohistochemical studies for the neuronal elements in the vomeronasal organ of the one-humped camel. J. Vet. Med. Sci., 77: 241-245.
15. Nawar, S.M., M.A. El Ayat and I.S. Ibrahim, 1975. Some anatomical and histological studies on the arterial supply of the nasal cavity of the buffalo in Egypt (*Bos bubalis* L.). Anatomischer Anzeiger, 138: 203-221.
16. Halpern, M., 1987. The organization and function of the vomeronasal system. Annu. Rev. Neurosci., 10: 325-362.
17. Villamayor, P.R., J.M. Cifuentes, P. Fdz.-de-Troconiz and P. Sanchez-Quinteiro, 2018. Morphological and immunohistochemical study of the rabbit vomeronasal organ. J. Anat., 233: 814-827.
18. Schneider, N.Y., F. Datiche and G. Coureaud, 2018. Brain anatomy of the 4-day-old European rabbit. J. Anat., 232: 747-767.
19. Dawley, E.M., 1998. Species, sex and seasonal differences in VNO size. Microsc. Res. Tech., 41: 506-518.
20. Brennan, P.A., 2010. Pheromones and Mammalian Behavior. In: The Neurobiology of Olfaction, Menini, A. (Ed.). Chapter 6, CRC Press/Taylor and Francis, Boca Raton, FL., USA., ISBN-13: 9780429141867, pp: 157-180.
21. Dulac, C. and R. Axel, 1995. A novel family of genes encoding putative pheromone receptors in mammals. Cell, 83: 195-206.
22. Keverne, E.B., 2002. Mammalian pheromones: From genes to behaviour. Curr. Biol., 12: R807-R809.
23. Brennan, P.A. and E.B. Keverne, 2001. Something in the air? New insights into mammalian pheromones. Curr. Biol., 14: R81-R89.
24. Cuschieri, A. and L.H. Bannister, 1975. The development of the olfactory mucosa in the mouse: Light microscopy. J. Anat., 119: 277-286.
25. Taniguchi, K., K. Taniguchi and K. Mochizuki, 1982. Developmental studies on the vomeronasal organ in the golden hamster. Jpn. J. Vet. Sci., 44: 709-716.
26. Vidic, B., H.G. Greditzer and W.J. Litchy, 1972. The structure and prenatal morphogenesis of the nasal septum in the rat. J. Morphol., 137: 131-147.
27. De Lahunta, A. and D.M. Noden, 2006. The Embryology of Domestic Animals: Developmental Mechanisms and Malformations. Samfundslitteratur, KVL-bogladen, København, Denmark.
28. Leonard, C.M., 1975. Developmental changes in olfactory bulb projections revealed by degeneration argyrophilia. J. Comp. Neurol., 162: 467-486.
29. Beauchamp, G.K., B.J. Cowart and H.J. Schmidt, 1991. Development of Chemosensory Sensitivity and Preference. In: Smell and Taste in Health and Disease, Getchell, T.V., R.L. Doty, M. Bartoshuk, J.B. Snow (Eds.). Raven Press, New York, USA., pp: 405-416.
30. Schaal, B., 1986. Presumed Olfactory Exchanges between Mother and Neonate in Humans. In: Ethology and Psychology, Le Camus, J. and J. Cosnier (Eds.). Privat Publisher, France, ISBN-13: 9782708987074, pp: 101-110.
31. Peaker, M., 1978. Gestation period and litter size in the goat. Br. Vet. J., 134: 379-383.