



Research Journal of
Parasitology

ISSN 1816-4943



Academic
Journals Inc.

www.academicjournals.com

Histopathology of the Infestation of Parasitic Isopod *Joryma tartoor* of the Host Fish *Parastromateus niger* *

¹S. Ravichandran, ¹T.T. Ajith Kumar, ²P. Ronold Ross and ²M. Muthulingam

¹Centre of Advanced Study in Marine Biology, Annamalai University,
Parangipettai-608 502, India

²Department of Zoology, Annamalai University, Annamalainagar-608 002, India

Abstract: The infestation of parasitic isopods in the fish *Parastromateus niger* was studied. Infested fish exhibited histopathological anomalies such as tissue reactions, primarily associated with the formation of granulomas consisted of macrophages and epithelioid cells, which are occasionally surrounded by a thin rim of fibroblasts. The infestations such as lipofibrosis, hyperaemia, haemorrhagic lesions and penetration of dactylus usually pressure atrophy often accompanied by the presence of parasites. Lesions had well developed granulomas that underlined in the muscle or overlying subcutaneous tissue, from these spread to underlying organs.

Key words: Isopod parasites, histopathology, lipofibrosis, hyperaemia, haemorrhagic lesions

INTRODUCTION

Parasitic isopods are among the dominant groups of crustacean ectoparasites of fish of which about 450 species are recorded as parasites of marine and freshwater fishes (Moller and Anders, 1986). They are protandric hermaphrodites and are blood suckers, living on the skin, in the gill chambers, or in the mouth of the fishes. The parasitic effects include growth retardation, emaciation and frequently death of those fish affected. Mortality losses are increased by weight losses resulting from the lowered conditions of the parasitised fish. Pathological conditions resulting from parasites and diseases assume high magnitude of epidemics under crowded and other unnatural conditions.

The effect of isopod parasite exhibited considerable variation (Ravichandran *et al.*, 1999; Ravichandran *et al.*, 2001; Grutter, 2003; Cuyas *et al.*, 2004). Histological changes in *Mugil cephalus* caused by *Stellantchasmus falcatus* was reported by Lee and Cheng (1979). Histopathological changes in *M. curema* in South America induced by *Phagicola longa* were studied by Torrealaba *et al.* (1986). Kabata (1985) and Ravichandran *et al.* (2000, 2004) described the pathogenicity of isopods and stated that the effect of the destruction of host tissue was mainly due to the pressure exerted by the Parasite's body.

At present, there is no accurate assessment of the infestation of isopod parasites in relation to their histopathological studies. Hence the present attempt was made to study the infestation and histopathology of infection by the isopod parasites in the fish *Parastromateus niger*.

MATERIALS AND METHODS

An extensive survey was undertaken along the Prangipettai coast. Fishes were collected from three major landing centers viz., Mudasalodai, Annankovil and Pudupettai and examined thoroughly for the presence of isopod parasites. The site of attachment, orientation of parasites on the host and number of parasites in each location were recorded. The parasites were then carefully removed from

Corresponding Author: S. Ravichandran, Centre of Advanced Study in Marine Biology, Annamalai University, Parangipettai-608 502, India Tel: + 91 4144 243223, 243533 Fax: + 91 4144 243555

*Originally Published in Research Journal of Parasitology, 2007

the hosts and transferred to 10% aqueous sodium bicarbonate solution to dissolve the mucus attached in the parasites. The parasites were then washed with tapwater and subsequently preserved in 10% neutral buffered formalin for identification.

To assess the nature of damage, tissues of infested and uninfested fishes were cut out in fresh condition and were fixed in neutral buffered formalin (10% NBF). Branchial, skin and gill tissue were considered for histopathological study. Fresh and recently preserved tissues were washed in tap water and dehydrated using alcohol series. The tissues were then cleaned in methylbenzoate and benzene and embedded in paraffin wax. The serial sections cut at 4 to 5 m thickness, were stained with Erlich's haemataxylin and Eosin

RESULTS

The histopathological symptoms owing to isopod parasites (*Joryma tartoor*) were categorized as gross lesions and histopathological anomalies (Fig. 1 and 2).

Tissue reactions, primarily associated with the formation of granulomas consisted of macrophages and epithelioid cells, which are occasionally surrounded by a thin rim of fibroblasts.




Fig. 1: Photograph showing the nature of thickening between the gill lamellae in *Parastromateus niger*

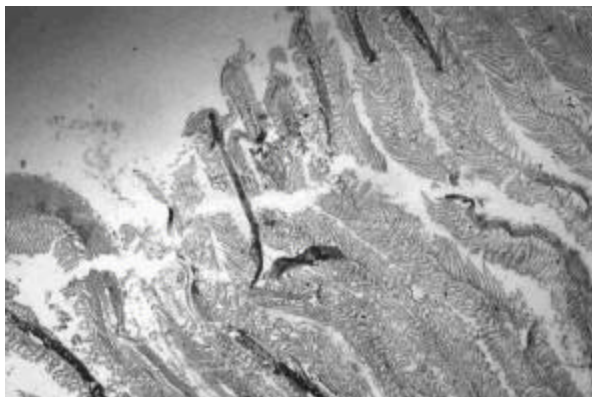


Fig. 2: Photograph showing the damage of gill raker and gill lamellae in *Parastromateus niger*



Fig. 3: Male and female *J. tartoor* in the branchial region of *Parastromateus niger*

Lesions were never encapsulated by developed granulomas that underlain in the lost epidermis. Lesions appeared to originate in the muscle or overlying subcutaneous tissue and from these they started spreading to the underlying organs.

The muscular growth has been identified as lipofibrous nodule that developed in response to the irritation caused by the isopod parasite *J. tartoor*. A flat nodule of tissue attached to the inner surface of the left operculum by slightly constricted base and formed about 1 to 2 mm thickness into the gill chamber. The base of the thickening consisted of a large normal fat tissue that is continuous with adjacent opercula flat. The surface of the thickening is solidly fibrous with a few small folds. In between, fibrous tissue and fat tissues intermingled. The surface epithelium that must have been present when the fish was alive was not in the section.

Nature of damage, observed in the gill remained the same, but the degree of damage varies, as the closely opposed gill arch observed a higher damage (Fig. 3). Terminal and middle regions of the gill lamellae bulged and the growth was stunted. Secondary gill lamellae uneven clubbed and showed fusion. Middle portion of some of the gill lamellae expanded to have some space or gap. Bifurcation was noticed at the tip of lamellae and the cartilaginous support of the gill arch was twisted.

DISCUSSION

Histological examination of the gill on which the isopod had settled, showed that the actions of the parasites meet with a characteristic reaction of the gill tissue, a reaction which is surprisingly uniform regardless of the stimulus applied; this reaction is the hypertrophy of epithelial and connective supporting tissues of the gill filament.

The lipofibrosis observed at the inner surface of the operculum was semihard and the surface was finely granulated and, showed invasive tendency. Accumulation of deeply stained acidophilic plasmacytes, marked separation of hyperplastic growth, peruse infiltration of lymphocytes and granulocytes are the characteristic features of the lipofibrosis noticed in the present study. Earlier workers indicate the presence of hyperplastic and hypertrophied reaction as function of infection due to isopod parasites (Eller, 1975; Romestand *et al.*, 1977; Rand, 1986).

Rand (1986) observed the presence of melanophores in the epidermis and dermal layers of fishes infested by *Nerocila acumunata*. In the present study, similar distinct melanophores were not accounted due to infestation of *J. tartoor*. Healthy tissue were absent at the pereopod attachment sites. Epidermis around pereopod attachment sites was hyperplastic, also, infested tissues appear to be deteriorated and is irregular in structure. The epithelial tissue contains intense hypertrophied cells. The effects may be due to the stress exerted by the parasite to the underlying tissues.

In the present study, apart from hyperplastic and hypertrophied reaction, the host tissue also showed lipofibrosis. This nodular formation of lipofibrosis at the branchial region might have initially formed as a small connective tissue thickening which subsequently due to constant contact of the parasite might have developed as a larger thickening as lipofibrosis. Hyperplasia in some situations represents an adaptation by the organism to protect the underlying tissues from any irritant (Meissner and Diamandopoulos, 1977). Hyperaemia was ascertained at the site of attachment of the parasite which in general had not been previously seen in young specimens. The parasite that attaches or settles on the host body, at first, causes localized inflammatory changes, but with time, they assume a different or diffused character. The changes always begin with hyperaemia in the angles between adjacent sides at the site of attachment and then move towards deeply situated area.

REFERENCES

- Cuyas, C., J.J. Castro, A.T. Santana Ortega and E. Carbonell, 2004. Insular stock identification of *Serranus atricauda* (Pisces: Serranidae) through the presence of *Ceratothoa steindachneri* (Isopoda: Cymothoidae) and *Pentacapsula cutanea* (Myoxoa: Pentacapsulidae) in the Canary Islands. *Sci. Mar. Barc.*, 68: 159-163.
- Eller, L.L., 1975. Gill Lesions in Freshwater Teleosts. In: the Pathology of Fishes. Ribelin, W.E. and G. Migaki (Eds.), The University of Wisconsin Press, pp: 305-330.
- Grutter, A.S., 2003. Feeding ecology of the fish ectoparasite *Gnathia* sp. (Crustacea: Isopoda) from the Great Barrier Reef and its implications for fish cleaning behaviour. *Marine Ecological Programe Series*, 259: 295-302.
- Kabata, Z., 1985. Parasites and Diseases of Fish Cultured in the Tropics. Isopoda, Taylor and Francis: London, pp: 265-271.
- Lee, F.O. and T.C. Cheng, 1979. The histochemistry of *Stellantchasmus falcatus* Onji and Nishio, 1915 (Trematoda: Heterophyidae) metacercarial Cyst in the mullet *Mugil ephalus* L. and histopathological alterations in the host. *J. Fish Biol.*, 2: 235-243.
- Meissner, W.A. and G.T.H. Deamandopoulos, 1977. Neoplasia. In: Pathology. Anderson, W.A.D. and J.M. Kissane (Eds.), St Louis: The C.V. Mosby Co., 1: 640-691.
- Moller, H. and K. Anders, 1986. Diseases and parasites of Marine fishes. Verlag Moller, FRG., pp: 385.
- Rand, T.G., 1986. The histopathology of infection of *Paranthias furcifer* (L.) (osteichthyes serranidae) by *Nerocila acuminata* (schioedte and Meinert) (Crustacea) Isopoda-Cymothoidae). *J. Fish Dis.*, 9: 143-146.
- Ravichandran, S., A.J.A. Ranjith Singh, N. Veerappan and T. Kannupandi, 1999. Effect of isopod parasite *Joryma brachysoma* on *Illisha melastoma* from Parangipettai coastal waters (southeast coast of India). *Ecol. Environ. Conserv.*, 5: 95-101.
- Ravichandran, S., P. Soundarapandian and T. Kannupandi, 2000. Infestation of isopod parasite *Epipenaeon ingens Nobili* parasitized on *Penaeus monodon* from Parangipettai coastal environment. *Adv. Biosci.*, 19: 73-78.
- Ravichandran, S., A.J.A. Ranjith Singh and N. Veerappan, 2001. Parasite induced vibriosis in *Chirocentrus dorab* off Parangipettai coastal waters. *Curr. Sci.*, 80: 101-102.
- Ravichandran, S. and T. Ramesh Kumar, 2004. Infestation of isopod parasite *Nerocila phaeopleura* on *Chirocentrus dorab*. *Proc., National Sem. on Marine Resources*. ST. Hindu College, Nagercoil, India, pp: 45-48.
- Romestand, B., M. Janicot and J.P. Trilles, 1977. Modifications tissulaires et reactions de defence chez quelques Teleosteens parasites par les Cymothoidae (Crustaces, Isopodes, Hemalophages). *Annales de parasitologie Humaine et Comparee*, 52: 171-180.
- Torrealaba, L., G. Conroy, D.A. Conroy and J.M. Torrealaba, 1986. Histological changes in Silver mullet, *Mugil curema* Val., 1836 infected with metacercaria of *Phagicola longa* (Trematoda: Heterophyidae) in South America. *Riv. Ital. Piscic. Ittiopatol.*, 21: 35-37.