



Research Journal of
Parasitology

ISSN 1816-4943



Academic
Journals Inc.

www.academicjournals.com

Chemoprophylaxis and Chemotherapeutic Effect of Flubendazole on *Echinococcus granulosus* Experimentally Infected Dogs

Amera F. Afifi and Nancy M. Harba

Department of Parasitology, Faculty of Medicine, Menoufiya University, Egypt

*Corresponding Author: Amara F. Afifi, Department of Parasitology, Faculty of Medicine, Menoufiya University, Egypt
Tel: 002 0100 2223913*

ABSTRACT

Dogs are pivoted in *Echinococcus granulosus* (*E. granulosus*) transmission to human that causes cystic echinococcosis. Uses of effective drugs as chemoprophylactic or chemotherapeutic provides a very practical and an important prevention strategy to control programs in endemic countries. The aim of the present study was to determine the effect of flubendazole (FLBZ) on *E. granulosus* infection in dogs as a chemoprophylactic and chemotherapeutic. FLBZ was given by a dose of 20 mg kg⁻¹ twice daily 35 days post infection for 3 consecutive days and was given by the same dose at time point of infection for 15 consecutive days. The results of the chemoprophylactic effect and chemotherapeutic effects showed significant reduction in the number of worms according to control group, also there was marked inhibition of maturation that gave 84.9% for FLBZ chemoprophylaxis and 100% as chemotherapeutic. SEM studies revealed different changes in the adults parasites surface.

Key words: *E. granulosus*, chemotherapeutic, chemoprophylactic, drugs, parasites

INTRODUCTION

Echinococcus granulosus is a small taeniid type tape worm. Carnivores such as dogs are usually definitive host, while intermediate hosts are typically herbivores such as sheep and cattle. Human acts as an accidental host because they are usually a dead end for the parasite infection cycle (Aslan *et al.*, 2011).

Cystic Echinococcosis (CE) caused by ingesting *E. granulosus* egg is widely distributed in both human and ungulates (Bruzinskaite *et al.*, 2009; Yang *et al.*, 2009; Hajjalilo *et al.*, 2012).

Although substantial effects have been made to control *E. granulosus* (Gemmell *et al.*, 2001), these have not always been successful. Vaccination can provide an adjunct to improved and integrated control. This area has advanced considerably in recent years with the development of an effective recombinant vaccine antigen from *E. granulosus* eggs that target infection in the intermediate host (Lightowers, 2002).

Dog immunization has received relatively little attention, yet dogs, as definitive hosts, are pivotal in transmission of *C. echinococcosis*. For example, monthly treatment of dogs with praziquantel resulted in significant reduction, in rates of *E. granulosus* infection in sheep (Zhang *et al.*, 1994). However, this high frequency of treatment has to be maintained for a considerable period, because dogs are quickly reinfected. In the early 1970s, some Benzimidazole (BZD) methyl carbamates were proved to be effective against *E. granulosus* and since then, many investigators have used Mebendazole (MBZ) and Albendazole (ABZ) for the treatment of human

hydatid disease (Teggi *et al.*, 1993). At present, three BZD methyl carbamates compounds, MBZ, ABZ and FLBZ have been used, MBZ was the first compound widely used. FLBZ is a broad-spectrum antihelminthic available for use in human and veterinary medicine against *C. echinococcosis* (Bekhti *et al.*, 1977; El-On, 2003).

The aim of this study is to determine the chemoprophylactic and chemotherapeutic effects of FLBZ against *E. granulosus* infected dogs as one of methods for control of hydatid diseases.

MATERIALS AND METHODS

This study was performed at Department of Parasitology, Faculty of Medicine, Menoufiya University in the Period from July 2010 to January 2012.

Parasite material: Hydatid cysts of *E. granulosus* were removed from lungs and liver of naturally infected cattle and sheep in slaughtered houses of Shebin El-Kom, Menoufiya Governorate, Egypt. The intact cysts were placed in an Ice Box and transported within 3 h to the Lab of Parasitology Department, Faculty of Medicine, Menoufiya University, Shebin El-Kom, Egypt.

Collection of hydatid fluid: Cysts were washed several times in sterile PBS (pH 7.2). Cyst surface was sterilized by 70% ethyl alcohol and their fertility was determined by the presence of free protoscolices (PSCs) in cyst fluid by microscopic examination of a wet round drop (Smyth, 1967).

Preparation of protoscolices: Hydatid fluid containing PSCs was evacuated completely into 15 mL falcon tubes without centrifugation and it was left to precipitate for an hour to obtain hydatid sand at room temperature. Protoscolices were maintained in a sterile preservative solution made of a mixture of Krebs-Ringer Solution (KRS) and hydatid cyst fluid (4:1) (Kadir *et al.*, 2004) for all experiments. This preservative solution does not contain an antibiotics or antifungal drugs.

The viability of protoscolices was determined prior to the experiments. A 0.01 mL solution of pooled protoscolices was transferred over a slide and mixed with 0.01 mL of 0.1% aqueous eosin stain, as a vital staining and was evaluated by low power microscopy after 5 minutes. Unstained protoscolices were considered as viable (Fig. 1) while stained ones were considered as non-viable (Fig. 2) (Smyth and Barrett, 1980). When the percentage of viable protoscolices in the sediment was 95% or more, they were considered to be appropriate for experiments. The percentage of viable protoscolices (viability rate) was determined by counting a minimum of 100 protoscolices (as a rational number of viable protoscolices to total protoscolices).

Experimental animal: All work with dogs was conducted following international guidelines on the use of animal for experimentation (recommendation of European Commission No. L358, ISSN 0378-6978). Dogs common breeds, between 6-12 months of age, were maintained under convenient conditions at the animal house of Pharmacology Department, Faculty of Medicine, Menoufiya University.

All animal underwent stool examination for sure that they are free from parasitic infection.

A total of 14 dogs were used in this study divided as follows:

Group I: Four dogs served infected non treated control group

Group II: Five dogs infected with *E. granulosus* PSCs and treated with 20 mg kg⁻¹ FLBZ of human dose 35 days post infection twice per day for 3 days (Chemotherapeutic group)

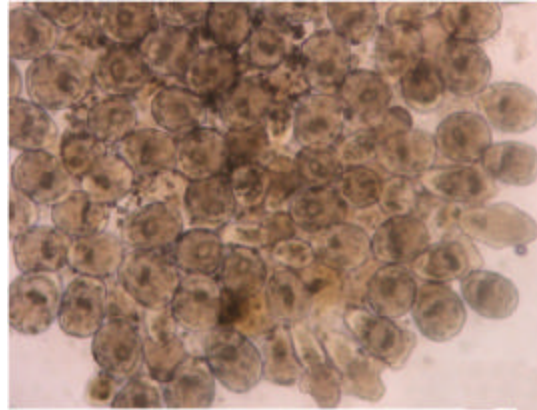


Fig. 1: Light microscopy for unstained PSCs (x400)

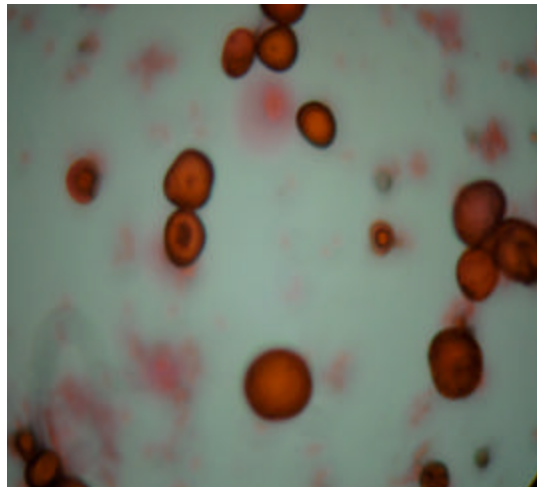


Fig. 2: Light microscopy for stained PSCs (x400)

Group III: Five dogs challenged and treated with FLBZ at the time point of infection by the previous dose for 15 consecutive days (chemoprophylactic group) (Ceballos *et al.*, 2010)

Animal dose of FLBZ was calculated according to Paget and Barnes (1964). All dogs were infected orally with 480,000 (PSCs) previously prepared. After forty days of infection, every 48 h dogs faeces were examined for adult worms while eggs were detected on the anal area using cellophane tape strips and microscopic examination (Heath and Lawrence, 1976).

Dogs were euthanized and necropsied 45-46 days after infection. The small intestine was freed immediately from the mesentery and opened longitudinally. The portion containing *E. granulosis* worms was cut into 20 cm length, which were incubated in PBS at 37°C. Most worms were released naturally within 1 h and the remainder was scraped carefully from the intestine using a microscope slide. The worms were washed twice with worm PBS and then fixed in 70% (Vol/Vol) ethanol before counting (eel worms) and microscopic examination of 1-2% of adult worms where in some groups all worms examined (Eckert *et al.*, 2001).

Scanning electron microscope (SEM): Topographic studies with SEM were performed. Samples of worms from each dog of each group were fixed with 30% glutaraldehyde in sodium cacodylate buffer for 72 h at 4°C.

Then, several washes in cacodylate buffer were made for SEM analysis, the specimens were dehydrated by sequential incubation in increasing concentration of ethanol (50-100%) and were finally immersed in hexamethyldizilazane for 5 min, 1 h and then overnight. They were then sputter coated with gold (100-Å Thickness) and inspected on a JEOLJSM-6460 LV scanning electron microscope operating at 15 kV, in Electron Microscopy Unit, Faculty of Medicine, Tanta University.

Statistical analysis: The collected revised and verified data were edited on personal computer and analyzed by program (SPSS; Statistical Package for Social science) version 15.0 for windows. All values were expressed as Mean±SD. Means were compared by student t-test, with level of significance of $p < 0.05$. t-test was used for comparison between two groups of normally distributed variable where Mann-Whitney test was used for comparison between two groups of non normally distributed variables. Kruskal-Wallis test is used for comparing more than two samples that are independent, or not related.

RESULTS

In this study, it revealed that FLBZ used as chemoprophylaxis and chemotherapeutic showed significant reduction in the number of worms according to control group, also there was marked inhibition of maturation of adult worms that showed by SEM examination.

Challenge infection in control group resulted in 58% of PSCs developing into adult worms (Table 1). In contrast, FLBZ treatment induced a significant suppression of growth and egg production. The burden of worms on the FLBZ chemoprophylactic group (GIII) was significantly lower than that in the control group ($p < 0.05$) (Table 1). Only 3.21% of worms were gravid (egg present) with 2 of 5 dogs having no gravid proglottids, whereas 21.26% of worms were gravid in the control group.

Dogs that are given FLBZ as therapeutic drug after infection (Group II) had also a significant reduction in the number of worms developing in the egg-producing stage ($p < 0.05$) were all worms in this group were without gravid segment. The inhibition of maturation (% of gravid worms in the control group-% of gravid worm in the treated group)/% of gravid worms in control group) was 84.9 and 100% for FLBZ chemoprophylaxis and FLBZ-chemotherapeutic, respectively.

Also, the size of randomly chosen worms per experimental group was measured and recorded the percentage of undeveloped (<5 mm) (Fig. 3) versus developed (≥ 5 mm) (Fig. 4). In the chemoprophylactic dogs, 48.3% of worms were small and in chemotherapeutic 97.5% of worms were small, whereas in infected control dogs, small worms represented only 28.25% and normal worms represented 72.75% of the chosen worms either gravid (Fig. 5) and non gravid (Fig. 6).

SEM studies permitted us to examine the effects induced by FLBZ, demonstrating that ultrastructure changes were induced in each of the two ways FLBZ used in this study according to the control group (Fig. 7-9).

Table 1: No. of worms extracted from different groups

Groups	Worm (n = 4)			No. of examined worm (1-2%)			<5 mm			=5 mm			Gravid segment			
	No.	Mean±SD	No.	Mean±SD	No.	Mean±SD	No.	Mean±SD	No.	Mean±SD	No.	Mean±SD	No.	Mean±SD	No.	Mean±SD
Control (N = 4)																
C1	295000	278771.5±3183.3	2950	2787.5±317.9	1004	787.5±522.45	1430	1407.5±398.08	516	592.5±260.33						
C2	308310		3083		339		1770		974							
C3	276500		2765		1425		848		492							
C4	235275		2352		382		1582		388							
Flubendazole chemopropylactic (F.P.) (N = 5)																
F.P.1	60580	23454.22±4738.85	605	280.8±198.0	289	135.6±85.9	316	136.2±121.08	0	9±12.2						
F.P.2	7520		150		89		57		4							
F.P.3	16710		167		98		69		0							
F.P.4	33800		338		103		206		29							
F.P.5	9640		144		99		33		12							
Flubendazole chemotherapeutic (F.T.) (N = 5)																
F.T.1	102	32.4±46.78	102	32.4±46.78	98	31.6±45.31	4	0.8±1.79	0	0.00						
F.T.2	0		0		0		0		0							
F.T.3	0		0		0		0		0							
F.T.4	60		60		60		0		0							
F.T.5	0		0		0		0		0							
K-test	11.67		5.96		19.89		11.83									
p-value	p2<0.05		p2<0.05		p2<0.05		p2<0.05		p2<0.05							
	p3<0.05		p3<0.05		p3<0.05		p3<0.05		p3<0.05							

Mann Whitney test, K-test: Kruskal Wallis test, P1: Between control group and F. P. group, P2: Between control group and F. T. group, P3: Between F.P. group and F. T. group

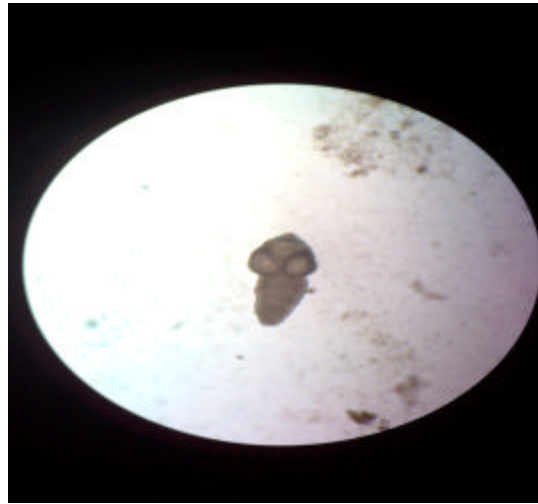


Fig. 3: Light microscopy for undeveloped *E. granulosus* adult (<5 mm) (x100)

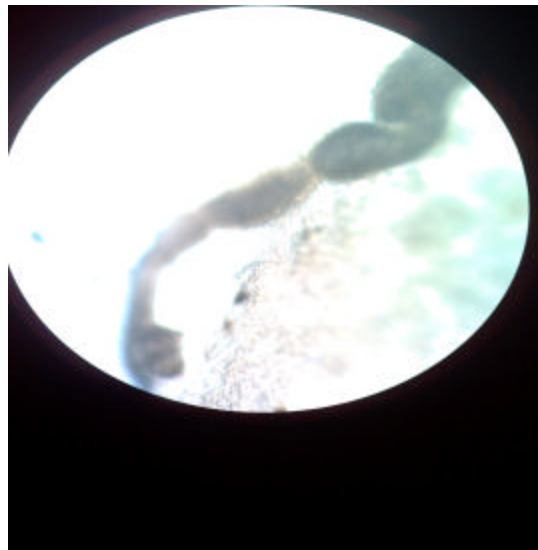


Fig. 4: Light microscopy for developed non gravid *E. granulosus* adult (>5 mm) (x100)

SEM examination revealed different changes in the adult parasite surface. The changes vary from complete loss of normal architecture of suckers and complete destruction of the soma region with absence of the hooks (Fig. 10), loss and altered of normal tegumental morphology (Fig. 11), complete closures and destructions of sucker and microtriches with multiple blebs (Fig. 12) and multiple areas of teguments loss and complete destruction and disappearance of the morphology of scolex and segments, also there are complete loss of microtriches (Fig. 13). These changes revealed as a result of using FLBZ as chemotherapeutic for *E. granulosus* infection in dogs.

On the other hand, the prominent SEM changes occurred with FLBZ as chemoprophylaxis was the immaturity of the adults produced, most adults produced were less than 5 mm in length (Fig. 14). Also, there were changes similar that produced by FLBZ as chemotherapeutic varies as

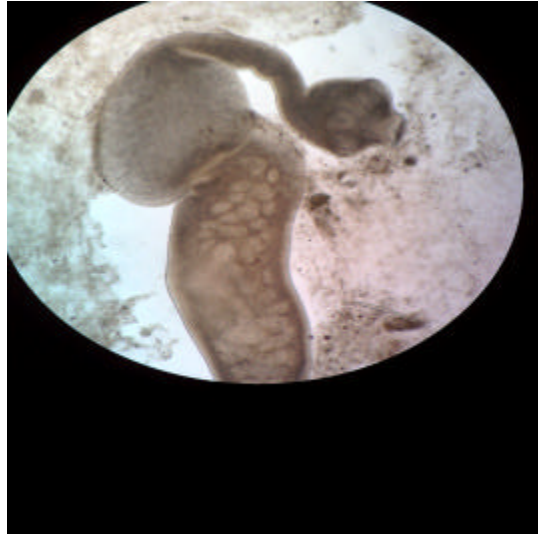


Fig. 5: Light microscopy for developed gravid *E. granulosus* adult (≥ 5 mm) (x100)

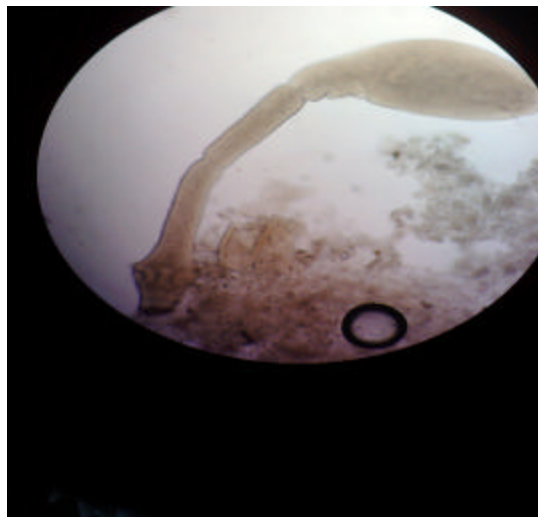


Fig. 6: Light microscopy for developed non gravid *E. granulosus* adult (≥ 5 mm) (x100)

following, loss of hooks and rostellum microtriches, contraction of the soma region and formation of multiple blebs in the suckers (Fig. 15), loss of normal architecture of the scolex and microtriches with multiple blebs and contraction of stoma (Fig. 16), destruction of suckers with loss of microtriches and still hooks present with altered soma and rostellum (Fig. 17, 18) and large area of tegument was lost (Fig. 19).

DISCUSSION

Hydatid disease remains an important risk to human health and has a large economic impact, so find a good way for control is important.




Fig. 7: SEM examination of *E. granulosus* adult extracted from group I showing normal soma (ST) region, normal suckers (S) with its microtriches, rostellum (R) and hooks (H)




Fig. 8: SEM examination of *E. granulosus* adult extracted from group I showing normal tegument of the segments

We have demonstrated to our knowledge for the first time the parasitological effect of FLBZ on *E. granulosus* in dogs. In this study, FLBZ evaluated as chemotherapy for exact infection and also as chemoprophylactic against *E. granulosus* infection at the beginning of the infection.

In this study, FLBZ treatment induced a high significant suppression of worm growth and egg production. So, there is high reduction in the number of worm and also in the number of worm developing to egg-producing stage by percentage of (100%).

This effect of FLBZ in this study are consistent with those reported by Elissondo *et al.* (2005) where they use FLBZ at dose of 10.5 and 1 µg mL⁻¹. in vitro provoked a protoscolicidal effect, reducing the vitality of protoscolices to 35.6±0.7% after 18 days of incubation. Maximal protoscolicidal effect of FBZ was observed after 25 days and 30 days of incubation when the percentage of vital protoscolices was 13.9±5.9 and 100%.

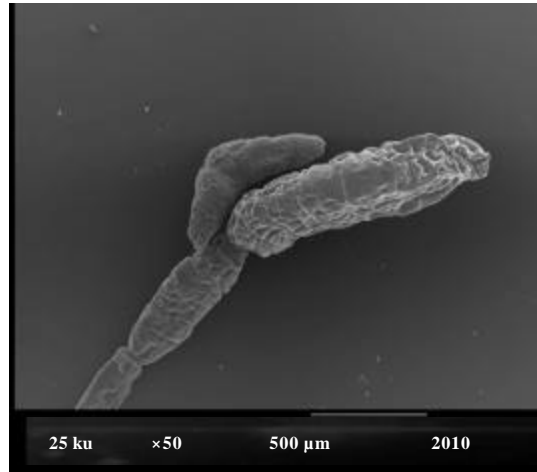


Fig. 9: SEM examination of *E. granulosus* adult extracted from group I showing normal tegument with presence of gravid segments




Fig. 10: SEM examination of *E. granulosus* adult extracted from group II mice showing complete loss of normal architecture of suckers and complete destruction of the soma region with absence of the hooks

Also, the result of this study for FLBZ as chemotherapeutic against *E. granulosus* nearly agreed with its effect against *Ascaridia galli*, *Heterakis gallinarum* and intestinal *Capillaria* spp. in chicken where FLBZ achieved an overall efficacy of 99.4% for the three Parasites sp. (Squires *et al.*, 2012). Chung *et al.* (2001) found that FLBZ causes 99.4% reduction in worm load when used experimentally by a dose of 20 mg kg⁻¹. in *Trichinella spiralis* infected mice for 5 consecutive days. Similar results revealed by Nessim *et al.* (2000) by using FLBZ in treatment of *S. mansoni* experimentally infected mice 25 days after infection where it gave significant reduction in the recovery of adult *S. mansoni* (79.5%).

The results of FLBZ as chemoprophylactic also are agreed with Ceballos *et al.* (2010) when they used FLBZ as chemoprophylactic against infection with hydatidosis in experimentally infected mice




Fig. 11: SEM examination of *E. granulosus* adult extracted from group II showing completely altered and loss of tegumental and scolex morphology




Fig. 12: SEM examination of *E. granulosus* adult extracted from group II showing complete closures and destructions of sucker and microtriches with multiple blebs

where they found that there were a significant reduction in cyst weight compare to the cysts recovered from untreated control animals. They reported that FLBZ offers a great potential to become a drug of choice as the preventive treatment of cystic echinococcosis.

Nessim *et al.* (2000) reported that when FLBZ given for mice at a dose of 100 mg kg⁻¹ for single oral dose 4 and 24 h before infection with *S. mansoni* gave significant reduction in worm count comparing to control ones.

According to using vaccines against *E. granulosus*, the results of vaccination were nearly to the results of this study in using FLBZ as chemoprophylaxis ,where Petavy *et al.* (2008) reported that an oral recombinant vaccine in dogs gave results of the trial in Morocco showed a 79% reduction in the number of *E. granulosus* in vaccinated dogs compared with non-vaccinated, infected controls,

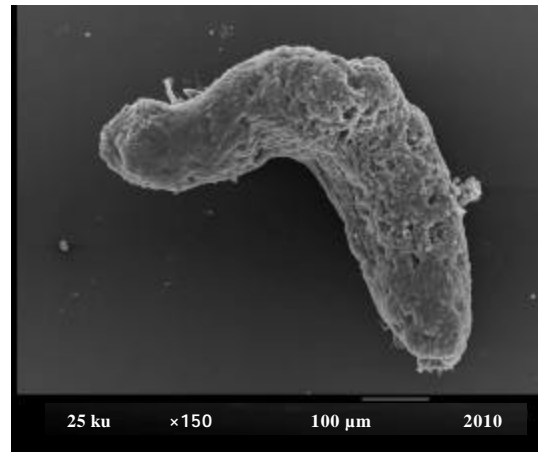


Fig. 13: SEM examination of *E. granulosus* adult extracted from group II showing multiple area of tegument loss and complete loss of morphology of scolex and segments

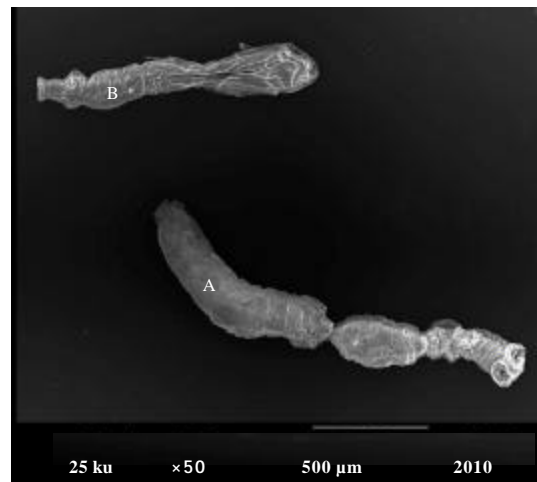


Fig. 14: SEM examination of *E. granulosus* adult extracted from group III showing two worms one of them is longer than 5 mm (A) and less than 5 mm (B)

also the same results reported in Tunisia showed 74% reduction. In addition, they measured the size of worms where they found in vaccinated dogs, 40% of the worms were small whereas in infected control only 15% small worm was found.

Ultrastructural alterations signs observed in this study revealed marked destruction and loss of integrity of the tegument of the adult worm. Also, formation of blebs on the tegument, rostellar disorganization, loss of hooks and destruction of microtriches when using FLBZ as chemotherapeutic while these damages decreased in chemoprophylactic effect, these results agreed with Elissondo *et al.* (2006) when they used FLBZ *in vitro* on protoscolices of *E. granulosus* where they demonstrated complete loss of morphology at 18 days p.i. at a dose of 5 and 1 μg mL⁻¹, some protoscolices had lost their hooks and tegumental sucker region appeared altered. The same region was contracted with tegument markedly altered.




Fig. 15: SEM examination of *E. granulosus* adult extracted from group III showing loss of hooks and rostellum microtriches, contraction of the soma region and formation of multiple blebs in the suckers




Fig. 16: SEM examination of *E. granulosus* adult extracted from group III showing loss of normal architecture of the scolex and microtriches with multiple blebs and contraction of stoma

Perez-Serrano *et al.* (1994) assumed that loss of hooks and formation of blebs are "stress responses" brought by any harmful condition. Also, they reported that alternation of tegumental microtriches probably interferes with scolex nutrition since microtriches are directly associated with the nutrients absorption.

Also, Elissondo *et al.* (2007) reported that in vitro results of the FLBZ treatment of hydatid Murine cysts were at 15 days P.I., the germinal membrane of microcysts was extensively distorted upon drug treatment with 5 and 1 $\mu\text{g mL}^{-1}$, at 25 days P.I., the germinal layer was completely altered with the presence of lipid droplets and vacuoles.




Fig. 17: SEM examination of *E. granulosus* adult extracted from group III showing destruction of suckers with loss of microtriches and still hooks present with altered soma




Fig. 18: SEM examination of *E. granulosus* adult extracted from group III showing destruction of suckers with loss of microtriches and still hooks present with altered rostellum

Ceballos *et al.* (2010) revealed marked ultrastructural morphological changes when using FLBZ as chemoprophylaxis in cystic echinococcosis.

The results of this study nearly similar to those reported by Conder *et al.* (1981) when using Praziquantel in vitro on *E. granulosus* adults where they found progressive breakdown of the tegument and morphologic distortion.




Fig. 19: SEM examination of *E. granulosus* adult extracted from group III showing large area of tegument loss (TS), loss of hooks, almost closed suckers and loss of morphology of the scolex and its microtriches

Ultrastructural studies of Elissondo *et al.* (2009) revealed that the germinal layer of the treated cyst of *E. granulosus* with FLBZ in vitro study at dose of 1 and 10 $\mu\text{g mL}^{-1}$ lost the multicellular structure feature and underwent considerable degenerative changes.

CONCLUSION

We concluded from this study that treatment of the dog host against *E. granulosus* is feasible when using FLBZ before and during infection, because the egg stage is crucial in the echinococcal life cycle, successful suppression of egg development by treatment with FLBZ would halt transmission to intermediate hosts, thereby effecting long-term control.

REFERENCES

- Aslan, M., P. Yuksel, E. Polat, H. Cakan and S. Ergin *et al.*, 2011. The diagnostic value of Western blot method in patients with cystic echinococcosis. *New Microbiol.*, 34: 173-177.
- Bekhti, A., J.P. Schaaps, M. Capron, J.P. Dessaint, F. Santoro and A. Capron, 1977. Treatment of hepatic hydatid disease with mebedazole: Preliminary results in four cases. *Br. Med. J.*, 2: 1047-1051.
- Bruzinskaite, R., M. Sarkunas, P.R. Torgerson, A. Mathis and P. Deplazes, 2009. Echinococcosis in pigs and intestinal infection with *Echinococcus* spp. in dogs in southwestern Lithuania. *Vet. Parasitol.*, 160: 237-241.
- Ceballos, L., C. Elissondo, S.S. Bruni, A. Confalonieri, G. Denegri, L. Alvarez and C. Lanusse, 2010. Chemoprophylactic activity of flubendazole in cystic echinococcosis. *Chemotherapy*, 56: 386-392.
- Chung, M.S., K.H. Joo, F.S. Quan, H.S. Kwon and S.W. Cho, 2001. Efficacy of flubendazole and albendazole against *Trichinella spiralis* in mice. *Parasite*, 8: S195-S198.
- Conder, G.A., A.A. Marchiondo and F.L. Andersen, 1981. Effect of praziquantel on adult *Echinococcus granulosus* in vitro: Scanning electron microscopy. *Parasitol. Res.*, 66: 191-199.

- Eckert, J., P. Deplazes, P.S. Craig, M.A. Gemmell, B. Gottstein *et al.*, 2001. Echinococcosis in Animals: Clinical Aspects, Diagnosis and Treatment. In: WHO/OIE Manual on Echinococcosis in Humans and Animals: A Public Health Problem of Global Concern, Eckert, J., M.A. Gemmell, F.X. Meslin and Z.S. Pawlowski (Eds.). World Organisation for Animal Health, Paris, pp: 72-99.
- El-On, J., 2003. Benzimidazole treatment of cystic echinococcosis. *Acta Trop.*, 85: 243-252.
- Elissondo, M.C., M.C. Dopchiz, F. Zanini, H. Perez, M. Brasesco and G. Denegri, 2005. Strain characterization of *Echinococcus granulosus* protoscoleces of cattle origin using the *In vitro* vesicular development. *Parasite*, 12: 159-164.
- Elissondo, M., M. Dopchiz, L. Ceballos, L. Alvarez, S.S. Bruni, C. Lanusse and G. Denegri, 2006. *In vitro* effects of flubendazole on *Echinococcus granulosus* protoscoleces. *Parasitol. Res.*, 98: 317-323.
- Elissondo, M., L. Ceballos, M. Dopchiz, V. Andresiuk, L. Alvarez, S.S. Bruni, C. Lanusse and G. Denegri, 2007. *In vitro* and *In vivo* effects of flubendazole on *Echinococcus granulosus* metacestodes. *Parasitol. Res.*, 100: 1003-1009.
- Elissondo, M.C., L. Ceballos, L. Alvarez, S.S. Bruni, C. Lanusse and G. Denegri, 2009. Flubendazole and ivermectin in vitro combination therapy produces a marked effect on *Echinococcus granulosus* protoscoleces and metacestodes. *Parasitol. Res.*, 105: 835-842.
- Gemmell, M.A., M.G. Roberts, T.C. Beard, S. Campano-Diaz, J.R. Lawson and J.M. Nonnemaker, 2001. Control of Echinococcosis. In: WHO/OIE Manual on Echinococcosis in Humans and Animals: A Public Health Problem of Global Concern, Eckert, J., M.A. Gemmell, F.X. Meslin and Z.S. Pawlowski (Eds.). World Organisation for Animal Health and World Health Organisation, Paris, France.
- Hajjalilo, E., M.F. Harandi, M. Sharbatkhori, H. Mirhendi and S. Rostami, 2012. Genetic characterization of *Echinococcus granulosus* in camels, cattle and sheep from the south-east of Iran indicates the presence of the G3 genotype. *J. Helminthol.*, 86: 263-270.
- Heath, D.D. and S.B. Lawrence, 1976. *Echinococcus granulosus*: Development *In vitro* from oncosphere to immature hydatid cyst. *Parasitology*, 73: 417-423.
- Kadir, M., S. Rasheed and S. Tahir, 2004. Comparison between the efficacy of some chemical drugs and medical herbs on hydatid cysts. Proceedings of the 11th Scientific Congress, Faculty of Veterinary Medicine, Assiut University, Egypt, December 13-15, 2004, Assiut Egypt, pp: 372-382.
- Lightowlers, M.W., 2002. Vaccination against hydatid disease. *Dev. Biol.*, 110: 81-87.
- Nessim, N.G., S.I. Hassan, S. William and H. El-Baz, 2000. Effect of the broad spectrum anthelmintic drug flubendazole upon *Schistosoma mansoni* experimentally infected mice. *Arzneimittelforschung*, 50: 1129-1133.
- Paget, G.E. and J.M. Barnes, 1964. Evaluation of Drug Activities. In: Pharmacometries, Laurence, D.R. and A.L. Backarach (Eds.). 1st Edn. Academic Press, London, pp: 253.
- Perez-Serrano, J., N. Casado, Guillermo, Denegri and F. Rodriguez-Caabeiro, 1994. The effects of albendazole and albendazole sulphoxide combination-therapy on *Echinococcus granulosus* *In vitro*. *Int. J. Parasitol.*, 24: 219-224.
- Petavy, A.F., C. Hormaeche, S. Lahmar, H. Ouhelli and A. Chabalgoity *et al.*, 2008. An oral recombinant vaccine in dogs against *Echinococcus granulosus*, the causative agent of human hydatid disease: A pilot study. *PloS Neglected Trop. Dis.*, Vol. 2.

- Smyth, J.D., 1967. Studies on tapeworm physiology. XI. *In vitro* cultivation of *Echinococcus granulosus* from the protoscolex to the strobilate stage. *Parasitology*, 57: 111-133.
- Smyth, J.D. and N.J. Barrett, 1980. Procedures for testing the viability of human hydatid cysts following surgical removal, especially after chemotherapy. *Trans. R. Soc. Trop. Med. Hyg.*, 74: 649-652.
- Squires, S., M. Fisher, O. Gladstone, S. Rogerson and P. Martin *et al.*, 2012. Comparative efficacy of flubendazole and a commercially available herbal wormer against natural infections of *Ascaridia galli*, *Heterakis gallinarum* and intestinal *Capillaria* spp. in chickens. *Vet. Parasitol.*, 185: 352-354.
- Teggi, A., G.M. Lastilla and F. de Rosa, 1993. Therapy of human hydatid disease with mebendazole and albendazole. *Antimicrob. Agents Chemother.*, 37: 1679-1684.
- Yang, Y.R., D.P. McManus, Y. Huang and D.D. Heath, 2009. *Echinococcus granulosus* infection and options for control of cystic echinococcosis in tibetan communities of Western Sichuan province, China. *PLOS Negl. Trop. Dis.*, Vol. 3, No. 4.
- Zhang, W.B., Z.Z. Zhang, H. Alili and P.S. Chi, 1994. Control program of hydatid disease in Hutubi county, Xinjian, China. *Endemic Dis. Bull.*, 9: 70-71.