



Research Journal of
Parasitology

ISSN 1816-4943



Academic
Journals Inc.

www.academicjournals.com

Myotonia and Colic Associated with the Spinose Ear Tick, *Otobius megnini*, in a Horse in Northern Mexico

¹J.J. Zarate-Ramos, ²A.M. Nevárez-Garza, ¹D.E. Zamora-Ávila and ²L.E. Rodríguez-Tovar

¹Cuerpo Académico de Epidemiología,

²Cuerpo Académico de Patobiología, Facultad de Medicina Veterinaria y Zootecnia, UANL. Campus de Ciencias Agropecuarias. Av. Fco. Villa, s/n, Ex-Hacienda El Canadá, Escobedo, N.L., CP 66050, México

*Corresponding Author: J.J. Zarate-Ramos, Department of Parasitology, Facultad de Medicina Veterinaria y Zootecnia, UANL. Campus de Ciencias Agropecuarias. Av. Fco. Villa, s/n, Escobedo, N.L., CP 66050, México
Tel: +52 (81)8313404390*

ABSTRACT

A 2-years-old quarter horse was referred for evaluation of ataxia. It had severe colic, hyperesthesia, tremors, muscle spasms, hypertonicity, lack of flexion of the hind limbs and prolapse of the third eyelids. Numerous ticks identified as *Otobius megnini* were identified in both ears. After tick's removal, a favorable clinical response was observed. So far, this is the first case report of *Otobius megnini* associated with myotonia and colic problems in Mexico.

Key words: Colic, horse, myotonia, *Otobius megnini*, spinose ear tick

INTRODUCTION

Otobius megnini or spinose ear tick is a mite of one host and just the immature stages (larva and nymph) are the parasitic forms, which are found in the ears of domestic animals, including the horse (Njaa and Wilcock, 2012). Because the larva stage attach deep within the ear canal it is difficult to be seen. The spinose ear tick has been identified worldwide (Nava and Guglielmono, 2009). In severe infestations there is a mechanical blockage of the ear canal, which leads to a secondary bacterial infection. Affected animals sometimes do not develop clinical signs, but when occur there is an excessive movement or shaking of the head from one side to another (Madigan *et al.*, 1995). Sometimes, there are CNS signs after rupture or perforation of the tympanic membrane. In other studies heavy ear infestation has been associated with muscle paralysis, myotonia and colic, probably associated to a tick salivary toxin (Pecina, 2012). In most cases, improvement of clinical signs can be seen after the topical administration of organophosphate insecticides directly into the ear canals, which eliminate the ticks (Tee and Feary, 2012). The aim of this case report was to demonstrate the association between *O. megnini* and the presence of myotonia in a horse.

MATERIALS AND METHODS

A 2-year-old male quarter horse, weighing approximately 500 kg, was examined by the local veterinarian of an equestrian club in Nuevo Leon, Mexico due to ataxia, prostration and clinical signs suggestive of colic, which occurred over four episodes, each of which lasted approximately

15 h. The animal was raised in Texas and later moved to Mexico and its vaccination and deworming schedules were current. The horse's health was reported as normal the days before disease presentation.

Disease symptoms started 2 h after the horse received its first meal in the morning, which he refused to eat. Clinical signs began with ataxia, profuse sweating, hitting and scratching the floor with the fore limbs, craning its neck and staring at its flanks. Restlessness, hyperesthesia, tremor on percussion and heavy breathing were also noted. Later, the animal was lethargic, without appetite and reluctant to get up. The veterinarian's presumptive diagnosis was colic and he applied flunixin meglumine (1 mg kg⁻¹, IV, q 12 h), as an analgesic and anti-inflammatory. Signs of colic disappeared after this treatment; however, once the animal was able to stand up, it was still reluctant to walk.

Further physical examination showed that the animal was in good bodily condition. Absence of gastrointestinal sounds was observed by auscultation, as well as tachycardia (60 beats min⁻¹), tachypnea (40 breaths min⁻¹), a body temperature of 37.9°C, dry and hyperemic oral mucosa and a capillary refill time of 4 sec. The horse displayed 8% dehydration; therefore, intravenous support therapy (Hartmann solution 30 mL kg⁻¹ h⁻¹) was provided and a normalization of physiologic parameters was noticed after 2 h.

Hematological examination revealed a slight increase in segmented polymorphonuclear neutrophils (PMNs) (87%, reference range 35-65%). However, it was not considered conclusive of an infection, other than perhaps an undetectable otitis. Biochemical analysis showed an elevation of Aspartate Aminotransferase (AST) (1458 U L⁻¹, reference range 153-411 U L⁻¹), alanine transaminase (ALT) (144 U L⁻¹, reference range 7.3-18.2 U L⁻¹), lactate dehydrogenase (LDH) (2290 U L⁻¹, reference range 131-134 U L⁻¹) and Gamma Glutamyl Transpeptidase (GGT) (31 U L⁻¹, reference range 5-28 U L⁻¹).

After IV treatment, the animal remained quiet, urinated and defecated normally and showed a normal appetite. However, approximately 6 h later, its neurological condition began to deteriorate; the horse presented ataxia, weakness, muscle spasm, hypertonicity not associated with muscle activity, lack of flexion of the hind limbs, prostration and prolapse of the third eyelid in both eyes. No sedative or muscle relaxant was applied. Based on these clinical symptoms, a presumptive diagnosis of a neurological disease was established, not eliminating the possibility of a clinical situation that could be manifesting as colic. To distinguish between these possibilities an examination of the anatomical structures located in the abdominal cavity and head was performed. No apparent digestive abnormalities were found by radiography, rectal palpation, or nasogastric survey. In addition, a physical assessment of the animal's skull was performed to exclude trauma.

RESULTS

During this physical examination, numerous structures were identified inside the horse's ear canals, which were mobile, circular, smaller than 1 cm and with a tan spiny cuticle. These objects were identified as mites and were located both in the external and middle ear. The parasites were removed manually. Because of this finding, a presumptive diagnosis of neurological disease caused by ticks was established. Some live specimens were collected and sent to the Laboratory of Parasitology at the College of Veterinary Medicine (Universidad Autonoma de Nuevo Leon), where they were identified as nymphs and larvae of the tick species *Otobius megnini*, which is also known as spinose ear tick (Fig. 1 and 2).

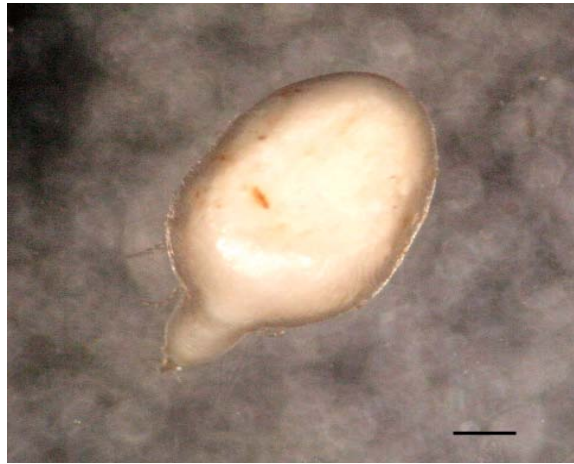


Fig. 1: Dorsal view of a pear-shaped, fully engorged *Otobius megnini* larva stage, removed from the horse's ear. Bar = 1 cm



Fig. 2: Nymph of *Otobius megnini* removed from the horse's ear. Note the Integument covered by hairs and spines. Dorsal view. Bar = 1 cm

Having identified the probable cause of neurological disease, a treatment plan was designed to eliminate any possible remaining ticks and to minimize disease progression. The horse was treated with ivermectin ($200 \mu\text{g kg}^{-1} \text{PO}^{-1}$) in addition to topical application inside the ear of 3% coumaphos, 2% propoxur and 5% prontalbin (inside the ear/q 12 h). The animal had a last episode of spasm and muscular incoordination in the hind limbs 2 h after treatment but then showed progressive improvement. Clinical signs disappeared completely after 3 days.

DISCUSSION

Based on clinical history and positive identification of the ticks in the ear canals of the horse, we determined that the observed muscle problems and colic were associated with the presence of spinose ear ticks, *Otobius megnini*. These ticks have been observed in Canada, USA, Central and

South America, Hawaii, Cuba, India and Africa (Nava and Guglielmone, 2009). These ticks have been observed in Mexico, but only as an incidental finding, not associated with neurological problems.

Otobius megnini has a single-host life cycle and only the immature stages of the tick, the larvae and nymphs, are found in the ears. Adult forms are not parasitic. The spinose ear tick has been reported in a wide variety of mammalian hosts, such as horses, domestic and wild dogs, lagomorphs (Nava and Guglielmone, 2009) and humans (Mans *et al.*, 2004). Severe tick infestation in horses sometimes causes a blockage of the ear canal and eardrum injuries, which can lead to bacterial infections and nerve damage (Njaa and Wilcock, 2012). Otitis could affect the balance of the horse and lead to symptoms that could be misinterpreted as being of neurological origin (Mans *et al.*, 2004). Neuromuscular dysfunction or myotonia and muscle cramping is associated in horses with *O. megnini* neurotoxin (Aleman, 2011). Although no specific toxins have been described for this tick, the presence of a neurotoxin, which is secreted by the salivary glands while feeding on blood, has been suggested (Pecina, 2012). Even though its mechanism of action is unknown, this neurotoxin might interfere with the transmission of nerve impulses in the neuromuscular junction of the host to increase the release of acetylcholine (Madigan *et al.*, 1995).

The presence of neurotoxins related to muscle paralysis or myotonia has been described in other ticks such as *Ixodes holocyclus*, *I. scapularis*, *Amblyomma americanum*, *A. maculatum*, *Rhipicephalus sanguineus* and *Dermacentor* sp. (Purwar, 2009). Besides myotonia, other clinical signs related to neurotoxins have been reported: muscle hypertonicity, prolapse of the third eyelid and signs suggestive of colic, as seen in the case described here. Similarly, elevation of enzymes indicating muscle damage has been reported (Madigan *et al.*, 1995) and we observed similarly elevated enzymes (i.e., elevated AST and LDH). This may be related to muscle spasm or prolonged prostration.

Among the differential diagnoses considered in this case, botulism and tetanus were included. However, botulism was clinically eliminated because the animal did not show dysphagia, nor reduced tongue tone or laryngeal or mandibular paralysis (Tee and Feary, 2012). Tetanus was ruled out because the medical records did not report the presence of injuries or previous surgical procedures that could have supported the growth of *Clostridium tetani*. In addition, the absence of the characteristic paralysis and muscular rigidity caused by this clostridial, as well as the horse's vaccination history, precluded this diagnosis. A point in favor of the diagnosis of spinose ear tick neurotoxicity was the satisfactory clinical response in the animal shortly after removing the ticks from the ears and the complete absence of clinical symptoms 6 weeks after treatment.

ACKNOWLEDGMENT

We would like to thank Edson Antonio Santamaría-Martínez, DVM for his valuable medical assistance with this case report.

REFERENCES

- Aleman, M., 2011. Miscellaneous neurologic or neuromuscular disorders in horses. *Vet. Clin. North Am. Equine. Pract.*, 27: 481-506.
- Madigan, J.E., S.J. Valberg, C. Ragle and J.L. Moody, 1995. Muscle spasms associated with ear tick (*Otobius megnini*) infestations in five horses. *J. Am. Vet. Med. Assoc.*, 207: 74-76.
- Mans, B.J., R. Gothe and A.W.H. Neitz, 2004. Biochemical perspectives on paralysis and other forms of toxicoses caused by ticks. *Parasitology*, 129: S95-S111.

- Nava, S. and A.A. Guglielmone, 2009. Difficulties to control natural infestation with *Otobius megnini* (Acari: Argasidae) nymphs in cattle with systemic biocides. *Res. Vet. Sci.*, 87: 258-259.
- Njaa, B. and B. Wilcock, 2012. The Ear and the Eye. In: *Pathological Basis of Veterinary Disease*, Zachary, J.F. and M.D. McGavin (Eds.). Elsevier Mosby, St. Lois, Missouri, ISBN-13: 978-0323075336, pp: 1153-1244.
- Pecina, C.A., 2012. Tick paralysis. *Semin. Neurol.*, 32: 531-532.
- Purwar, S., 2009. Tick paralysis: An uncommon dimension of tick-borne diseases. *South Med. J.*, 102: 131-131.
- Tee, S.Y. and D.J. Feary, 2012. Suspected tick paralysis (*Ixodes holocyclus*) in a Miniature Horse. *Aust. Vet. J.*, 90: 181-185.