



Research Journal of **Parasitology**

ISSN 1816-4943



Academic
Journals Inc.

www.academicjournals.com

Role of COX-2 in Pathogenesis of Intestinal Cryptosporidiosis and Effect of some Drugs on Treatment of Infection

Gehan S. Sadek and Bahaa El Deen W. El Aswad

Department of Parasitology, Faculty of Medicine, Menoufiya University, Egypt

Corresponding Author: Gehan S. Sadek, Department of Parasitology, Faculty of Medicine, Menoufiya University, Egypt

ABSTRACT

Cryptosporidium is a common cause of severe diarrhea in immunocompromised people and young children. *Cryptosporidium* infection was found to be associated with elevation of many cytokines as tumor necrosis factor alpha (TNF- α) and interleukin 1 β (IL-1 β). These cytokines are key stimulators of prostaglandin synthesis. Prostaglandins may contribute to diarrhea by altering chloride secretion. COX-2 is an inducible enzyme and the expression of the COX-2 gene has been shown to increase in certain inflammatory states. It is known that COX-2 is essential for the synthesis of prostaglandins. There are no studies that define the role of COX-2 in intestinal cryptosporidiosis. The present study was aimed to assess the expression pattern of COX-2 immunohistochemically in the intestine of experimentally infected rats. Also, it was aimed to assess the effectiveness of celecoxib, nitazoxanide, nitazoxanide combined with celecoxib and nitazoxanide combined with azithromycin as anticryptosporidial drugs. It was found that infection with *Cryptosporidium* caused severe pathological changes in ileal tissue. Also, there was a strong correlation between *Cryptosporidium* and COX-2 expression in the same tissue. So, it can be said that the inflammatory effect of *Cryptosporidium* in intestine is mediated through induction of COX-2 but practically "celecoxib" which is an anti COX-2 drug did not represent a significant advance in the treatment of rats infected with *Cryptosporidium*. On the other hand, treatment of infection by nitazoxanide combined with azithromycin represents a significant advance in the treatment of this infection.

Key words: *Cryptosporidium*, COX-2, celecoxib, nitazoxanide, azithromycin

INTRODUCTION

Cryptosporidium sp. is an obligate intracellular protozoan parasite belonging to the phylum Apicomplexa (Desai *et al.*, 2012). Currently, there are 22 known species of *Cryptosporidium* that infect vertebrate hosts reported in scientific literature (Fayer, 2010) of which the zoonotic *Cryptosporidium parvum* and the anthroponotic *Cryptosporidium hominis* are the major causes of human cryptosporidiosis throughout the world (Desai *et al.*, 2012). Cryptosporidiosis was one of the defining illnesses for Acquired Immunodeficiency Syndrome (AIDS) before the discovery of the Human Immunodeficiency Virus (HIV) (Peletz *et al.*, 2013). *Cryptosporidium* is transmitted feco-orally by oocysts and in the intestine, excystation releases four infectious sporozoites that invade the apical region of epithelial cells (enterocytes). Parasite reproduction and gamete formation occur in the epithelium and after a few days, new oocysts are formed (Barakat *et al.*, 2009). The parasite is highly infectious with a minimal infectious dose as low as 10 oocysts (Chappell *et al.*, 2006).

Cryptosporidiosis leads to rapid loss of the microvillus border, shortening and fusion of the villi and lengthening of crypts resulting in malabsorption due to loss of membrane-bound digestive enzymes, decreased absorption, reduced glucose-NaCL absorption and increased chloride anion secretion (Ajajampur *et al.*, 2008).

In immunocompetent patients, infection is frequently asymptomatic, particularly in adults. In symptomatic cases, symptoms appear 2-10 days after infection and result in either acute diarrhea or a persistent form that can last for a few weeks. The diarrhea is usually watery with mucus, sometimes associated with cramps, nausea, vomiting and a low grade fever. Dehydration can result from large volume watery diarrhea particularly in young children and prolonged infection can result in malabsorption. In immunocompromised patients such as those with AIDS or severe malnutrition, infection may be severe and life threatening, also frequently results in chronic diarrhea lasting for several months (Snelling *et al.*, 2007; Tzipori and Widmer, 2008; Desai *et al.*, 2012). *Cryptosporidium* infections in early childhood have been reported to be associated with subsequent impairment of growth, physical fitness and cognitive functions (Guerrant *et al.*, 1999). In immunocompromised patients especially HIV-infected patients, cryptosporidiosis sometimes affects the pulmonary and hepatic tissues (Certad *et al.*, 2005; Palmieri *et al.*, 2005).

It was found that *Cryptosporidium* infection leads to elevation of many cytokines as interferon-gamma (IFN- γ), interleukin-1 β (IL-1 β), tumor necrosis factor-alpha (TNF- α), interleukin-10 (IL-10) and transforming growth factor- β (TGF- β) (Lean *et al.*, 2003; Pantenburg *et al.*, 2008). TNF- α and IL-1 β are key stimulators of prostaglandin synthesis (Robinson *et al.*, 2001). Prostaglandins may contribute to diarrhea by altering chloride secretion (Kirkpatrick *et al.*, 2002; Pantenburg *et al.*, 2008). Cyclooxygenase-2 (COX-2) is the rate-limiting enzyme in the conversion of arachidonic acid to prostaglandin H₂ (PGH₂), the precursor of a large group of biologically active mediators, such as PGE₂, prostacyclin and thromboxane A₂ (Moraitis *et al.*, 2005). COX-2 is an early gene expressed in response to many cytokines and is involved in several biological processes, including inflammation, immune responses, cell growth, ovulation and regulation of vascular tone (Smith *et al.*, 2002). The role of COX-2 in *Cryptosporidium* infection has been previously evaluated in only one study concerning pulmonary cryptosporidiosis and it was found that there was a strong correlation between COX-2 expression and *Cryptosporidium* infection in lung (Asaad and Sadek, 2006). To our knowledge, there are no studies that define the role of COX-2 in intestinal cryptosporidiosis.

No fully effective approved drug therapy exists for *Cryptosporidium* infections of immunocompetent and immunosuppressed patients. Recently, only nitazoxanide (5-nitrothiazole derivative) was approved by the Food and Drug Administration (FDA) for the treatment of diarrhea caused by *Cryptosporidium* in humans. However, the effectiveness of this drug in immunosuppressed individuals is unclear (Graczyk *et al.*, 2011). Azithromycin is a macrolide antibiotic that was introduced as a potential anticryptosporidial drug. *In vitro* studies have shown it to be active in inhibiting *Cryptosporidium parvum* growth at concentrations close to those available *in vivo*. Some studies have shown that nitazoxanide in combination with azithromycin are active in inhibiting *Cryptosporidium parvum* growth *in vitro* (Giacometti *et al.*, 2000). Celecoxib is a COX-2 selective, Non-steroidal Anti-inflammatory Drug (NSAID) with low gastrointestinal toxicity. It was found that this drug inhibits the PGE₂ release of stimulated cells. It is now widely used to relieve the symptoms and signs of osteoarthritis and rheumatoid arthritis in adults (Niederberger *et al.*, 2001).

The present study was aimed to assess the expression pattern of COX-2 immunohistochemically in the intestine of experimentally infected rats to investigate whether the inflammatory effect of

Cryptosporidium in intestine is mediated through induction of COX-2. Moreover, the current study was aimed to assess the effectiveness of nitazoxanide, celecoxib, nitazoxanide combined with celecoxib and nitazoxanide combined with azithromycin as anticryptosporidial drugs.

MATERIALS AND METHODS

ASSESSMENT OF THE ROLE OF COX-2 IN PATHOGENESIS OF INTESTINAL CRYPTOSPORIDIOSIS

For this aim, 30 parasite free female albino rats aged 2-3 weeks were used. These rats were classified as group A: 20 immunosuppressed rats orally infected with *Cryptosporidium* oocysts and group B: 10 immunosuppressed non-infected rats (control group). The rats were fed *ad libitum* on a standard pellet diet obtained commercially (Taylor *et al.*, 1999). Immunosuppression was achieved by giving oral dexamethasone at a dose of 0.25 µg/kg/day for 10 successive days before the inoculation of *Cryptosporidium* oocysts until the end of the experiment (Rehg, 1994).

Preparation of the infecting inoculum and infection of rats: *Cryptosporidium* oocysts for experimental infection were prepared by examining stool samples of malnourished children suffering from diarrhea who attended Menoufiya University Hospital, using modified Ziehl-Neelsen staining method (Henriksen and Pohlenz, 1981). Positive samples were suspended in two volumes of 2.5% potassium dichromate solution; this suspension was then passed through a graded series of sieves to remove large particles and stored at 4°C until use, but not for more than 6 months (Harp *et al.*, 1992; Lacroix *et al.*, 2001). Infecting inoculum was prepared according to Gardner *et al.* (1991) as follows: One volume of stool suspension was mixed with four volumes of a saturated solution of NaCl in distilled water and then centrifuged at 1000 rpm for 10 min. The 5 mL aliquots of the supernatant containing oocysts were mixed with 45 mL of distilled water and re-centrifuged. The supernatant was then decanted and oocysts in the pellet were re-suspended in 10 mL of saturated NaCl solution and the procedure was repeated. The final pellets containing oocysts were pooled and suspended in 25 mL of 1% sodium hypochlorite solution and centrifuged at 1000 rpm for 10 min. The pellet was washed in distilled water and oocysts were counted with a haemocytometer. The amount given to each rat was adjusted to contain about 2.6×10^5 oocysts (Suresh and Rehag, 1996). Each control rat was inoculated with the same amount of non-infected stool samples after the same purification process (Gardner *et al.*, 1991). Before inoculation, the animals were fasted for 4-6 h (Miller *et al.*, 1990).

Examination of rats after infection: From the second day post-inoculation, fresh faecal pellets were collected from five rats (selected randomly) from each group and examined using modified Ziehl-Neelsen staining method to ensure establishment of *Cryptosporidium* infection (Henriksen and Pohlenz, 1981). The rats were sacrificed 8 weeks post-infection by cervical dislocation (Mead *et al.*, 1991; Rasmussen and Healey, 1992). After death, intestinal autopsies (from ileum) were fixed in 10% neutral formalin and embedded in paraffin blocks. Serial sections were prepared for routine haematoxylin and eosin (H and E) staining and immunostaining by COX-2.

Immunohistochemical staining of COX-2: It was performed on 4 µm thick sections by Zymed's 2nd generation LAB-SA (Labeled {Strept} Avidin-Biotin) technology using the broad-spectrum, peroxidase, Histostain-Plus Kit. Briefly, tissue slides were deparaffinized with xylene and then rehydrated through three changes of alcohol. Endogenous peroxidase activity was blocked.

Heat-induced epitope retrieval using citrate buffer (pH 6.0) was performed. The slides were rinsed in Tris Buffered Saline (TBS) (pH 7.6) and then incubated overnight with mouse monoclonal antibody (Zymed Laboratories Inc., Isotype: IgG, Clone: COX 229, concentrate 0.5 mL. The dilution used was 1:100). After washing with TBS, sections were incubated with the secondary antibody (biotinylated goat anti-mouse/rabbit immunoglobulin) for 30 min, then the avidin biotin complex for a further 45 min. The 3-3'diaminobenzidine tetrahydrochloride (DAB) was used as chromogen and sections were counterstained with Mayer's haematoxylin. Positive controls were included according to the data sheets of the antibodies. Negative control with omission of the primary antibody was included (Asaad and Sadek, 2006).

Evaluation of immunohistochemical staining: In each section, ten high power fields were selected and a total of 1000 cells were examined. Brownish cytoplasmic staining was considered positive. COX-2 positivity was assessed by evaluation of both the intensity and extent of staining. The intensity of staining was estimated subjectively and was classified as negative, weak, moderate and strong (Shamma *et al.*, 2000). Regarding the extent of staining, it was classified as negative where, ≤ 5 of cells were found stained, focal positive if 6-50% of cells were stained and diffuse positive if more than 50% of cells were stained (Nofech-Mozes *et al.*, 2006).

ASSESSMENT OF EFFECTIVENESS OF SOME DRUGS FOR THE TREATMENT OF CRYPTOSPORIDIOSIS

Seventy five free female albino rats aged 2-3 weeks were used. They were classified in the following groups:

- Group 1:** Fifteen immunosuppressed infected rats were given celecoxib "celebrix" (Pfizer Pharmaceuticals, USA) in a daily oral dose of 50 mg/kg/day (Niederberger *et al.*, 2001) starting 10 days post-inoculation and lasting for 10 days
- Group 2:** Fifteen immunosuppressed infected rats were given nitazoxanide "Alinia" (Romark Laboratories, USA) in a daily oral dose of 100 mg/kg/day (Theodos *et al.*, 1998; Li *et al.*, 2003) starting 10 days post-inoculation and lasting for 10 days (Theodos *et al.*, 1998; Fox and Saravolatz, 2005)
- Group 3:** Fifteen immunosuppressed infected rats were given nitazoxanide in a daily oral dose of 100 mg/kg/day combined with celecoxib in a daily oral dose of 50 mg/kg/day starting 10 days post-inoculation and lasting for 10 days
- Group 4:** Fifteen immunosuppressed infected rats were given nitazoxanide in a daily oral dose of 100 mg/kg/day combined with azithromycin "Zithromax" (Pfizer Pharmaceuticals, USA) in a daily oral dose of 200 mg/kg/day starting 10 days post-inoculation and lasting for 10 days (Rehg, 1991, 1994)
- Group 5:** Fifteen immunosuppressed infected untreated rats which were used as a control group

Immunosuppression and infection of animals were performed as previously mentioned. The effect of the used drugs was evaluated by two methods:

- **Stool examination:** The day before onset of drug intake, fresh faecal pellets were collected from five rats (selected randomly) from each group and examined to just ensure the establishment of infection. These pellets were first homogenized in a small volume of saline and sieved to remove the coarse fecal debris; then they were stained using modified Ziehl-Neelsen

staining method (Henriksen and Pohlenz, 1981). The day following the last day of drug intake just before sacrifice, feces of all rats of different groups were collected. Each fecal sample was prepared and stained by modified Ziehl Neelsen staining method as mentioned above. Stained fecal smears were examined and the number of *Cryptosporidium* oocysts was counted in 10 High Power Fields (HPF), then the arithmetic mean of the number of oocysts/HPF for each animal and then for each group of animals was calculated

- **Histopathological examination:** The rats were sacrificed after 10 days of drug intake by cervical dislocation and the terminal 2 cm of ilea were fixed in 10% formalin and embedded in paraffin blocks {ileum was used to assess the severity of infection in both drug-treated and control animals as it was previously proved that it is the intestinal segment that is most heavily infected with cryptosporidia (Rehg, 1991)}. Serial sections were prepared and stained with haematoxylin and eosin. The severity of infection of ileal sections was assessed by counting the endogenous stages of the parasite in the epithelium of 10 villous-crypt units, then the arithmetic mean of the number/one villous crypt unit was calculated for each animal and then for each group of animals (Healey *et al.*, 1995). Any pathological changes in the tissues were also recorded

Statistical analysis: Data were collected, tabulated, statistically analyzed by computer using SPSS version 16. Descriptive data were represented by number and percentage for qualitative variables. Kruskal Wallis test was done to compare between not normally distributed quantitative variables for more than two groups.

RESULTS

Examination of rats after infection: It was found that two rats related to group A and one rat related to group B died probably due to immunosuppression or due to infection itself in group A.

Examination of fecal smears of rats belonging to group A by modified Ziehl-Neelsen staining method showed that oocysts appeared as round or ovoid bright red structures on a green background, they were about 5 µm in diameter, they had distinct thick walls and various inner structures as 4 dark sporozoites could be seen in some oocysts (Fig. 1). No oocysts appeared in fecal smears of rats belonging to group B.

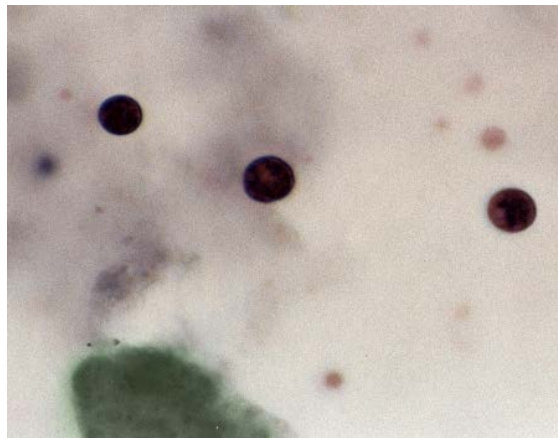


Fig. 1: *Cryptosporidium* oocysts in stool of group A rats stained by modified Ziehl-Neelsen stain (X1000)

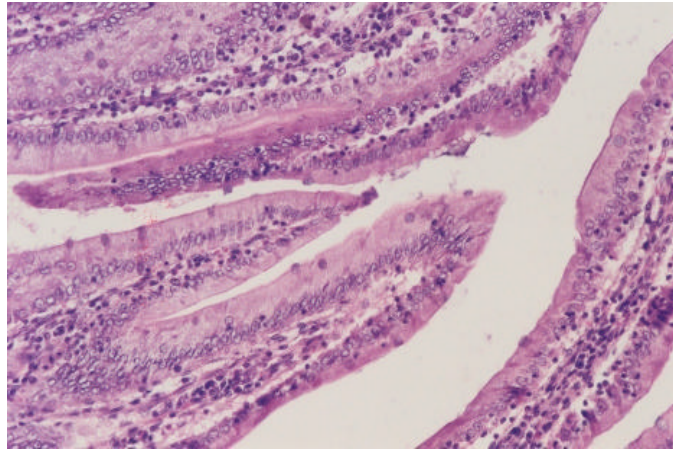


Fig. 2: Section in the ileum of an immunosuppressed infected rat belonging to group A showing the endogenous stages of *Cryptosporidium* in the brush border of the mucous membrane (H and E, X 200)

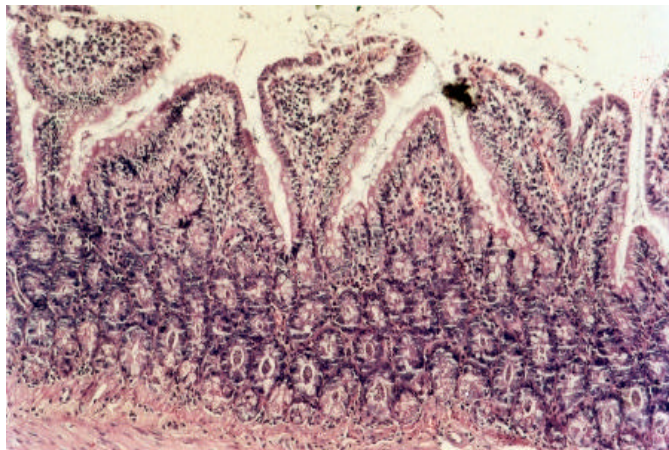


Fig. 3: Section in ileum of an immunosuppressed infected rat belonging to group A showing shortening and blunting of villi and crypt hyperplasia (H and E, X200)

In H and E stained sections of rats belonging to group A, the endogenous stages of the parasite could be detected occupying the microvillus region of the ileal mucosa. They appeared as small oval or round basophilic bodies about 2-5 μm in diameter (Fig. 2). The mucosa and submucosa showed severe pathological changes. These changes were in the form of shortening and blunting of the villi in some areas (Fig. 3) and villous atrophy in other areas, the columnar epithelial cells on atrophic villi were replaced by cuboidal cells. In some rats, there were denudation of mucosa or complete loss of villi (Fig. 4). Crypts showed hyperplasia, deepening and absence of paneth cells (Fig. 3). Lamina propria showed moderate to severe oedema and cellular infiltration with plasma cells, lymphocytes and histiocytes (Fig. 5). None of these pathological changes appeared in sections of rats related to group B (control group) (Fig. 6).

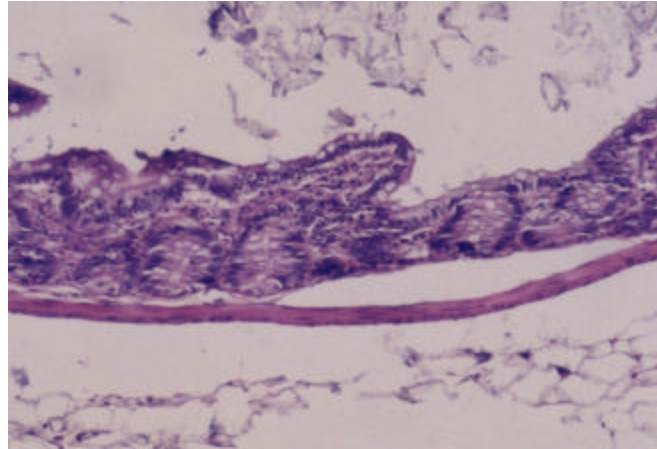


Fig. 4: Section in ileum of an immunosuppressed infected rat belonging to group A showing complete loss of villi (H and E, X200)

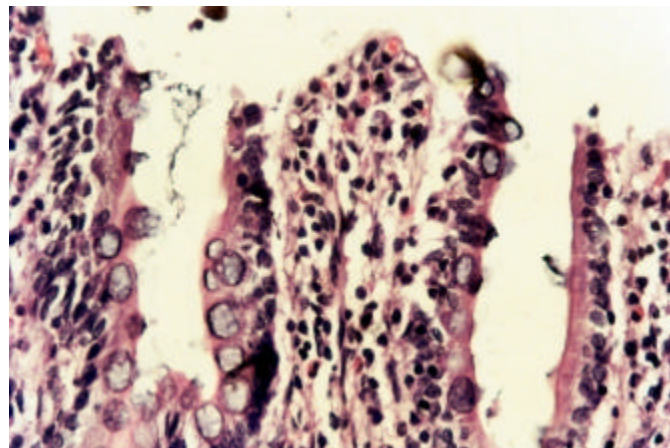


Fig. 5: Section in ileum of an immunosuppressed infected rat belonging to group A showing endogenous stages of *Cryptosporidium*, sloughing of the brush border of mucous membrane and infiltration of lamina propria with plasma cells, lymphocytes and histiocytes (H and E, X1000)

Evaluation of immunohistochemical staining: Concerning sections related to group A, all sections showed strong staining intensity of COX-2 in inflammatory cells in lamina propria, 11 out of 18 (61.1%) showed diffuse positivity (Fig. 7), 5 sections (27.8%) showed focal positivity (Fig. 8) and 2 (11.1%) were negative as extent of staining was less than 5% (Fig. 9). The percentage of positivity for COX-2 as a whole was 88.9%. So, it was considered that there was a strong correlation between *Cryptosporidium* infection and COX-2 expression. Concerning sections related to group B, extent of staining was 0% (negative) in 7 sections out of 9 sections (Fig. 10) and in the remaining 2 sections, extent was less than 5%, so it was also considered negative. The intensity of staining in these two sections was weak (Table 1).

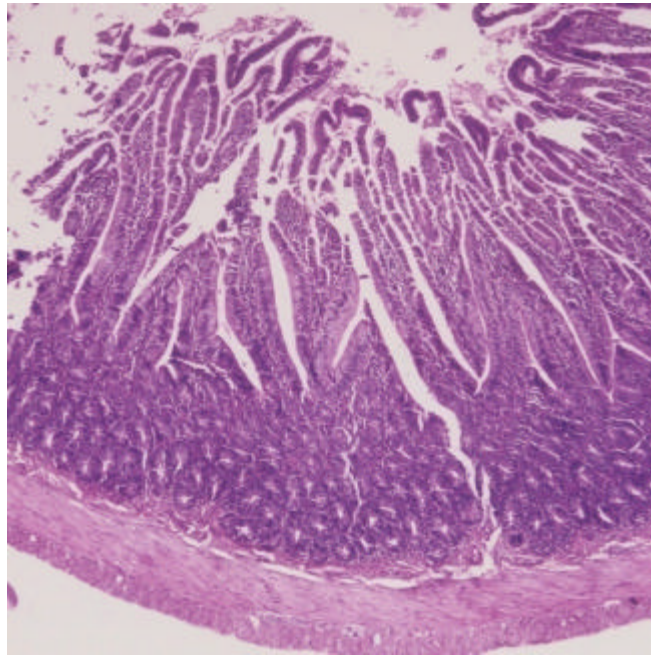


Fig. 6: Section in ileum of an uninfected rat belonging to group B (control group) showing normal villi. No pathological changes are seen (H and E, X40)

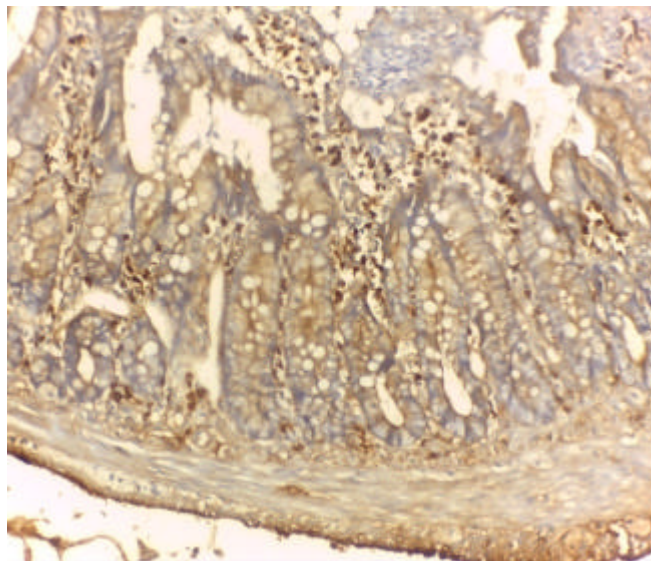


Fig. 7: Section in ileum of an immunosuppressed infected rat belonging to group A showing strong diffuse COX-2 expression in inflammatory cells of lamina propria (IPS, X200)

Assessment of effectiveness of some drugs for the treatment of cryptosporidiosis: At first, it was found that one rat belonging to group 1 died, two rats died from group 2, one rat died from group 3, two rats died from group 4 and two rats died from group 5 probably due to infection or immunosuppression.

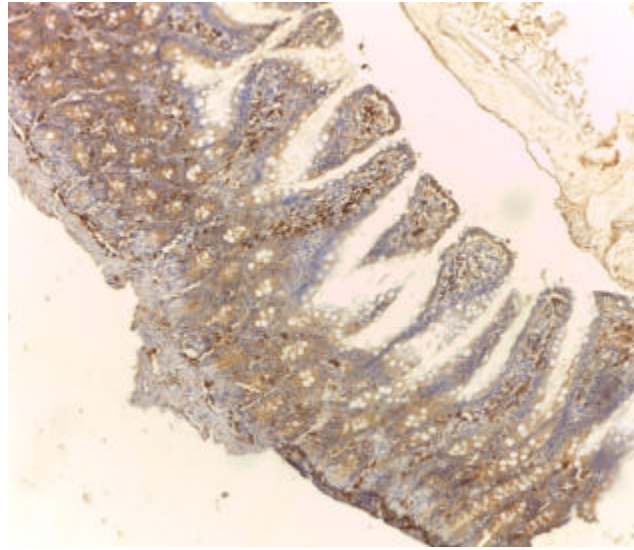


Fig. 8: Section in ileum of an immunosuppressed infected rat belonging to group A showing strong focal positivity of COX-2 expression in inflammatory cells of lamina propria. There is blunting of villi (IPS, X100)

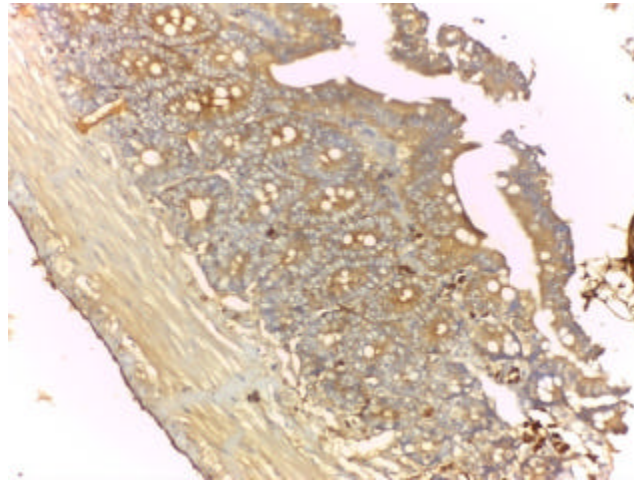


Fig. 9: Section in ileum of an immunosuppressed infected rat belonging to group A showing negative expression of COX-2 as extent of staining is less than 5%. There is atrophy of villi (IPS, X200)

Table 1: Percentage of positivity for COX-2 in sections of rats belonging to groups A and B

Extent of staining	Group A (total 18 rats)		Group B (total 9 rats)	
	No.	Percentage (%)	No.	Percentage (%)
Negative	2	11.1	9	100
Focal	5	27.8	0	0
Diffuse	11	61.1	0	0
Total positive	16	88.9	0	0

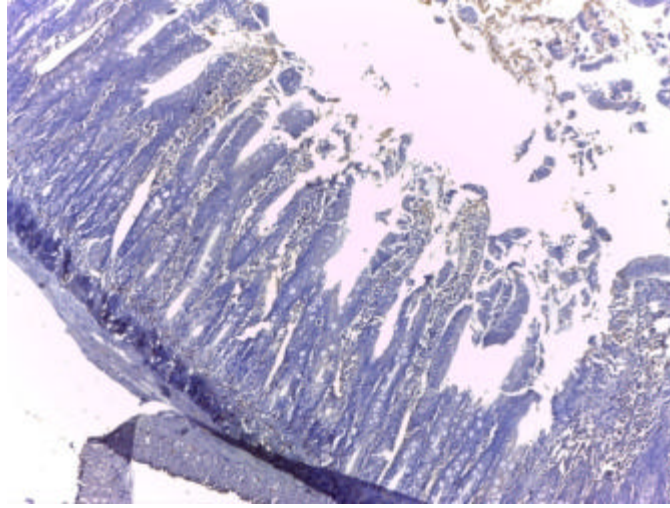


Fig. 10: Section in ileum of an immunosuppressed non-infected rat belonging to group B (control group) showing negative expression of COX-2. Villi are normal (IPS, X100)

Table 2: Counts of *Cryptosporidium* oocysts/HPF in the stools of immunosuppressed infected treated rats (group 1, 2, 3 and 4) vs. immunosuppressed infected untreated rats (group 5) at last day of experiment

Mean No. of	Group 1	Group 2	Group 3	Group 4	Group 5	Kruskal-wallis test	p-value
<i>Cryptosporidium</i> oocysts/HPF	(n = 14)	(n = 13)	(n = 14)	(n = 13)	(n = 13)		
	18.74±1.89	7.13± 9.42	6.64±9.29	1.37±4.96	18.35±1.73	31.16	0.000

p<0.05 = Significant. P1 (group 1 vs. group 2) = 0.008, P2 (group 1 vs. group 3) = 0.003*, P3 (group 1 vs. group 4) = 0.000*, P4 (group 1 vs. group 5) = 1.00, P5 (group 2 vs. group 3) = 1.00, P6 (group 2 vs. group 4) = 0.51, P7 (group 2 vs. group 5) = 0.01*, P8 (group 3 vs. group 4) = 0.55, P9 (group 3 vs. group 5) = 0.004*, P10 (group 4 vs. group 5) = 0.000*

Stool examination: At last day of experiment, it was found that the mean number of *Cryptosporidium* oocysts/HPF was 18.74±1.89, 7.13±9.42, 6.64±9.29, 1.37±4.96 and 18.35±1.73 in groups 1, 2, 3, 4 and 5, respectively. Regarding group 1 (rats treated with celecoxib alone), there was a significant statistical difference between it and groups 2, 3 and 4 (p = 0.008, 0.003 and 0.000, respectively) while there was no significant statistical difference between it and group 5 (control group) (p = 1.00). Concerning group 2 (rats treated with nitazoxanide alone), there was a significant statistical difference between it and both groups 1 and 5 (control group) (p = 0.008 and 0.01, respectively) while there was no significant statistical difference between it and both groups 3 and 4 (p = 1.00 and 0.51, respectively). As regards group 3 (rats treated with nitazoxanide and celecoxib), there was a significant difference between it and groups 1 and 5 (control group) (p = 0.003 and 0.004, respectively) while there was no significant statistical difference between it and both groups 2 and 4 (p = 1.00 and 0.55, respectively). Regarding group 4 (rats treated with nitazoxanide and azithromycin), there was a significant statistical difference between it and both groups 1 and 5 (control group) (p = 0.000 and 0.000, respectively) while there was no significant statistical difference between it and both groups 2 and 3 (p = 0.51 and 0.55, respectively) (Table 2).

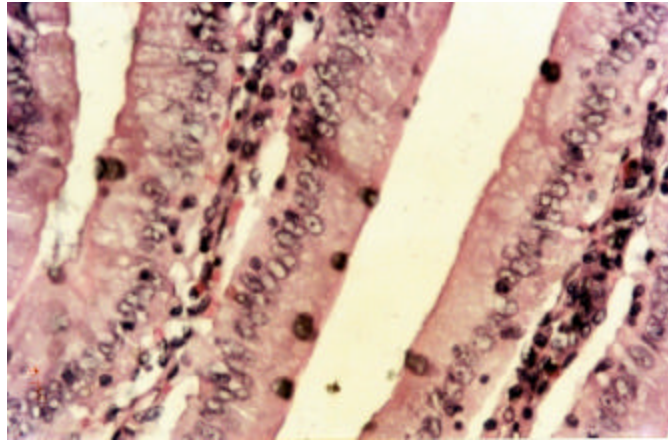


Fig. 11: Section in ileum of rat belonging to group 1 (rats treated with celecoxib alone) showing numerous endogenous stages of *Cryptosporidium* in the brush border of the mucous membrane at last day of experiment (H and E, X400)

Table 3: Counts of the endogenous stages of *Cryptosporidium*/one villous-crypt unit in ilea of immunosuppressed infected treated rats (group 1, 2, 3 and 4) vs. immunosuppressed infected untreated rats (group 5) at the sacrifice day

Mean No. of endogenous stages of <i>Cryptosporidium</i> oocysts/one villous-crypt unit	Group 1 (n = 14)	Group 2 (n = 13)	Group 3 (n = 14)	Group 4 (n = 13)	Group 5 (n = 13)	Kruskal-wallis test	p-value
	15.72±1.57	6.18±8.17	5.33±7.35	1.13±4.10	15.67±2.66	31.41	0.000

p<0.05 = significant. P1 (group 1 vs. group 2) = 0.01, P2 (group 1 vs. group 3) = 0.002*, P3 (group 1 vs. group 4) = 0.000*, P4 (group 1 vs. group 5) = 1.00, P5 (group 2 vs. group 3) = 1.00, P6 (group 2 vs. group 4) = 0.47, P7 (group 2 vs. group 5) = 0.01*, P8 (group 3 vs. group 4) = 0.58, P9 (group 3 vs. group 5) = 0.002*, P10 (group 4 vs. group 5) = 0.000*

Histopathological examination: At last day of experiment, it was found that the mean number of endogenous stages of *Cryptosporidium*/one villous-crypt unit was 15.72±1.57, 6.18±8.17, 5.33±7.35, 1.13±4.10 and 15.67±2.66 in groups 1, 2, 3, 4 and 5, respectively. Regarding group 1, there was a significant statistical difference between it and groups 2, 3 and 4 (p = 0.01, 0.002 and 0.000, respectively) while there was no significant statistical difference between it and group 5 (control group) (p = 1.00). Concerning group 2, there was a significant statistical difference between it and both groups 1 and 5 (p = 0.01 and 0.01, respectively) while there was no significant statistical difference between it and both groups 3 and 4 (p = 1.00 and 0.47, respectively). As regards group 3, there was a significant statistical difference between it and both groups 1 and 5 (control group) (p = 0.002 and 0.002, respectively) but there was no significant difference between it and both groups 2 and 4 (p = 1.00 and 0.58, respectively). Concerning group 4, there was a significant statistical difference between it and both groups 1 and 5 (control group) (p = 0.000 and 0.000, respectively) while there was no significant statistical difference between it and both group 2 and 3 (p = 0.47 and 0.58, respectively) (Table 3, Fig. 11, 12).

Also, at last day of experiment, the pathological changes were mild in group 3, moderate in groups 1, 2 and 4 and severe in group 5. They were in the form of shortening and broadening of some villi, atrophy of other villi, sloughing of the brush border of the mucous membrane and cellular inflammatory reaction (Fig. 13, 14).

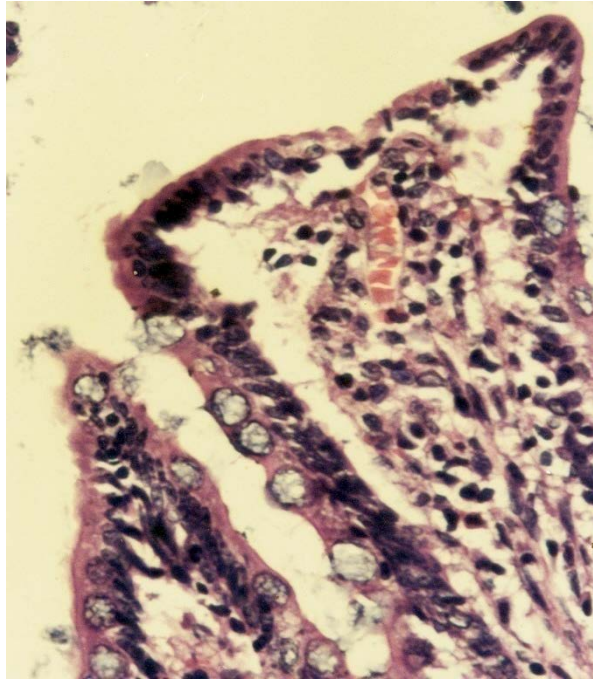


Fig. 12: Section in ileum of a rat belonging to group 1 (rats treated with celecoxib alone) showing numerous endogenous stages of *Cryptosporidium* in the brush border of the mucous membrane at last day of experiment. There is infiltration of lamina propria by plasma cells, lymphocytes and histiocytes (H and E, X1000)

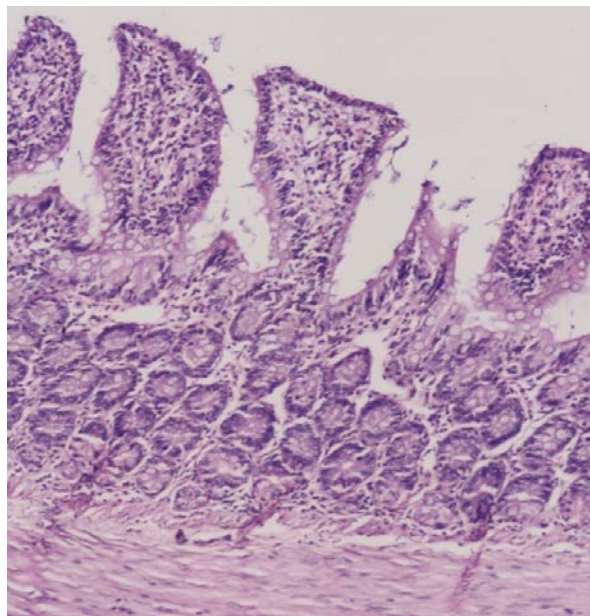


Fig. 13: Section in ileum of a rat belonging to group 2 (rats treated with nitazoxanide alone) showing shortening and blunting of villi at last day of experiment (H and E, X200)

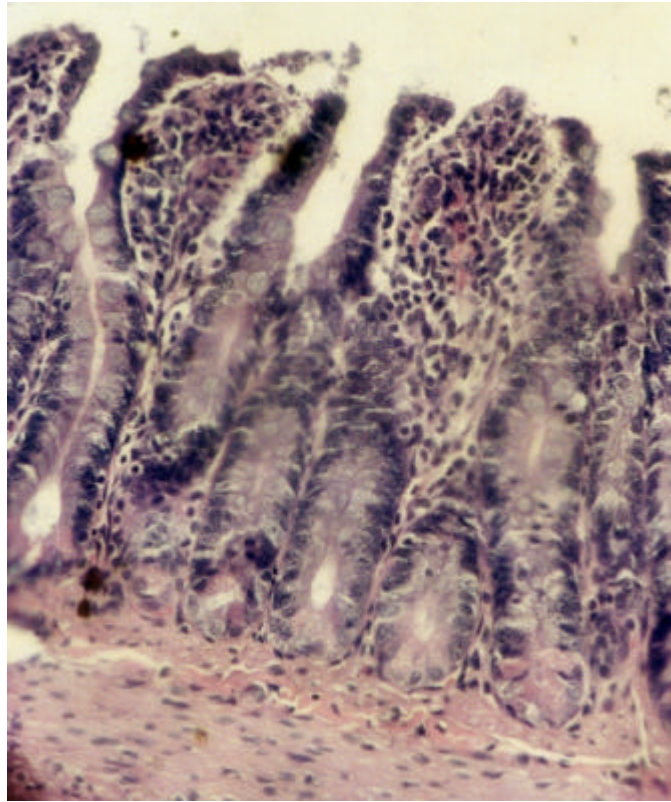


Fig. 14: Section in ileum of a rat belonging to group 5 showing shortening and blunting of villi, sloughing of mucosa and infiltration of lamina propria with inflammatory cells (H and E, X400)

Table 4: Cure rate after treatment of cryptosporidiosis with some drugs

Groups of rats	No. of treated rats	No. of cured rats	Cure (%)
1	14	0	0.00
2	13	8	61.53
3	14	9	64.28
4	13	12	92.30
5	13	0	0.00

On calculating the percentage of cure of the drugs used in this study, it was found that no rats out of the 14 rats belonging to group 1 were cured as proved by the presence of *Cryptosporidium* oocysts in their stool smears and the presence of endogenous stages of *Cryptosporidium* in their ileal sections, thus the percentage of cure was 0%. In group 2, 8 rats out of 13 rats were cured completely as proved by cessation of oocyst shedding in stool and absence of endogenous stages of *Cryptosporidium* in their ilea, so the percentage of cure was 61.53%. Concerning group 3, 9 rats out of 14 were cured completely, so the percentage of cure was 64.28%. Regarding group 4, 12 rats out of 13 were cured completely, so the percentage of cure was 92.3% (Table 4).

DISCUSSION

Cryptosporidium is one of the most widespread intestinal parasites and a common cause of severe diarrhea in immunocompromised people and young children (Peletz *et al.*, 2013). It is a serious parasite and is associated with high morbidity and mortality (Hassanain *et al.*, 2011; Desai *et al.*, 2012) and this underscores the need for more effective treatment. However, treatment remains difficult and unsatisfactory (Amadi *et al.*, 2009). There is no evidence to support the role of chemotherapeutic agents in the management of cryptosporidiosis among immunocompromised individuals. Some evidence of effectiveness for nitazoxanide in a combined population of immunocompetent and immunocompromised individuals was identified and is worth further study. At present, supportive management including rehydration therapy, electrolyte replacement and antimotility agents may be the only option for most immunocompromised patients (Abubakar *et al.*, 2007).

The mechanisms by which *Cryptosporidium* infections cause its spectrum of clinical illness and outcomes are poorly understood. To understand the pathophysiology of cryptosporidiosis, it is important to define the intestinal mucosal immune responses to *Cryptosporidium* infection and their potential impact on intestinal secretory responses (Kirkpatrick *et al.*, 2002). It was found that many cytokines are involved in the pathophysiology of cryptosporidiosis as IL-1 β , TNF- α , IFN- γ , IL-10 and TGF- β (Lean *et al.*, 2006; Pantenburg *et al.*, 2008). TNF- α and IL-1 β could cause diarrhea by increasing prostaglandin secretion which leads to increase in chloride secretion and by sodium and glucose malabsorption (Robinson *et al.*, 2001). These same proinflammatory cytokines could also directly alter the mucosal epithelial integrity leading to diminished barrier function (Stockmann *et al.*, 1998). The increased permeability may result in back diffusion of ions and water into the gut lumen thereby contributing to a greater loss in gastrointestinal fluids (Zhang *et al.*, 2000). IFN- γ either alone or in combination with other proinflammatory cytokines has been shown to stimulate antimicrobial killing mechanisms in Intestinal Epithelial Cells (IEC) *in vitro*. This could involve either increased production of microbicidal nitric oxide derivatives via the up regulation of Inducible Nitric Oxide Synthase (iNOS) (Lean *et al.*, 2003) or deprivation of available Fe²⁺ required for development of parasites within the IEC (McDonald *et al.*, 2006). TGF- β and IL-10 are likely involved in anti-inflammatory and healing processes. They may also lead to generation of secretory IgA which may prevent reinfection (Pantenburg *et al.*, 2008). COX-2 is an inducible enzyme and the expression of the COX-2 gene has been shown to increase in certain inflammatory states (Paulson *et al.*, 2000). It is known that COX-2 is essential for the synthesis of prostaglandins (Asaad and Sadek, 2006).

There has been a great interest in drugs that can selectively block COX-2 as reducing its levels will be effective strategy for inhibiting inflammation (Mulshine *et al.*, 2004; Shishodia and Aggarwal, 2004). However, the role of COX-2 gene expression in *Cryptosporidium*-induced intestinal injury is still not clear. Therefore, in the present study we assessed the expression of COX-2 to investigate whether the pathological lesions produced by *Cryptosporidium* in intestine were the result of over expression of COX-2. Hence, it was found that there was a strong correlation between COX-2 expression and inflammation induced by cryptosporidiosis, we tried celecoxib which is a selective COX-2 NSAID to treat rats infected with *Cryptosporidium* to exhibit whether this drug would be useful in amelioration of inflammation and hence clinical manifestations of the disease. Also, nitazoxanide was tried as an anti-cryptosporidial drug either singly or in combination with celecoxib or azithromycin.

Regarding the pathological changes which were observed in ileal tissue of rats belonging to group A, they were in accordance with the findings of Ollivett *et al.* (2009) who recorded the same changes and added that this intestinal pathology creates a maldigestive, malabsorptive and osmotic diarrhea that may or may not be secretory in nature.

Concerning results of immunohistochemical staining of COX-2, it was found that the percentage of positivity for COX-2 as a whole was 88.9% in rats of group A and all of them showed strong intensity. So, it was considered that there was a strong correlation between *Cryptosporidium* infection and COX-2 expression. To our knowledge, no studies have evaluated this correlation in intestine. However, our result coincides with the result of Asaad and Sadek (2006) who recorded that 66.7% of immunosuppressed rats showed COX-2 overexpression and 14/20 of them had a strong COX-2 quick score on examining cryptosporidiosis in lung. The same authors added that this result is consistent with previous studies demonstrating that the induction of COX-2 production is a hallmark of inflammation in general. Moreover, they stated that the signaling pathways important for *Cryptosporidium* induction of lung damage could interact with each other as follows: TNF- α could activate the cytoplasmic form of NF-kB resulting in NF-kB activation, COX-2 mRNA induction and COX-2 protein production. This chain of events might contribute to the pathogenesis of *Cryptosporidium*. This may moreover suggest that COX-2 and NF-kB mediate the inflammatory response owing to *Cryptosporidium* infection. This indicates that pharmacological interventions that can inhibit COX-2 and NF-kB may prove beneficial in the treatment of *Cryptosporidium* infection (Asaad and Sadek, 2006).

In the present study, COX-2 staining was observed in inflammatory cells in lamina propria. In agreement with our results, Zamamiri-Davis *et al.* (2000, 2002) stated that COX-2 was expressed in activated macrophages, monocytes and several other cell types and has been identified in chronic inflammatory conditions *in vivo*.

Concerning group 1 (rats treated with celecoxib), it was found that no rats were cured completely as proved by the persistence of oocysts in their stools and persistence of endogenous stages of *Cryptosporidium* in their ileal tissues at last day of experiment (cure rate = 0%). This explains why there was a statistical significant difference between this group and group 2, 3 and 4 regarding the mean number of *Cryptosporidium* oocysts/HPF in stool and mean number of endogenous of the parasite/one villous-crypt unit. As regards the severity of pathological changes, it was found that these changes were moderate at last day of experiment in comparison with those of group 5 {control group} which were severe.

It must be mentioned that the idea of using celecoxib in the treatment of rats infected with *Cryptosporidium* in this study was to evaluate whether the drug would be useful in the remission of the pathological changes accompanying the infection or not. Of course, it is known that it has no anti-parasitic activity but only it is an inhibitor of COX-2 giving analgesic and anti-inflammatory effects (Paulson *et al.*, 2000). In this study, it was proved that there was remission of the pathological changes in rats treated with celecoxib. This is in accordance with the results of several authors who reported its anti-inflammatory effect (Paulson *et al.*, 2000). Those authors added that the mechanism of action of non-steroidal anti-inflammatory drugs has been attributed to the blockade of the production of prostaglandins by inhibition of COX-2. Prostaglandin secretion has an essential role in diarrhea by either increasing chloride secretion or sodium and glucose malabsorption (Robinson *et al.*, 2001). So, use of celecoxib would be useful in the management of symptoms of cryptosporidiosis in combination with a useful antiparasitic drug.

Concerning group 2 (rats treated with nitazoxanide alone), it was found that 8 out of 13 rats were cured completely (cure rate = 61.53%) and there was a statistical significant difference between it and control group regarding the mean number of *Cryptosporidium* oocysts/HPF in stool and the mean number of endogenous stages of *Cryptosporidium*/one villous-crypt unit. At last day of experiment, pathological changes were found to be moderate. This result supports the results of Fox and Saravolatz (2005) who demonstrated that 80% of Egyptian patients treated with nitazoxanide had resolved diarrhea and associated symptoms 7 days after initiation of therapy. It was reported that the anti-parasitic activity of nitazoxanide is believed to be due to interference with the Pyruvate-ferridoxin Oxireductase (PFOR) enzyme dependent electron transfer reaction which is essential for anaerobic energy metabolism of the parasite. However, this may not be the only pathway by which nitazoxanide exhibits its anti-protozoal activity (Parashar and Arya, 2005). Several studies have reported that nitazoxanide is generally well tolerated and adverse reactions are mild and transient (Fox and Saravolatz, 2005). On the other hand, some authors stated that nitazoxanide has limited effectiveness for treating cryptosporidiosis in immunosuppressed patients including AIDS patients (Gargala, 2008; Cabada and White, 2010).

Regarding group 3 (rats treated with nitazoxanide and celecoxib), it was found that 9 out of 14 rats were cured completely (cure rate = 64.28%) and there was a statistical significant difference between this group and control group concerning the mean number of *Cryptosporidium* oocysts/HPF in stool and mean number of endogenous stages of the parasite/one villous crypt unit. The most significant observation was that this was the only group which showed mild pathological changes at last day of experiment when compared to the other groups which showed moderate changes while control group showed severe changes. These results were not unexpected, they are the normal sequelae of the results given by the two above mentioned groups. This group has merged the results of the antiparasitic effect of nitazoxanide and the effect of celecoxib as anti-COX-2.

As regards group 4 (rats treated with nitazoxanide and azithromycin), it was found that 12 out of 13 rats were completely cured (cure rate = 92.3%) and there was a significant statistical difference between this group and control group regarding the mean number of *Cryptosporidium* oocysts/HPF in stool and the mean number of endogenous stages of *Cryptosporidium*/one villous-crypt unit. At last day of experiment, this group showed moderate pathological changes. These results are in agreement with those of Giacometti *et al.* (2000) who reported that combination of nitazoxanide and azithromycin was active in inhibiting *Cryptosporidium parvum* at concentrations that appeared not to be toxic to the human cell monolayer. They presumed that the additive effect observed between nitazoxanide and azithromycin may be a consequence of the cumulative inhibitory effect on different and essential metabolic pathways of the parasite. Also, they added that nitazoxanide has a dose-dependent effect on DNA synthesis while the action of azithromycin resulted in inhibition of protein synthesis by binding to the transpeptidation site of the larger ribosomal subunit. Also, results of the present study concerning combination of nitazoxanide with azithromycin are in accordance with those of Gardner *et al.* (1991) and Fox and Saravolatz (2005) who reported the same observations.

From the above mentioned results concerning the effect of different drug regimens on treatment of cryptosporidiosis in rats, it is observed that the use of celecoxib alone as anti COX-2 in the management of infection did not give any cure rate but it caused remission in the pathological changes caused by the disease. Also, it caused a better remission of these changes

when used in combination with nitazoxanide but in this case the cure rate was 64.28% only which is much less than the cure rate shown by rats treated with nitazoxanide combined with azithromycin.

It could be concluded that infection with *Cryptosporidium* caused severe pathological changes in ileal tissue. There was a strong correlation between *Cryptosporidium* and COX-2 expression in the same tissue. So, it can be said that the inflammatory effect of *Cryptosporidium* in intestine is mediated through induction of COX-2 but practically "celecoxib" which is anti COX-2 drug did not represent a significant advance in the treatment of rats infected with *Cryptosporidium*. On the other hand, treatment of infection by nitazoxanide combined with azithromycin represents a significant advance in the treatment of *Cryptosporidium* infection giving the highest cure rate (92.3%) among all the used drug regimens.

ACKNOWLEDGMENT

The authors would like to express their gratitude to Professor Dr. Nancy Youssef Asaad (Professor of Pathology, Faculty of Medicine, Menoufiya University) for her assistance in reading the pathological data in H and E sections and in reading results of immunohistochemical staining.

REFERENCES

- Abubakar, I., S.H. Aliyu, C. Arumugam, N.K. Usman and P.R. Hunter, 2007. Treatment of cryptosporidiosis in immunocompromised individuals: Systematic review and meta-analysis. Br. J. Clin. Pharmacol., 63: 387-393.
- Ajjampur, S.S.R., P. Sankaran and G. Kang, 2008. *Cryptosporidium* species in HIV-infected individuals in India: An overview. Natl. Med. J. India, 21: 178-184.
- Amadi, B., M. Mwiya, S. Sianongo, L. Payne, A. Watuka, M. Katubulushi and P. Kelly, 2009. High dose prolonged treatment with nitazoxanide is not effective for cryptosporidiosis in HIV positive Zambian children: A randomised controlled trial. BMC Infect. Dis., Vol. 9 10.1186/1471-2334-9-195
- Asaad, N.Y. and G.S. Sadek, 2006. Pulmonary cryptosporidiosis: Role of COX2 and NF- κ B. APMIS, 114: 682-689.
- Barakat, F.M., V. McDonald, G.R. Foster, M.G. Tovey and D.S. Korbel, 2009. *Cryptosporidium parvum* infection rapidly induces a protective innate immune response involving type I interferon. J. Infect. Dis., 200: 1548-1555.
- Cabada, M.M. and A.C. Jr. White, 2010. Treatment of cryptosporidiosis: Do we know what we think we know? Curr. Opin. Infect. Dis., 23: 494-499.
- Certad, G., A. Arenas-Pinto, L. Pocaterra, G. Ferrara, J. Castro, A. Bello and L. Nunez, 2005. Cryptosporidiosis in HIV-infected Venezuelan adults is strongly associated with acute or chronic diarrhea. Am. J. Trop. Med. Hyg., 73: 54-57.
- Chappell, C.L., P.C. Okhuysen, R. Langer-Curry, G. Widmer, D.E. Akiyoshi, S. Tanriverdi and S. Tzipori, 2006. *Cryptosporidium hominis*: Experimental challenge of healthy adults. Am. J. Trop. Med. Hyg., 75: 851-857.
- Desai, N.T., R. Sarkar and G. Kang, 2012. Cryptosporidiosis: An under-recognized public health problem. Trop. Parasitol., 2: 91-98.
- Fayer, R., 2010. Taxonomy and species delimitation in *Cryptosporidium*. Exp. Parasitol., 124: 90-97.

- Fox, L.M. and L.D. Saravolatz, 2005. Nitazoxanide: A New Thiazolide antiparasitic agent. Clin. Infectious Dis., 40: 1173-1180.
- Gardner, A.L., J.K. Roche, C.S. Weikel and R.L. Guerrant, 1991. Intestinal cryptosporidiosis: Pathophysiologic alterations and specific cellular and humoral immune responses in rnu/+ and rnu/rnu (athymic) rats. Am. J. Trop. Med. Hyg., 44: 49-62.
- Gargala, G., 2008. Drug treatment and novel drug target against *Cryptosporidium*. Parasite, 15: 275-281.
- Giacometti, A., O. Cirioni, F. Barchiesi, F. Ancarani and G. Scalise, 2000. Activity of nitazoxanide alone and in combination with azithromycin and rifabutin against *Cryptosporidium parvum* in cell culture. J. Antimicrob. Chemother., 45: 453-456.
- Graczyk, Z., L. Chomicz, M. Kozłowska, Z. Kazimierzczuk and T.K. Graczyk, 2011. Novel and promising compounds to treat *Cryptosporidium parvum* infections. Parasitol. Res., 109: 591-594.
- Guerrant, D.I., S.R. Moore, A.A. Lima, P.D. Patrick, J.B. Schorling and R.L. Guerrant, 1999. Association of early childhood diarrhea and cryptosporidiosis with impaired physical fitness and cognitive function four-seven years later in a poor urban community in northeast Brazil. Am. J. Trop. Med. Hyg., 61: 707-713.
- Harp, J.A., W. Chen and A.G. Harmsen, 1992. Resistance of severe combined immunodeficient mice to infection with *Cryptosporidium parvum*: The importance of intestinal microflora. Infect. Immun., 60: 3509-3512.
- Hassanain, M.A., F.A.M. Khalil, K.A. AbdEl-Razik and R.M. Shaapan, 2011. Prevalence and molecular discrimination of *Cryptosporidium parvum* in calves in Behira provinces, Egypt. Res. J. Parasitol., 6: 101-108.
- Healey, M.C., S. Yang, K.R. Rasmussen, M.K. Jackson and C. Du, 1995. Therapeutic efficacy of paromomycin in immunosuppressed adult mice infected with *Cryptosporidium parvum*. J. Parasitol., 18: 114-116.
- Henriksen, S.A. and J.F. Pohlenz, 1981. Staining of cryptosporidia by a modified Ziehl-Neelsen technique. Acta Vet. Scand., 22: 594-596.
- Kirkpatrick, B.D., M.M. Daniels, S.S. Jean, J.W. Pape and C. Karp *et al.*, 2002. Cryptosporidiosis stimulates an inflammatory intestinal response in malnourished Haitian children. J. Infect. Dis., 186: 94-101.
- Lacroix, S., R. Mancassola, M. Naciri and F. Laurent, 2001. *Cryptosporidium parvum*-specific mucosal immune response in C57BL/6 neonatal and gamma interferon-deficient mice: Role of tumor necrosis factor alpha in protection. Infect. Immun., 69: 1635-1642.
- Lean, I.S., S.A. McDonald, M. Bajaj-Elliott, R.C. Pollok, M.J. Farthing and V. McDonald, 2003. Interleukin-4 and transforming growth factor β have opposing regulatory effects on gamma interferon-mediated inhibition of *Cryptosporidium parvum* reproduction. Infect. Immun., 71: 4580-4585.
- Lean, I.S., S Lacroix-Lamande, F. Laurent and V. McDonald, 2006. Role of tumor necrosis factor alpha in development of immunity against *Cryptosporidium parvum* infection. Infect. Immun., 74: 4379-4382.
- Li, X., P. Brasseur, P. Agnamey, D. Lemeteil, L. Favennec, J.J. Ballet and J.F. Rossignol, 2003. Long-lasting anticryptosporidial activity of nitazoxanide in an immunosuppressed rat model. Folia Parasitol., 50: 19-22.

- McDonald, V., R.C.G. Pollok, W. Dhaliwal, S. Naik, M.J.G. Farthing and M. Bajaj-Elliott, 2006. A potential role for interleukin-18 in inhibition of the development of *Cryptosporidium parvum*. Clin. Exp. Immunol., 145: 555-562.
- Mead, J.R., M.J. Arrowood, R.W. Sidwell and M.C. Healey, 1991. Chronic *Cryptosporidium parvum* infections in congenitally immunodeficient SCID and nude mice. J. Infect. Dis., 168: 1297-1304.
- Miller, R.A., M.A Bronsdon and W.R. Morton, 1990. Experimental cryptosporidiosis in a primate model. J. Infect. Dis., 161: 312-315.
- Moraitis, D., B. Du, M.S. De Lorenzo, J.O. Boyle and B.B. Weksler *et al.*, 2005. Levels of cyclooxygenase-2 are increased in the oral mucosa of smokers: Evidence for the role of epidermal growth factor receptor and its ligands. Cancer Res., 15: 664-670.
- Mulshine, J.L., J.C. Atkinson, R.O. Greer, V.A. Papadimitrakopoulou and C. van Waes *et al.*, 2004. Randomized, double-blind, placebo-controlled phase IIb trial of the cyclooxygenase inhibitor ketorolac as an oral rinse in oropharyngeal leukoplakia. Clin. Cancer Res., 10: 1565-1573.
- Niederberger, E., I. Tegeder, G. Vetter, A. Schmidtke and H. Schmidt *et al.*, 2001. Celecoxib loses its anti-inflammatory efficacy at high doses through activation of NF- κ B. FASEM J., 15: 1622-1624.
- Nofech-Mozes, S., R. Kupets, G. Rasty, N. Ismail, A. Covens and M.A. Khalifa, 2006. Cyclooxygenase-2 (COX-2) immunostaining does not correlate with the degree of vulvar neoplasia. J. Obstet. Gynaecol. Can., 28: 290-294.
- Ollivett, T.L., D.V. Nydam, D.D. Bowman, J.A. Zambriski, M.L. Bellosa, T.C. Linden and T.J. Divers, 2009. Effect of nitazoxanide on cryptosporidiosis in experimentally infected neonatal dairy calves. J. Dairy Sci., 92: 1643-1648.
- Palmieri, F., S. Cicalini, N. Froio, E.B. Rizzi and D. Goletti *et al.*, 2005. Pulmonary cryptosporidiosis in an AIDS patient: Successful treatment with paromomycin plus azithromycin. Int. J. STD AIDS, 16: 515-517.
- Pantenburg, B., S.M. Dann, H.C. Wang, P. Robinson, A. Castellanos-Gonzalez, D.E. Lewis and A.C. White, 2008. Intestinal immune response to human *Cryptosporidium* sp. infection. Infect. Immun., 76: 23-29.
- Parashar, A. and R. Arya, 2005. Drug therapy. Indian Pediat., 42: 1161-1165.
- Paulson, S.K., J.Y. Zhang, A.P. Breau, J.D. Hribar and N.W. Liu *et al.*, 2000. Pharmacokinetics, tissue distribution, metabolism and excretion of celecoxib in rats. Drug Metab. Dispos., 28: 514-521.
- Peletz, R., T. Mahin, M. Elliott, M. Montgomery and T. Clasen, 2013. Preventing cryptosporidiosis: The need for safe drinking water. Bull. World Health Org., 91: 238-238a.
- Rasmussen, K.R. and M.C. Healey, 1992. Experimental *Cryptosporidium parvum* infections in immunosuppressed adult mice. Infect. Immun., 60: 1648-1652.
- Rehg, J.E., 1991. Activity of azithromycin against cryptosporidia in immunosuppressed rats. J. Infect. Dis., 163: 1293-1296.
- Rehg, J.E., 1994. A comparison of anticryptosporidial activity of paromomycin with that of other aminoglycosides and azithromycin in immunosuppressed rats. J. Infect. Dis., 170: 934-938.
- Robinson, P., P.C. Okhuysen, C.L. Chappell, D.E. Lewis, I. Shahab, A. Janecki and A.C. White, 2001. Expression of tumor necrosis factor Alpha and interleukin 1 β in jejuna of volunteers after experimental challenge with *Cryptosporidium parvum* correlates with exposure but not with symptoms. Infect. Immun., 69: 1172-1174.

- Shamma, A., H. Yamamoto, Y. Doki, J. Okami and M. Kondo *et al.*, 2000. Up-regulation of cyclooxygenase-2 in squamous carcinogenesis of the esophagus. Clin. Cancer Res., 6: 1229-1238.
- Shishodia, S. and B.B. Aggarwal, 2004. Cyclooxygenase (COX)-2 inhibitor celecoxib abrogates activation of cigarette smoke-induced Nuclear Factor (NF)- κ B by suppressing activation of I- κ B α kinase in human non-small cell lung carcinoma: Correlation with suppression of cyclin D1, COX-2 and matrix metalloproteinase-9. Cancer Res., 64: 5004-5012.
- Smith, R.S., R. Kelly, B.H. Iglewski and R.P. Phipps, 2002. The *Pseudomonas* autoinducer N-(3-oxododecanoyl) homoserine lactone induces cyclooxygenase-2 and prostaglandin E2 production in human lung fibroblasts: Implications for inflammation. J. Immunol., 169: 2636-2642.
- Snelling, W.J., L. Xiao, G. Ortega-Pierres, C.J. Lowery and J.E. Moore *et al.*, 2007. Cryptosporidiosis in developing countries. J. Infect. Dev. Countries, 1: 242-256.
- Stockmann, M., H. Schmitz, M. Fromm, W. Schmidt and K. Rokos *et al.*, 1998. The mechanism of diarrhea in HIV is based on an impaired epithelial barrier function that could be induced by a specific cytokine pattern. Ann. N. Y. Acad. Sci., 859: 267-270.
- Suresh, P. and J.E. Rehg, 1996. Comparative evaluation of several techniques for purification of *Cryptosporidium parvum* oocysts from rat feces. J. Clin. Microbiol., 34: 38-40.
- Taylor, M.A., R.N. Marshall, J.A. Green and J. Catchpole, 1999. The pathogenesis of experimental infections of *Cryptosporidium muris* (strain RN 66) in outbred nude mice. Vet. Parasitol., 86: 41-48.
- Theodos, C.M., J.K. Griffiths, J. D'Onfro, A. Fairfield and S. Tzipori, 1998. Efficacy of nitazoxanide against *Cryptosporidium parvum* in cell culture and in animal models. Antimicrob. Agents Chemother., 42: 1959-1965.
- Tzipori, S. and G. Widmer, 2008. A hundred-year retrospective on cryptosporidiosis. Trends Parasitol., 24: 184-189.
- Zamamiri-Davis, F., Y. Lu, J.T. Thompson, K.S. Prabhu, L.M. Sordillo and C.C. Reddy, 2000. Up regulation of cyclooxygenase-2 is mediated by NF-kappa B in macrophages during selenium deficiency. Mol. Biol. Cell, 11(Suppl.): 49-49.
- Zamamiri-Davis, F., Y. Lu, J.T. Thompson, K.S. Prabhu, P.V. Reddy, L.M. Sordillo and C.C. Reddy, 2002. Nuclear factor- κ B mediates over-expression of cyclooxygenase-2 during activation of RAW 264.7 macrophages in selenium deficiency. Free Radic. Biol. Med., 32: 890-897.
- Zhang, Y., B. Lee, M. Thompson, R. Glass and R.C. Lee *et al.*, 2000. Lactulose-Mannitol intestinal permeability test in children with diarrhea caused by *Rotavirus* and *Cryptosporidium*. J. Pediatr. Gastroenterol. Nutr., 31: 16-21.