

Hepatoprotective Activity of Rohitaka ghrita against Paracetamol Induced Liver Injury in Rat

¹R. Goyal, ²B. Ravishankar, ²V.J. Shukla and ¹M. Singh

¹Department of Pharmacology, ISF College of Pharmacy, Moga, Punjab, 142001, India

²Gujarat Ayurved University, Jamnagar, Gujarat, India

Abstract: Background: Rohitaka ghrita an ayurvedic formulation is recommended to use in various clinical conditions including jaundice, cirrhosis and cholestasis etc. The study was designed to investigate the hepatoprotective activity of Rohitaka ghrita using paracetamol intoxication model in rats. Wistar albino rats (180-240 g) were employed into the study. **Material and Methods:** Rohitaka ghrita was administered at the dose of 3.6 and 7.2 g kg⁻¹, p.o. daily. Liver damage was induced by the administering paracetamol (3 g kg⁻¹, p.o.). Silymarin was used as standard. **Results:** Paracetamol intoxication caused marked increase in SGPT, SGOT, ALP and bilirubin levels. It further impaired the hepatic antioxidant system as evidenced by increased lipid peroxidation; decreased glutathione, catalase levels and also Na⁺K⁺ATPase level. Moreover, the liver histopathology revealed central vein dilation, infiltration and fatty degeneration due to PCM intoxication. However, treatment with Rohitaka ghrita (3.6 and 7.2 g kg⁻¹) and silymarin (25 mg kg⁻¹) markedly reversed the effects of PCM in rat. Rohitaka ghrita have a significant hepatoprotective potential against paracetamol induced hepatocellular damage in rats. **Conclusion:** The present study provides a scientific rationale for its traditional and commercial uses in the management of liver diseases.

Key words: Rohitaka ghrita, hepatoprotective, paracetamol, ATPase, *Tecomella undulate*

INTRODUCTION

Liver diseases are the biggest threat to the world which is characterized with impaired metabolic and secretory functions of liver clinically as jaundice, cirrhosis, hepatitis, liver cancer and ultimately liver failure. However, traditional systems of medicine recommend making use of several plants and formulations for the treatment of liver diseases.

Rohitaka ghrita, a hepatoprotective ayurvedic formulation, is composed with *Tecomella undulate* (Rohitaka), *Ziziphus jujuba* (Badar), *Piper longum* (Pippali), *Piper retrofractum* (Chavya), *Plumbago zeylanica* (Chitraka), *Zinziber officinalis* (Sunthi), in cow's ghee (Go-ghrita). The constituting plant drugs are noted to contain iridoid glucosides, tecomin (Verma *et al.*, 1986); jujubosides A and B (Shen *et al.*, 2009); piperine, pipartine (Jalalpure *et al.*, 2003; Koul and Kapil, 1993); retrofractamides (Matsuda *et al.*, 2008); naphthoquinones: Plumbagin, chitranone (Tilak *et al.*, 2004) and gingerol, zingerone (Abdullah *et al.*, 2004), respectively which are reported to possess hepatoprotective and antioxidant

properties. *T. undulate* Seem commonly called rohitaka, is a small deciduous shrub which is incorporated into several commercial hepatoprotective formulations as Rohitakghrita, Rohitakarishtha, Herboliv, Livo-plus, Hepato-100, Amlycure, Liv-52 and Himoliv. It is well documented to have hepatoprotective (Khatri *et al.*, 2009; Rana *et al.*, 2008) and choleric activities (Azam *et al.*, 1997).

However, no comprehensive evidence has yet been documented for the hepatoprotective activity of Rohitaka ghrita experimentally or clinically. Keeping this in view, the present study was designed to evaluate the protective effect of Rohitaka ghrita and its putative mechanisms using paracetamol induced liver injury model in rats.

MATERIALS AND METHODS

Rohitaka ghrita: Plant drugs were procured from Pharmacy unit attached to the Gujarat Ayurved University, Jamnagar, Gujarat. A decoction was prepared with rohitaka bark and badar fruit in water. The remaining

plant drugs: Rohitaka bark, pippali fruits and roots, chavya, chitraka roots and sunthi rhizome were mixed (5:1:1:1:1) for paste formation. Then, the decoction and paste were formulated with cow's ghee (go-ghrita), cooled and stored in air-tight container.

Chemicals: Paracetamol and Silymarin were obtained from GlaxoSmithKline, Mumbai and Micro Labs., Goa, respectively. All the chemicals or reagents were procured from reputed firms and were of analytical grade. The biochemical kits were purchased from ERBA Diagnostic, Mannheim Transasia Biochemicals Ltd, Daman.

Animals: Wistar albino rats (180-240 g) of either sex were obtained from animal house, Gujarat Ayurved University, Jamnagar. Animals were housed under 12-12 h light/dark cycles. They were maintained on food pellets and water ad libitum. The temperature and humidity were maintained at 20-25°C and 45-50%, respectively. The experiments were carried out in conformity with the Institutional Animal Ethical Committee (IAEC) and with internationally accepted principles for laboratory animal use.

Paracetamol induced hepatotoxicity

Experimental schedule: Rats were divided into different groups, each comprising six animals (n = 6). The treatment schedule is as following (Table 1).

The test drugs were allowed to administer orally for 7 days. On 3rd and 5th days, two hrs after to test drug administration, PCM (3 g kg⁻¹, p.o.) was given to each group except saline control. On 7th day, blood was withdrawn through retro orbital plexus of each rat after 4 h of test drug. Serum was separated from blood by centrifugation. The animals were sacrificed by cervical dislocation and livers were rapidly excised out for tissue biochemical estimations. The excised livers were washed with ice-cold saline and blotted dry. The 10% liver homogenates were prepared in 0.9% normal saline and in 0.1 M phosphate buffer (for glutathione only) using Teflon-glass homogenizer and then centrifuged to obtain clear supernant.

Assessment of liver functions

Biochemical estimations: The serum biochemical estimations as Serum Glutamate Pyruvate Transaminase (SGPT), Serum Glutamate Oxaloacetate Transaminase (SGOT), bilirubin and Alkaline Phosphatase (ALP) were done spectrophotometrically using biochemical kits.

The supernant obtained from liver homogenates were subjected for estimations of lipid peroxidation (Ohkawa *et al.*, 1979), glutathione (Ellman, 1959), catalase (Sinha, 1972), Na⁺K⁺ATPase (Bonting, 1970) and total protein (Lowry *et al.*, 1951).

Table 1: Experimental schedule

Group	For 7 days	On 3rd and 5th days
I	Saline control: Normal Saline (SC)	-
II	Paracetamol control (PC)	PCM, 3 g kg ⁻¹ , p.o.
III	Vehicle control (Cow's ghee), 3.6 g kg ⁻¹ , p.o. (VC+PC)	PCM, 3 g kg ⁻¹ , p.o.
IV	Rohitaka Ghrita, 3.6 g kg ⁻¹ , p.o. (RG+PC)	PCM, 3 g kg ⁻¹ , p.o.
V	2xRohitaka Ghrita, 7.2 g kg ⁻¹ , p.o. (2RG+PC)	PCM, 3 g kg ⁻¹ , p.o.
VI	Reference Silymarin, 25 m g kg ⁻¹ , p.o. (RS+PC)	PCM, 3 g kg ⁻¹ , p.o.

(p.o.: Per oral, PCM: Paracetamol)

Histopathological evaluation: The excised livers were fixed in formalin (10%), embedded in paraffin block, sectioned upto 5 µm and microscopically examined after staining with hematoxylin and eosin.

Statistical analysis: Data expressed as Mean±SEM (Standard error of mean) and were analyzed using one way ANOVA followed by Dunnett's multiple comparison test as post-hoc analysis. The p<0.05 considered to be statistically significant.

RESULTS

Effect on serum markers: Paracetamol administration caused significant rise in serum markers namely SGPT, SGOT, bilirubin and ALP in comparison to saline control (Table 2). However, oral treatment with Rohitaka ghrita (3.6 and 7.2 g kg⁻¹, p.o.) markedly inhibited the increased level of these serum markers, similar to silymarin. (Table 2).

Effect on liver tissue enzymes: Paracetamol intoxication resulted in a significant depletion of antioxidants as glutathione, catalase and Na⁺K⁺ATPase level in liver tissue in comparison to SC. Moreover, it also caused increased lipid peroxidation (TBARS). However, Rohitaka ghrita (3.6 and 7.2 g kg⁻¹, p.o.) and silymarin significantly reversed the effects of paracetamol on tissue enzymes. In addition, Vehicle control showed no significant effect on tissue enzymes except on TBARS level (Fig. 1a-d).

Effects on histopathological observations: Scanning of liver sections showed marked pathological changes in liver parenchyma due to paracetamol as compared to saline control. There were significant cell infiltration around the periportal system, vacuolization of the parenchymal cells and focal necrosis. These changes were found to be less in RG and RS groups. In 2xRG and VC, mild to moderate attenuation in pathological changes were observed (Fig. 2a-f).

Table 2: Effect of drug treatment on various serum markers

Group	SGPT (IU L ⁻¹)	SGOT (IU L ⁻¹)	Bilirubin (mg dL ⁻¹)	ALP (IU L ⁻¹)
SC	109.45±1.87	137.53±5.45	0.41±0.020	220.34±5.05
PC	197.43±5.07 ^a	336.71±8.40 ^a	0.92±0.014 ^a	423.16±5.28 ^a
VC+PC	171.20±3.57 ^b	307.26±5.20 ^b	0.82±0.026 ^b	398.24±4.12 ^b
RG+PC	126.27±3.36 ^b	213.98±5.57 ^b	0.62±0.021 ^b	311.48±5.76 ^b
2RG+PC	152.94±2.93 ^b	264.75±3.64 ^b	0.74±0.023 ^b	356.36±6.11 ^b
RS+PC	116.83±3.08 ^b	172.60±7.36 ^b	0.51±0.031 ^b	233.16±4.40 ^b

Values are Mean±SEM, ^ap<0.05 vs. SC; ^bp<0.05 vs. PC; SGPT: Serum glutamate pyruvate transaminase; SGOT: Serum glutamate oxaloacetate transaminase; ALP: Alkaline phosphatase; SC: Saline control; PC: Paracetamol control; VC: Vehicle control; RG: Rohitaka ghrita; 2RG: 2 Rohitaka ghrita; RS: Reference Silymarin

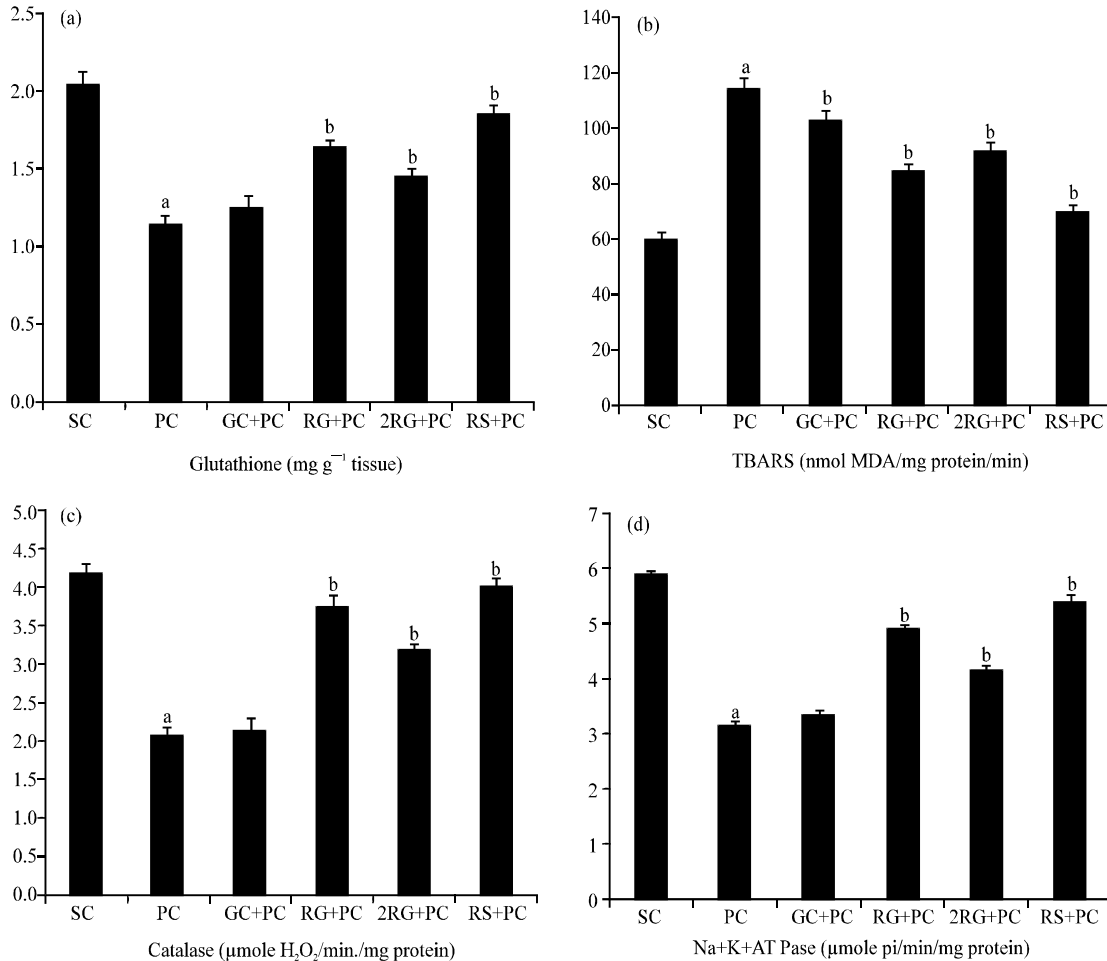


Fig. 1 (a-d): Effect on liver tissue enzymes: (a) Glutathione, (b) TBARS, (c) Catalase, (d) Na⁺K⁺ATPase. SC: Saline Control; PC: Paracetamol Control; VC: Vehicle Control; RG: Rohitaka ghrita, 2RG: 2xRohitaka ghrita; RS: Reference Silymarin; Results: Mean±SEM, a: p<0.05 vs. SC; b: p<0.05 vs. PC

DISCUSSION

The study provides evidence that Rohitaka ghrita (3.6 and 7.2 g kg⁻¹) acts as hepatoprotective agent against paracetamol induced liver injury in rats. RG was recommended to cure liver diseases at the dose of 3.6 g kg⁻¹, p.o. (Khatri *et al.*, 2009). A recent study demonstrated the hepatoprotective effects of Tecomella

undulate against experimental liver injury (Rana *et al.*, 2008). In addition, the other plant drugs: *Ziziphus jujube* (Shen *et al.*, 2009), *Piper longum* (Jalalpure *et al.*, 2003), *Piper retrofractum* (Matsuda *et al.*, 2008), *Plumbago zeylanica* and *Zinziber officinalis* (Abdullah *et al.*, 2004) are also known to possess hepatoprotective efficacy and hence incorporated frequently into several hepatoprotective formulations.

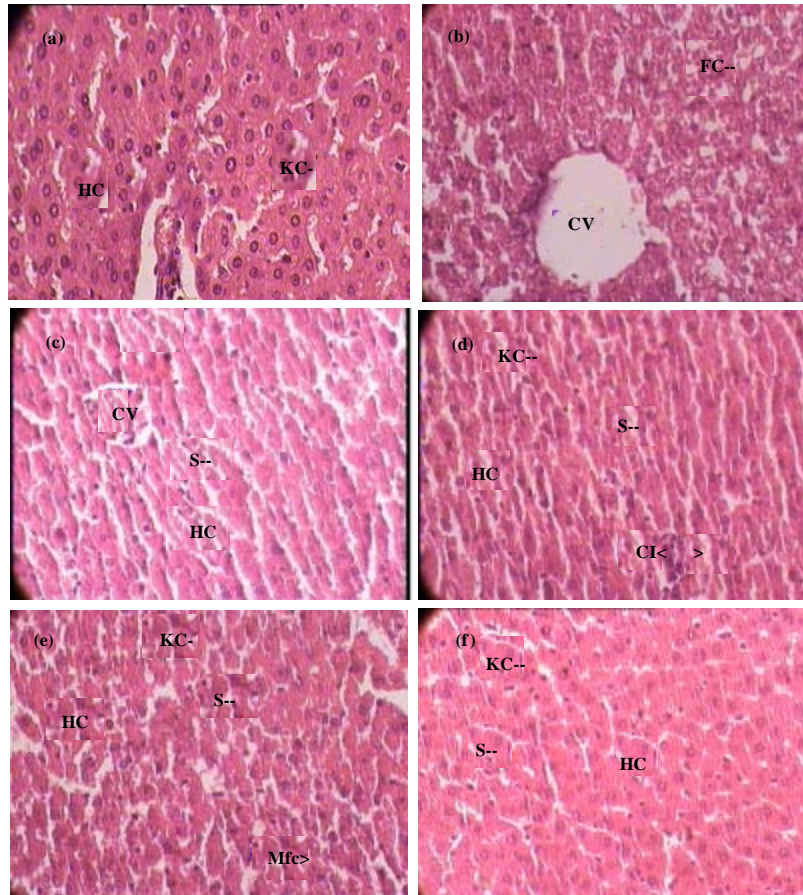


Fig. 2 (a-f): Histopathological Studies, Histological images of rat livers displaying normal lobular architecture with central veins and radiating hepatic cords in (a) saline control rat. (b) Depicted the significant cell infiltration around the periportal system, vacuolization of parenchymal cells, focal necrosis and central vein dilation in paracetamol control rat. (c) The liver from ghrita control group revealed mild to moderate protection against paracetamol. (d, e) The degree of liver damage and degeneration were significantly reduced with rohitaka ghrita (3.6 and 7.2 g kg⁻¹) treatment. (f) Treatment with silymarin (25 mg kg⁻¹) also markedly restored the liver cell constitution. (hc: hepatic cell; cv: central vein; s: sinusoid; fc: fatty changes; kc: kupffer cell; mfc: micro-fatty changes)

The present study demonstrated that the paracetamol, on overdose, found to cause liver injury clinically manifested as jaundice, steatosis and fibrosis (Lewis *et al.*, 2006). It is a well established model to induce hepatocellular damage in rat (Porchezian and Ansari, 2005). Its reactive metabolite N-acetyl-p-benzoquinoneimine (NAPQI) causes free radical production as peroxynitrite (Nelson, 1990). It is attributed with the increase in SGPT and SGOT levels as release into systemic circulation due to membrane damage of hepatocytes and necrosis. However, RG markedly reduced these serum transaminases, similar to silymarin whereas vehicle control was less prominent. The PCM intoxication

facilitates the release of alkaline phosphatase due to hepato-biliary damage and it was notably reversed by RG and vehicle treatments. Hence, the reduction in the levels of these enzymes demonstrates membrane stabilizing activity of RG. Moreover, the increase in serum bilirubin level is a conventional indicator of liver damage which was significantly decreased by RG and silymarin. Therefore, this reversal of serum markers by Rohitaka ghrita (3.6 and 7.2 g kg⁻¹) over PCM intoxication may confirm its efficacy as an anti-hepatotoxic agent.

The paracetamol induced free radicals generation is reported to cause membrane lipid peroxidation

(Jollow *et al.*, 1973), depletion of hepatic glutathione and peroxisomal catalase (Knight *et al.*, 2002) leading cell death (Jaeschke *et al.*, 2003) as featured in present study. However, the study quotes that the treatment with RG, 2RG and silymarin markedly restored the antioxidant defense system by increasing the level of glutathione, catalase and by lowering lipid peroxidation whereas vehicle control showed no effect. Further, the induction of mitochondrial dysfunction is well documented with hepatotoxic effects of PCM (Burcham and Harman, 1990) which are caused due to Mitochondrial Permeability Transition (MPT) (Reid *et al.*, 2005) and impaired membrane function as evidenced with decreased Na⁺K⁺ATPase activity (Kulkarni *et al.*, 2002) in present study. This finally facilitates certain necrotic, apoptotic and fibrotic cascades of hepatocellular injury (Parmar *et al.*, 1995; El-Hassan *et al.*, 2003). However, in the study, pretreatment with RG and silymarin showed potentiation of mitochondrial viability in comparison to PCM group as indicated by increased Na⁺K⁺ATPase activity probably by restoration of cell homeostasis.

Moreover, there was prominent attenuation of PCM induced toxic histological changes in liver observed in the group receiving RG (3.6 g kg⁻¹) as evidenced by impaired cell infiltration, vacuolization and central vein dilation. Moderate decrease was observed in 2RG (7.2 g kg⁻¹) and less in vehicle administered groups. Based on the restorative histological changes, it may be suggested that Rohitaka ghrita (3.6 g kg⁻¹) is having a good hepatoprotective activity.

CONCLUSION

The above expressions might postulated that Rohitaka ghrita: An ayurvedic formulation is having a significant hepatoprotective potential against paracetamol intoxication in rat liver by lowering oxidative cell damage and restoration of mitochondrial membrane function. Thus, the present study provides a scientific rationale for its traditional and commercial uses in management of liver diseases.

ACKNOWLEDGMENTS

This study was achieved with the support of Department of Pharmacology, Gujarat Ayurved University, Jamnagar, Gujarat; and also by ISF College of Pharmacy, Moga, Punjab, India. A special thanks to Prof. M.G. Chauhan, Gujarat Ayurved University, Jamnagar and late Shri Dr. Vachchrajani, CCRAS, Jamnagar, India.

REFERENCES

- Abdullah, N., N.Z.M. Saat, H.A. Hasan, S.B. Budin and S. Kamaralzaman, 2004. Protective effect of the ethanol extract of *Zingiber officinale* roscoe on paracetamol induced hepatotoxicity in rats. *J. Sains Kesihatan Malaysia*, 2: 85-95.
- Azam, M.M.E., P. Singh and A. Ghanim, 1997. Triacantanol and Triterpenes from *Tecomella undulata*. In: *World Forestry Congress*, A.K. Mukherjee (Ed.). Central Arid Zone Research Institute, Jodhpur, pp: 29-33.
- Bonting, S.L., 1970. Sodium-Potassium Activated Adenosine Triphosphatase and Cation Transport. In: *Membranes and Ion Transport*, Bittar, E.E. (Ed.), Wiley Interscience, England, pp: 257-363.
- Burcham, P.C. and A.W. Harman, 1990. Mitochondrial dysfunction in paracetamol hepatotoxicity: In vitro studies in isolated mouse hepatocytes. *Toxicol. Lett.*, 50: 37-48.
- El-Hassan, H., K. Anwar, P. Macanas-Pirard, M. Crabtree and S.C. Chow *et al.*, 2003. Involvement of mitochondria in acetaminophen induced apoptosis and hepatic injury: Roles of cytochrome c, Bax, Bid and caspases. *Toxicol. Appl. Pharmacol.*, 191: 118-129.
- Ellman, G.L., 1959. Tissue sulphhydryl groups. *Arch. Biochem. Biophys.*, 82: 70-77.
- Jaeschke, H., T.R. Knight and M.L. Bajt, 2003. The role of oxidant stress and reactive nitrogen species in acetaminophen hepatotoxicity. *Toxicol. Lett.*, 144: 279-288.
- Jalalpure, S.S., M.B. Patil, N.S. Prakash, K. Hemalata and F.V. Manvi, 2003. Hepatoprotective activity of the fruits of *Piper longum* Linn. *Indian J. Pharm. Sci.*, 65: 362-366.
- Jollow, D.J., J.R. Mitchell, W.Z. Potter, D.C. Davis, J.R. Gillette and B.B. Brodie, 1973. Acetaminophen induced hepatic necrosis. II. Role of covalent binding in vivo. *J. Pharmacol. Exp. Ther.*, 187: 195-202.
- Khatrri, A., A. Garg and S.S. Agrawal, 2009. Evaluation of hepatoprotective activity of aerial parts of *Tephrosia purpurea* L. and stem bark of *Tecomella undulata*. *J. Ethnopharmacol.*, 122: 1-5.
- Knight, T.R., Y.S. Ho, A. Farhood and H. Jaeschke, 2002. Peroxynitrite is a critical mediator of acetaminophen hepatotoxicity in murine livers: Protection by glutathione. *J. Pharmacol. Exp. Ther.*, 303: 468-475.
- Koul, I.B. and A. Kapil, 1993. Evaluation of the liver protective potential of piperine, An active principle of black and long peppers. *Planta Med.*, 59: 413-417.

- Kulkarni, K.S., M.D. Rafiq, S. Gopumadhavan, M.V. Venkataranganna, B.G. Madhumathi and S.K. Mitra, 2002. Protective effect of Liv.52 on Na⁺-K⁺-ATPase activity in paracetamol-induced hepatotoxicity. *Med. Update*, 5: 53-56.
- Lewis, J.H., M. Ahmed, A. Shobassy and C. Palese, 2006. Drug-induced liver disease. *Curr. Opin. Gastroenterol.*, 22: 223-233.
- Lowry, O.H., N.J. Rosebrough, A.L. Farr and R.J. Randall, 1951. Protein measurement with folin phenol reagent. *J. Biol. Chem.*, 193: 265-275.
- Matsuda, H., K. Ninomiya, T. Morikawa, D. Yasuda, I. Yamaguchi and M. Yoshikawa, 2008. Protective effects of amide constituents from the fruit of *Piper chaba* on D-galactosamine/TNF- α -induced cell death in mouse hepatocytes. *Bioorg. Med. Chem. Lett.*, 18: 2038-2042.
- Nelson, S.D., 1990. Molecular mechanisms of the hepatotoxicity caused by acetaminophen. *Semin. Liver Dis.*, 10: 267-278.
- Ohkawa, H., N. Ohishi and K. Yagi, 1979. Assay for lipid peroxides in animal tissues by thiobarbituric acid reaction. *Anal. Biochem.*, 95: 351-358.
- Pamar, D.V., G. Ahmed, M.A. Khandkar and S.S. Katyare, 1995. Mitochondrial ATPase: A target for paracetamol induced hepatotoxicity. *Eur. J. Pharmacol.*, 293: 225-229.
- Porchezian, E. and S.H. Ansari, 2005. Hepatoprotective activity of *Abutilon indicum* on experimental liver damage in rats. *Phytomedicine*, 12: 62-64.
- Rana, M.G., R.V. Katbamna, A.V. Dudhrejiya and N.R. Sheth, 2008. Hepatoprotection of *Tecomella undulata* against experimentally induced liver injury in rats. *Pharmacology online*, 3: 674-682.
- Reid, A.B., R.C. Kurten, S.S. McCullough, R.W. Brock and J.A. Hinson, 2005. Mechanisms of acetaminophen-induced hepatotoxicity: Role of oxidative stress and mitochondrial permeability transition in freshly isolated mouse hepatocytes. *J. Pharmacol. Exp. Ther.*, 312: 509-516.
- Shen, X., Y. Tang, R. Yang, L. Yu, T. Fang and J.A. Duan, 2009. The protective effect of *Zizyphus jujuba* fruit on carbon tetrachloride-induced hepatic injury in mice by anti-oxidative activities. *J. Ethnopharmacol.*, 122: 555-560.
- Sinha, A.K., 1972. Colorimetric assay of catalase. *Anal. Biochem.*, 47: 389-394.
- Tilak, J.C., S. Adhikari and T.P. Devasagayam, 2004. Antioxidant properties of *Plumbago zeylanica*, an Indian medicinal plant and its active ingredient plumbagin. *Redox Rep.*, 9: 219-227.
- Verma, K.S., A.K. Jain and S.R. Gupta, 1986. Structure of undulating: A new iridoid glucosides from *Tecomella undulate*. *Planta Med.*, 5: 359-362.