

Pegylated Interferon Versus Standard Interferon and Silymarin in Treatment of Liver Fibrosis Induced by Chronic Carbon Tetrachloride in Rats

¹Rasha E. Mostafa, ²Hala F. Zaki, ¹Amany A. Sleem, ³Omar M. Abdel-Salam, ⁴Fatma A. Morsy and ²Sanaa A. Kenawy

¹Pharmacology, National Research Centre, Tahrir St., Dokki, Cairo, Egypt

²Pharmacology and Toxicology, Faculty of Pharmacy, Cairo University, Cairo, Egypt

³Toxicology and Narcotics and ⁴Pathology, National Research Centre, Tahrir St., Dokki, Cairo, Egypt

ABSTRACT

The study aimed to investigate the effect of pegylated interferon alpha (Peg IFN α 2a), standard interferon alpha (Std IFN α 2a) and silymarin in liver fibrosis induced in rats by chronic treatment with carbon tetrachloride (CCl₄). Rats were divided into 9 groups (n = 7 per group). Group 1 received olive oil (0.5 mL kg⁻¹, p.o. twice weekly) for 8 weeks followed by saline for 4 weeks (normal control). The remaining 8 groups received CCl₄ (0.5 mL kg⁻¹, p.o.) twice weekly for 8 weeks, followed by saline (CCl₄ control), Std. IFN α 2a (1.5 or 3 MIU kg⁻¹, s.c., 3 times per week), Peg IFN α 2a (1 or 2 μ g kg⁻¹, s.c., once per week), silymarin (100 mg kg⁻¹ day⁻¹, p.o.) alone or combined with either Peg IFN α 2a (1 μ g kg⁻¹) or Std. IFN α 2a (1.5 MIU kg⁻¹), respectively for 4 weeks. At the end of the experiment, blood samples were collected and livers were isolated for biochemical and histological assessment of markers related to liver fibrosis. Administration of CCl₄ resulted in increases in liver function tests, liver lipid peroxides and hydroxyproline contents coupled with decrease in total protein and liver content of reduced glutathione. Administration of Peg IFN α 2a or silymarin alone or combined together attenuated CCl₄-induced changes. On the other hand, using Std. IFN was not coupled by significant improvement in CCl₄-induced changes, an effect that was reversed by its combination with silymarin. In conclusion, administration of Peg IFN, silymarin or their combination can limit hepatocellular fibrosis caused by chronic CCl₄ administration; whereas, the effects of Std. IFN are only evident when combined with silymarin.

Key words: Pegylated interferon alpha, standard interferon alpha, silymarin, carbon tetrachloride, liver fibrosis

Pharmacologia 4 (3): 208-217, 2013

INTRODUCTION

Liver fibrosis is the final pathological outcome for the majority of chronic liver insults, which may progress to liver cirrhosis and liver carcinoma if not reversed¹. CCl₄ is one of the most widely used toxins for experimental induction of liver fibrosis in laboratory animals². This model primarily provides insights into the fibrotic process. The relative ease of induction and the reproducibility of the model account for its popularity³. There is no standard treatment for liver fibrosis. Although, experimental studies have revealed targets to prevent fibrosis progression in rodents, the efficacy of most treatments was not proven in humans⁴. Interferons (IFNs) are proteins made and released

by host cells in response to the presence of pathogens such as viruses, bacteria, parasites or tumor cells⁵. Interferon on-alpha (IFN- α) is the hallmark of treatment in viral hepatitis. Moreover, it was reported that the antifibrotic effects of IFN- α in rats and patients with hepatitis C virus (HCV) are independent on its antiviral activity, i.e., it reduces the degree of fibrosis even when there is no sufficient antiviral response. In addition, IFN- α decreases the production of Reactive Oxygen Species (ROS) in stimulated hepatocytes and inhibits oxidative stress in patients with HCV infection⁶. Pegylating of standard IFN α -2a (Std. IFN α 2a) was performed by F. Hoffmann-La Roche Ltd., in collaboration with Shearwater Corporation; Basel Switzerland. Pegylation optimized the pharmacological activity of the protein such that efficacy is enhanced, adverse effects minimized and patient compliance and quality of life are improved⁷. Silymarin, a natural product prepared from the milk

Corresponding Author: Rasha E. Mostafa, Department of Pharmacology, Medical Division, National Research Centre, Cairo, Egypt, El-Bohoth St., Dokki, Giza, 12622, Egypt Tel/Fax: +202-33335996/+2-01284547833/+966-567547873/+202-33370931

a radical-scavenger and hepatoprotectant⁸. Silymarin also decreases lipid peroxidation and inhibits fibrogenesis in animal models⁹. Although, traditionally reviewed as irreversible, reversibility of liver fibrosis has lately been described^{10,11}. Therefore, the present study was designed to investigate and compare the antifibrotic effects of Std. IFN, pegylated interferon (Peg IFN) or silymarin in treatment of liver fibrosis induced by CCl₄ administration in rats. The study also aimed to see whether combined therapy with silymarin and Std. IFN or Peg IFN would offer any potential advantage over therapy with either of the two drugs alone. The effect of test drugs was evaluated based on biochemical markers associated with liver fibrosis as well as histopathological examination of liver tissues.

MATERIALS AND METHODS

Animals: Sprague-Dawley rats, weighing 130-150 g body weight were used. They were housed under standard laboratory conditions with free access to standard laboratory chow and water. All animal procedures were performed according to approved protocols for the proper care and use of laboratory animals adopted by the Ethics Committee, Faculty of Pharmacy, Cairo University.

Drugs and chemicals: CCl₄ (Egyptian Co. for chemicals and pharmaceuticals (ADWIA), Egypt), Peg IFN α 2a (Pegasys[®], 180 μ g 0.5 mL injection solution; Hoffmann-La Roche Inc., New Jersey, USA), Std. IFN α 2a (Roferon-A[®], 3 million IU/0.5 mL injection solution; Hoffmann-La Roche Inc., New Jersey, USA) and silymarin (Legalon[®], 70 mg sugar-coated tablets; Madaus GmbH, Köln Germany) were used in the present experiments. Drugs were dissolved in saline to obtain the necessary doses. The doses of Peg IFN, Std. IFN and silymarin were chosen from published literature based on their beneficial effects in models of hepatic injury^{12,13,14}.

Induction of liver fibrosis: Liver fibrosis was induced by CCl₄ dissolved in olive oil (1:1) and given orally in a dose of 0.5 mL kg⁻¹, twice weekly for 8 successive weeks².

Experimental design: After induction of liver fibrosis, rats were randomly allocated in 8 groups (n = 7) and drug administration was started. Rats received saline (CCl₄ control), Std. IFN α 2a (1.5 or 3 MIU kg⁻¹, s.c., 3 times per week), Peg IFN α 2a (1 or 2 μ g kg⁻¹, s.c., once per week), silymarin (100 mg kg⁻¹ day⁻¹, p.o.) alone or combined with either Std. IFN α 2a (1.5 MIU kg⁻¹) or Peg IFN α 2a (1 μ g kg⁻¹), respectively for 4 weeks. Normal control rats were treated with olive oil

(0.5 mL kg⁻¹; twice weekly for 8 weeks) followed by saline for the remaining 4 weeks. By the end of the 12th week, blood samples were collected from the retro-orbital vein plexuses under light ether anesthesia and centrifuged at 3000 rpm for serum separation. Rats were sacrificed and livers were isolated. Part of the liver was preserved in 10% formalin for histological examination and the other part homogenized in ice-cold 0.9% w/v saline to prepare 10% homogenates.

Serum samples were analyzed for Alanine Amino Transferase (ALT), Aspartate Amino Transferase (AST) and Alkaline Phosphatase (ALP) activities as well as levels of total bilirubin and total protein. Liver homogenates were used for determination of liver contents of lipid peroxides, measured as malondialdehyde (MDA), Nitric Oxide (NO) metabolites, reduced glutathione (GSH) and hydroxyproline.

Biochemical measurements: ALT and AST activities in serum were measured according to the method of Reitman *et al.*¹⁵ using commercially available kits (Quimica Clinica Aplicada, Spain).

Colorimetric determination of ALP activity was done according to the method of Jusman and Halim¹⁶ using commercially available kits (Quimica Clinica Aplicada, Spain).

Serum levels of total bilirubin and protein were measured according to the methods described by Walters and Gerade¹⁷ and Gornall *et al.*¹⁸, respectively using commercially available kits (Biodiagnostic, Egypt). Liver contents of MDA and NO metabolites were measured according to the methods adopted by Ruiz-Larrea *et al.*¹⁹ and Miranda *et al.*²⁰, respectively. Liver GSH content was measured according to the method by Ellman²¹ and modified by Bulaj *et al.*²², while that of hydroxyproline was done according to the method of Woessner²³.

Histological studies: Specimens from the three major lobes of each liver were fixed in 10% buffered formalin. Paraffin sections 5 μ thick were prepared and stained with hematoxylin and eosin (Hx. and E.) for the histological investigations under electron microscope. photoshop version 7.0.1 was used for photo capturing.

Statistical analysis: All results are expressed as Means \pm SE. Multiple group comparisons were performed by analysis of variance (ANOVA) followed by Tukey's multiple comparisons post hoc test. p < 0.05 was considered statistically significant. Statistical analysis of results was done using GraphPad prism, version 5.00.

RESULTS

Effects of test agents on CCl₄-induced changes in liver function tests: Administration of CCl₄ was associated with marked increase in serum ALT, AST and

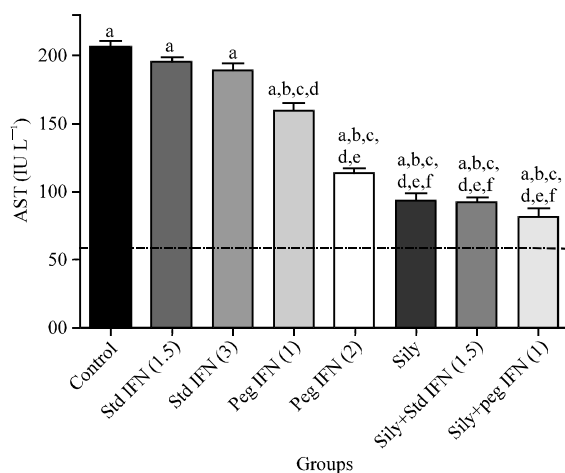


Fig. 1: Effect of 4 weeks administration of standard interferon, pegylated interferon and silymarin alone or combined with either Std. or peg IFN on serum aspartate transaminase activity, Normal rats (dotted line) received 0.2 mL olive oil p.o., daily, *Significantly different from normal rats, at $p < 0.05$, ^bSignificantly different from control group, at $p < 0.05$, ^cSignificantly different from Std. IFN 1.5 group at $p < 0.05$, ^dSignificantly different from Std. IFN 3 group at $p < 0.05$, ^eSignificantly different from Peg IFN 1 group at $p < 0.05$, ^fSignificantly different from Peg IFN 2 group at $p < 0.05$

ALP activities as well as total bilirubin level by 289, 262, 116 and 290%, respectively as compared to normal control group. Moreover, a marked decrease in serum total protein level by 40% was observed (Fig. 1-5).

Administration of Std. IFN in CCl_4 -treated rats did not significantly change CCl_4 -induced changes in liver function tests when compared to CCl_4 control rats. Meanwhile; administration of peg INF (1 or 2 $\mu\text{g kg}^{-1}$) in CCl_4 -treated rats resulted in 22.7-44.8% decrease in AST activity, 24.7-43.7% decrease in ALT activity, 25.4-32.2% decrease in ALP activity, 20-29.4% decrease in total bilirubin level and 26.3-27.9% increase in total proteins level, respectively when compared with CCl_4 control group (Fig. 1-5).

Administration of silymarin (100 mg kg^{-1}) in CCl_4 -treated rats resulted in a decrease in AST, ALT and ALP activities as well as total bilirubin level by 54.6, 51.3, 37.7 and 38.1%, respectively parallel to 29.6% increase in total proteins when compared with the CCl_4 control group (Fig. 1-5).

Moreover, administration of silymarin combined with either Std. IFN (1.5 MIU kg^{-1}) or Peg IFN (1 $\mu\text{g kg}^{-1}$) resulted in 55-60.2% decrease in AST

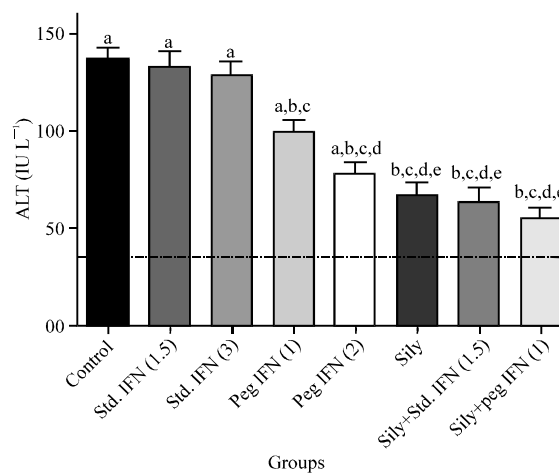


Fig. 2: Effect of 4 weeks administration of standard interferon, pegylated interferon and silymarin alone or combined with either Std. or Peg IFN on serum alanine transaminase activity, Normal rats (dotted line) received 0.2 mL olive oil p.o., daily, *Significantly different from normal rats, at $p < 0.05$, ^bSignificantly different from control group, at $p < 0.05$, ^cSignificantly different from Std. IFN 1.5 group at $p < 0.05$, ^dSignificantly different from Std. IFN 3 group at $p < 0.05$, ^eSignificantly different from Peg IFN 1 group at $p < 0.05$

activity, 54-60.3% decrease in ALT activity, 39.4-47.9% decrease in ALP activity, 41.2-44.4% decrease in total bilirubin and 29.7-32.5% increase in total proteins, respectively when compared with the CCl_4 control group (Fig. 1-5).

Effect of test agents on CCl_4 -induced changes in liver contents of hydroxyproline, nitric oxide metabolites, lipid peroxides and reduced glutathione: Administration of CCl_4 was associated with marked increase in liver content of hydroxyproline, NO metabolites and liver lipid peroxides (MDA) by 394, 97 and 244%, respectively as compared to normal control group. Moreover, a marked decrease in liver content of reduced glutathione (GSH) by 72% of the normal level (Fig. 6-9).

Administration of Std. IFN in CCl_4 -treated rats at 1.5 or 3 MIU kg^{-1} did not significantly change CCl_4 -induced changes in liver content of hydroxyproline, NO metabolites or GSH when compared to CCl_4 control rats, while Std. IFN 3 MIU kg^{-1} resulted in 22.3% decrease in liver content of MDA (Fig. 6-9). Meanwhile; administration of Peg IFN (1 or 2 $\mu\text{g kg}^{-1}$) in CCl_4 -treated rats resulted in 18.2-32.2% decrease in liver hydroxyproline content,

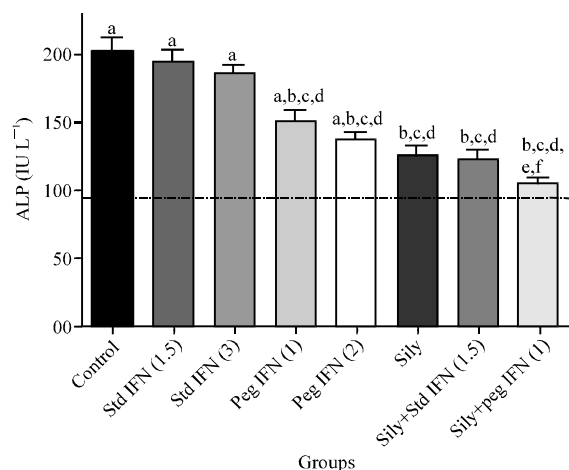


Fig. 3: Effect of 4 weeks administration of standard interferon, pegylated interferon and silymarin alone or combined with either Std. IFN or peg IFN on serum alkaline phosphatase (ALP) activity, Normal rats (dotted line) received 0.2 mL olive oil p.o., daily, ^aSignificantly different from normal rats, at $p < 0.05$, ^bSignificantly different from control group, at $p < 0.05$, ^cSignificantly different from Std. IFN 1.5 group at $p < 0.05$, ^dSignificantly different from Std. IFN 3 group at $p < 0.05$, ^eSignificantly different from Peg IFN 1 group at $p < 0.05$, ^fSignificantly different from Peg IFN 2 group at $p < 0.05$

18.9-28.2% decrease in liver NO metabolites, 32.3-44.8% decrease in MDA and 40.6-51.7% increase in GSH, respectively when compared with CCl₄ control group (Fig. 6-9).

Administration of silymarin (100 mg kg⁻¹) in CCl₄-treated rats resulted in a decrease in liver content of hydroxyproline, NO metabolites and MDA by 46.6, 36.2 and 54%, respectively parallel to 55.8% increase in GSH when compared with the CCl₄ control group (Fig. 6-9).

Moreover, administration of silymarin combined with either Std. IFN (1.5 MIU kg⁻¹) or Peg IFN (1 μg kg⁻¹) resulted in 47.6-57.1% decrease in liver hydroxyproline content, 38.4-43.6% decrease in NO metabolites, 55.7-60.7% decrease in MDA and 56.3-59.7% increase in GSH, respectively when compared with the CCl₄ control group (Fig. 6-9).

Histological results: The liver of normal control rats revealed the normal characteristic hepatic architecture being composed of plates of hepatocytes radiating from a central vein. These plates are separated from each other by blood sinusoids of nearly equal size (Fig. 10a).

The livers of control CCl₄ group showed vacuolar degeneration, dilated, congested portal vein, dilated bile

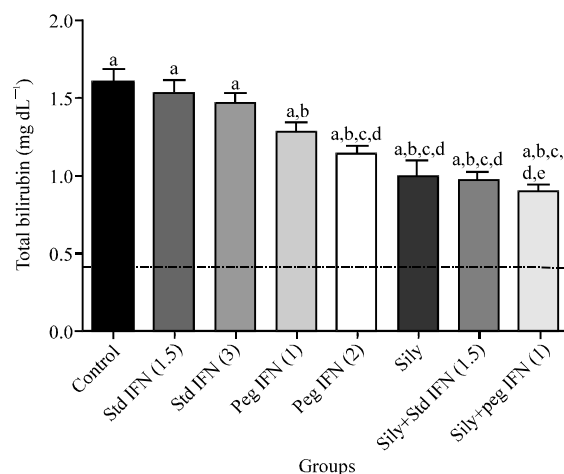


Fig. 4: Effect of 4 weeks administration of standard interferon, pegylated interferon and silymarin alone or combined with either Std. IFN or peg IFN on serum total bilirubin level, Normal rats (dotted line) received 0.2 mL olive oil p.o., daily, ^aSignificantly different from normal rats, at $p < 0.05$, ^bSignificantly different from control group, at $p < 0.05$, ^cSignificantly different from Std. IFN 1.5 group at $p < 0.05$, ^dSignificantly different from Std. IFN 3 group at $p < 0.05$, ^eSignificantly different from Peg IFN 1 group at $p < 0.05$

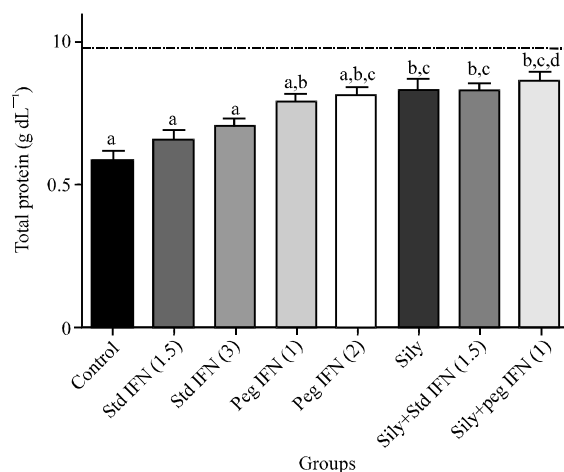


Fig. 5: Effect of 4 weeks administration of standard interferon, pegylated interferon and silymarin alone or combined with either std. IFN or peg IFN on serum total protein level, Normal rats (dotted line) received 0.2 mL olive oil p.o., daily, ^aSignificantly different from normal rats, at $p < 0.05$, ^bSignificantly different from control group, at $p < 0.05$, ^cSignificantly different from Std. IFN 1.5 group at $p < 0.05$, ^dSignificantly different from Std. IFN 3 group at $p < 0.05$

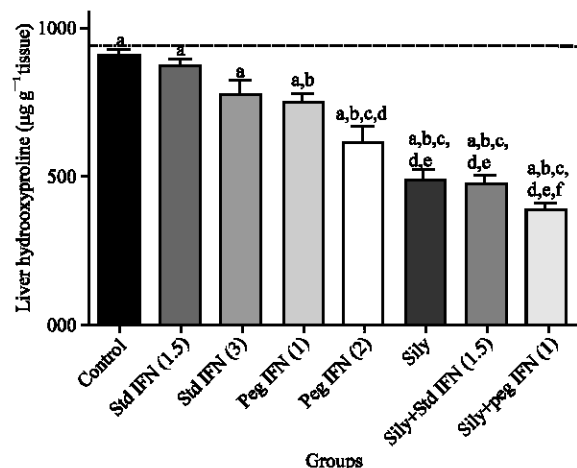


Fig. 6: Effect of 4 weeks administration of standard interferon, pegylated interferon and silymarin alone or combined with either std. IFN or peg IFN on liver hydroxyproline content, Normal rats (dotted line) received 0.2 mL olive oil p.o., daily, ^aSignificantly different from normal rats, at $p < 0.05$, ^bSignificantly different from control group, at $p < 0.05$, ^cSignificantly different from Std. IFN 1.5 group at $p < 0.05$, ^dSignificantly different from Std. IFN 3 group at $p < 0.05$, ^eSignificantly different from Peg IFN 1 group at $p < 0.05$, ^fSignificantly different from Peg IFN 2 group at $p < 0.05$

duct, congested blood vessel in blood sinusoid and architecture distortion together with the appearance of many pseudolobules, edema, mononuclear cellular infiltration and marked fibrosis (Fig. 10b).

In rats treated with CCl₄ followed by Std. IFN (1.5 MIU kg⁻¹), examination of liver sections revealed no protective effects as compared to control CCl₄ group, since fibrosis was not improved (Fig. 10c), while treatment with CCl₄ together with Std. IFN (3 MIU kg⁻¹) revealed minor improvement in pathological changes in the form of moderate fibrosis and absence of many pseudolobules (Fig. 10d).

Examination of liver sections from rats treated with CCl₄ followed by Peg IFN (1 or 2 µg kg⁻¹) revealed dilated, congested portal vein, dilated bile duct, cellular infiltration and cloudy swelling. Improvement in pathological changes was observed in the form of minimal fibrosis and absence of many pseudolobules (Fig. 10e,f).

Liver sections of rats treated with CCl₄ followed by silymarin (100 mg kg⁻¹) showed minimal fibrosis and signs of degeneration in the form of karyolysis (Fig. 10g).

On the other hand, liver sections of rats treated with CCl₄ followed by silymarin combined with Std. IFN (1.5 MIU kg⁻¹) or Peg IFN (1 µg kg⁻¹) revealed marked

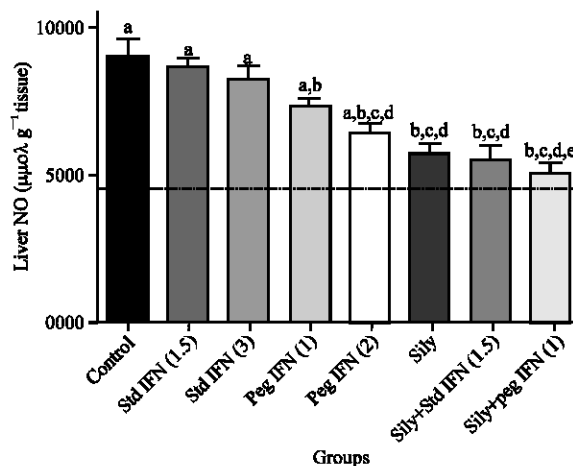


Fig. 7: Effect of 4 weeks administration of standard interferon, pegylated interferon and silymarin alone or combined with either Std. IFN or peg IFN on liver content of Nitric Oxide (NO) metabolites, Normal rats (dotted line) received 0.2 mL olive oil p.o., daily, ^aSignificantly different from normal rats, at $p < 0.05$, ^bSignificantly different from control group, at $p < 0.05$, ^cSignificantly different from Std. IFN 1.5 group at $p < 0.05$, ^dSignificantly different from Std. IFN 3 group at $p < 0.05$, ^eSignificantly different from Peg IFN 1 group at $p < 0.05$

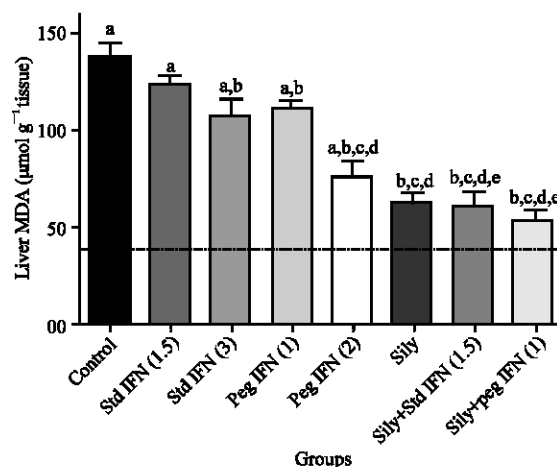


Fig. 8: Effect of 4 weeks administration of standard interferon, pegylated interferon and silymarin alone or combined with either Std. IFN or peg IFN on liver lipid peroxides (MDA), Normal rats (dotted line) received 0.2 mL olive oil p.o., daily, ^aSignificantly different from normal rats, at $p < 0.05$, ^bSignificantly different from control group, at $p < 0.05$, ^cSignificantly different from Std. IFN 1.5 group at $p < 0.05$, ^dSignificantly different from Std. IFN 3 group at $p < 0.05$, ^eSignificantly different from Peg IFN 1 group at $p < 0.05$

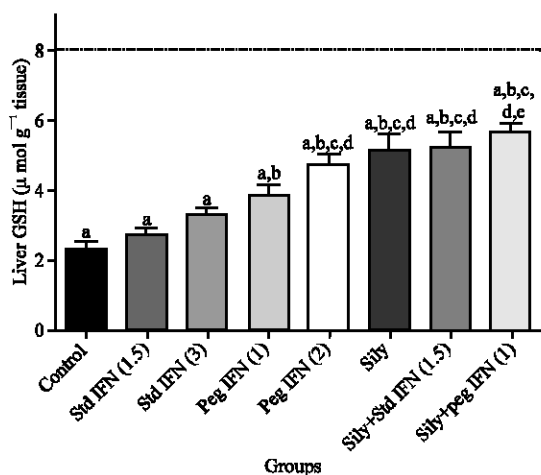


Fig. 9: Effect of 4 weeks administration of standard interferon, pegylated interferon and silymarin alone or combined with either Std. IFN or peg IFN on liver reduced glutathione (GSH), Normal rats (dotted line) received 0.2 ml olive oil p.o., daily, ^aSignificantly different from normal rats, at $p < 0.05$, ^bSignificantly different from control group, at $p < 0.05$, ^cSignificantly different from Std. IFN 1.5 group at $p < 0.05$, ^dSignificantly different from Std. IFN 3 group at $p < 0.05$, ^eSignificantly different from Peg IFN 1 group at $p < 0.05$

improvement in pathological outcome where fibrosis couldn't be observed, however, hepatocytes with variable size and signs of degeneration in the form of pyknosis and karyolysis were still seen (Fig. 10h,i).

DISCUSSION

In the present study, treatment of rats with CCl_4 for 8 weeks induced marked fibrosis and architectural distortion. Oral administration of CCl_4 twice weekly for 8 weeks resulted in significant increase in serum AST, ALT and ALP activities as well as total bilirubin level and a significant decrease in serum total protein level, more over a significant decrease in liver tissue content of GSH and a significant increase in liver contents of MDA, NO metabolites and hydroxyproline as compared to control group. The observed changes were previously reported in other studies^{24,25,26,27}. The increased activities of ALT and AST may be attributed to the damaged structural integrity of the liver. The increased activity of ALP gives an indication of damage in the bile duct. Increased serum total bilirubin is a signal of hepatocellular damage and decreased liver clearance. On the other hand, the liver is responsible for the synthesis of total proteins and their marked decrease in the serum indicates severe liver

damage²⁸. GSH is an important endogenous antioxidant which can scavenge Reactive Oxygen Species (ROS). Reaction of ROS with lipid membrane will cause lipid peroxidation. MDA is the end product of lipid peroxidation and its concentration in liver tissue will increase markedly in OS and liver fibrosis²⁹. The formation of NO increases in liver disease, where the L-arginine-NO pathway is activated³⁰. Hydroxyproline is found in few proteins other than collagen and for this reason; its content has been used as an indicator to determine collagen amount and therefore, fibrosis³¹.

The present study provides evidence that in a model of hepatic injury and fibrosis caused by chronic administration of CCl_4 in rats, Std. IFN $\alpha 2a$ failed to decrease the elevated serum AST, ALT and ALP activities, total bilirubin level and failed to increase the reduced serum protein level. Std. IFN also failed to decrease the elevated liver MDA, NO metabolites and hydroxyproline contents and failed to increase the decreased liver GSH content. Histopathological investigation of the liver tissues from rats treated with Std. IFN didn't show any improvement of the pathological outcome. Contradictory results about the antifibrotic efficacy of IFN- α in some liver fibrosis models have been reported. Some studies have shown INFs as ineffective³², others found it effective^{33,34}, while others observed a weak but significant reduction in liver fibrosis³⁵. The current results are in good agreement with Tarcin *et al.*³², who found no statistically significant recovery or even a change in collagen turnover rate in rats treated with Std. INF $\alpha 2a$ and that IFN-alpha has no beneficial effect on experimental fibrosis.

On the other hand, the present study provides evidence that in a model of hepatic injury and fibrosis caused by chronic administration of CCl_4 in rats, Peg IFN $\alpha 2a$ decreased leakage of hepatocellular enzymes ALT, AST and ALP into plasma and lessened the development of hepatic fibrosis necrosis and fibrosis caused by CCl_4 . Cellular dysfunction induced by CCl_4 and evidenced by reduced serum protein and elevated serum total bilirubin content were largely prevented by the Peg IFN $\alpha 2a$. Similar findings were observed on treatment with silymarin. These findings indicate that both Peg IFN $\alpha 2a$ and silymarin limit hepatocellular injury and exert antifibrotic effect. A benefit from combining either Std. IFN or Peg IFN and silymarin was also observed. The histochemical investigation showed that Peg IFN, silymarin alone or in combination with either Std. IFN or Peg IFN reduced the elevated liver MDA, NO metabolites and hydroxyproline content and elevated the decreased liver GSH content. Histopathological investigation of the liver tissues from rats treated with peg IFN, silymarin alone or in combination with Std. IFN revealed improvement of the

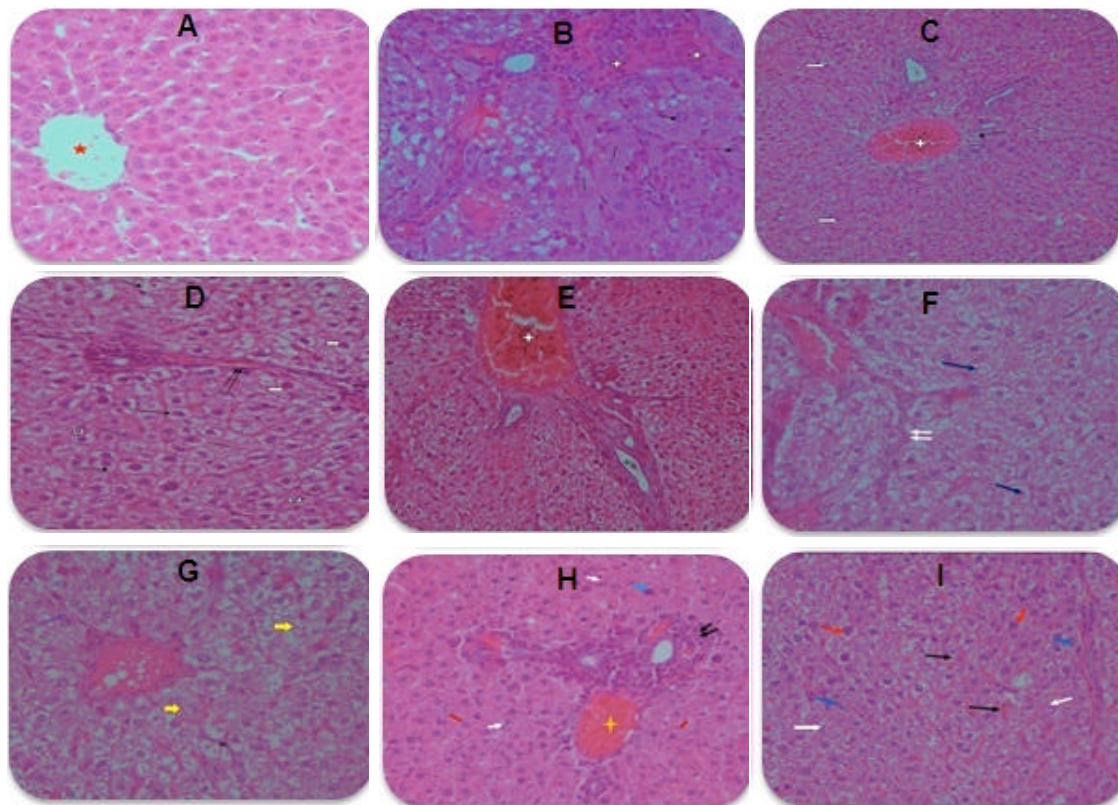


Fig. 10(a-i): A photomicrograph of a section of liver tissue from: (a): Normal rat showing normal structure of liver being composed of plates of cells (hepatocytes) radiating from a central vein (star) (Hx. and E. $\times 400$), (b): Control CCl_4 -treated rat showing coagulated necrosis (star), swelling of some hepatocyte (arrow) and karyolysis (line) (Hx. and E. $\times 400$), (c): Rat treated with Std. IFN (1.5 MIU kg^{-1}) showing dilated, congested portal vein and cellular infiltration around (star), in addition to minute vacuolar degeneration (white arrow), focal necrosis (line) and congested blood vessel in blood sinusoid (double arrows) (Hx. and E. $\times 100$), (d): Rat treated with Std. IFN (3 MIU kg^{-1}) showing massive vacuolar degeneration (arrow), focal necrosis (line) and signs of degeneration in the form of karyolysis (black arrow) and pyknosis (white arrow) (Hx. and E. $\times 400$), (e): Rat treated with Peg IFN ($1 \mu\text{g kg}^{-1}$) showing dilated, congested portal vein (star), dilated bile duct (2 stars) and cellular infiltration (star). Cloudy swelling (double arrows) could be also noticed (Hx. and E. $\times 200$), (f): Rat treated with Peg IFN ($2 \mu\text{g kg}^{-1}$) showing necrotic foci (arrow), signs of degeneration in the form of karyolysis (white arrow), Improvement in pathological changes was observed in the form of minimal fibrosis (double arrows) (Hx. and E. $\times 400$), (g): Rat treated with silymarin (100 mg kg^{-1}) showing karyolysis and focal necrosis (arrow head), Minimal fibrosis (arrow) was observed (Hx. and E. $\times 400$), (h): Rat treated with silymarin and Std. IFN (1.5 MIU kg^{-1}) showing hepatocytes with variable size, hyperchromasia of some hepatocytes (arrow), karyolysis (line) as well as dilatation and congestion of portal vein (star), Cellular infiltration around the bile duct was observed (double arrows), Fibrosis could not be observed. (Hx. and E. $\times 400$), (i): Rat treated with silymarin and Peg IFN ($1 \mu\text{g kg}^{-1}$) showing congested blood vessel in dilated blood sinusoid (arrow) and signs of degeneration in the form of pyknosis (red arrow) and karyolysis (white arrow), Fibrosis could not be observed. (Hx. and E. $\times 200$)

pathological picture in the form of moderate to minimal fibrosis, while the pathological picture of liver tissues from rats treated with silymarin in combination with Peg IFN revealed no fibrosis.

Peg IFNs are generally superior to Std. IFNs. Peg IFNs have longer half-lives with more consistent serum levels therefore they require less frequent dosing which accounts for their higher tolerability due to weekly administration in comparison to thrice weekly administration in the case of Std. IFNs. Pegylation optimized the pharmacological activity of the protein such that efficacy is enhanced, adverse effects minimized and patient compliance and quality of life are improved³⁶.

Results reported by Canbakan *et al.*³⁶ were in partial agreement with the results of current study, where the use of Peg IFN α 2a (50 $\mu\text{g kg}^{-1}$; i.p.; once weekly; 4 weeks) improved the OS markers; MDA and GSH but failed to decrease the liver collagen content and thus failed to improve liver fibrosis either histologically or biochemically. Results reported by Tasci *et al.*² are also in partial agreement with the present study where they reported that Peg IFN α 2b (1.5 $\mu\text{g kg}^{-1}$; s.c.; once weekly; 4 weeks) significantly reduced fibrosis scores; decreased liver hydroxyproline content but was not able to decrease the OS biomarkers when compared to control group. Results of the present study are in good agreement with the results of Poynard *et al.*¹³, who reported that therapy with Peg IFN (1.5 $\mu\text{g kg}^{-1}$ per week) managed to cause better improvement in fibrosis progression even in patients without sustained virologic response than the Std. IFN α . Moreover, histopathological analysis of liver biopsy specimens showed some improvement in the degree of fibrosis after therapy, irrespective of the initial virological response. The present study is also in good agreement with Zeuzem *et al.*¹², who reported that a regimen of Peg IFN α 2a given once weekly is more effective than a regimen of IFN α 2a given 3 times weekly in both serum biochemical liver function tests and histological response.

The antioxidant property, the anti-inflammatory activities, membrane stabilizing, immunomodulatory, liver regenerating mechanisms and the antifibrotic actions are considered as most important actions of silymarin³⁷. The current results agree with many studies^{38,39,40}. Favari and Perez-Alvarez³⁸ stated that treatment with silymarin (50 mg kg^{-1}) in CCl₄ induced hepatotoxicity in rats has led to complete normalization of elevated transaminases. It also reduced liver collagen content by 55%. Abdel-Salam *et al.*³⁹ reported that the silymarin (22 mg kg^{-1}) decreased leakage of hepatocellular enzymes ALT and AST into plasma, decreased serum levels of ALP and lessened the development of liver necrosis and fibrosis caused by

CCl₄. Significant decrease in the area of fibrosis was also observed after treatment with silymarin. Cho *et al.*⁴⁰ reported that the elevated serum liver enzymes were significantly attenuated by chronic silymarin treatment. Silymarin also significantly decreased collagen deposition.

CONCLUSION

Hepatocellular injury and hepatic fibrosis evoked by the administration of CCl₄ for 8 weeks in rats was ameliorated by the administration of Peg IFN α 2a, silymarin and the co-administration of silymarin with either Std. IFN or Peg IFN. Furthermore, these effects were associated with an improvement in the pathological picture from liver tissues of rats treated with the aforementioned drugs. Peg IFN alone or in combination with silymarin is therefore, likely to be of benefit in reducing the likelihood of malignant transformation in patients with chronic liver disease.

ABBREVIATIONS

Pegylated interferon alpha (Peg IFN α 2a), Standard interferon alpha (Std. IFN α 2a), Carbon tetrachloride (CCl₄), Alanine aminotransferase (ALT), Aspartate aminotransferase (AST), Alkaline phosphatase (ALP), Malondialdehyde (MDA), Nitric oxide (NO), Reduced glutathione (GSH).

REFERENCES

- Oh, S.W., D.H. Kim, J.R. Ha and D.Y. Kim, 2009. Anti-fibrotic effects of a Methylenedioxybenzene compound CW209292 on dimethylnitrosamine-induced hepatic fibrosis in rats. *Biol. Pharm. Bull.*, 32: 1364-1370.
- Tasci, I., M.R. Mas, S.A. Vural, S. Devenci and B. Comert *et al.*, 2007. Pegylated interferon-alpha plus taurine in treatment of rat liver fibrosis. *World J. Gastroenterol.*, 13: 3237-3244.
- Tsukamoto, H., M. Matsuoka and S.W. French, 1990. Experimental models of hepatic fibrosis: A review. *Semin. Liver Dis.*, 10: 56-65.
- Bataller, R. and D.A. Brenner, 2001. Hepatic stellate cells as a target for the treatment of liver fibrosis. *Semin. Liver Dis.*, 21: 437-451.
- De Weerd, N.A., S.A. Samarajiwa and P.J. Hertzog, 2007. Type I interferon receptors: Biochemistry and biological functions. *J. Biol. Chem.*, 282: 20053-20057.
- Vendemiale, G., I. Grattagliano, M.L. Caruso, G. Serviddio, A.M. Valentini, M. Pirrelli and E. Altomare, 2001. Increased oxidative stress in dimethylnitrosamine-induced liver fibrosis in the rat: Effect of N-acetylcysteine and interferon- α : *Toxicol. Applied Pharmacol.*, 175: 130-139.

7. Reddy, K.R., M.W. Modi and S. Pedder, 2002. Use of peginterferon alfa-2a (40KD) (Pegasys) for the treatment of hepatitis C. *Adv. Drug Deliv. Rev.*, 54: 571-586.
8. Schuppan, D., A. Krebs, M. Bauer and E.G. Hahn, 2003. Hepatitis C and liver fibrosis. *Cell Death Differ.*, 10: S59-S67.
9. Pradhan, S.C. and C. Girish, 2006. Hepatoprotective herbal drug silymarin from experimental pharmacology to clinical medicine. *Indian J. Med. Res.*, 124: 491-504.
10. Iredale, J.P., R.C. Benyon, J. Pickering, M. McCullen and M. Northrop *et al.*, 1998. Mechanisms of spontaneous resolution of rat liver fibrosis. Hepatic stellate cell apoptosis and reduced hepatic expression of metalloproteinase inhibitors. *J. Clin. Invest.*, 102: 538-549.
11. Mas, M.R., B. Comert, K. Oncu, S.A. Vural and C. Akay *et al.*, 2004. The effect of taurine treatment on oxidative stress in experimental liver fibrosis. *Hepatol. Res.*, 28: 207-215.
12. Zeuzem, S., S.V. Feinman, J. Rasenack, E.J. Heathcote and M.Y. Lai *et al.*, 2000. Peginterferon alfa-2a in patients with chronic hepatitis C. *N. Engl. J. Med.*, 343: 1666-1672.
13. Poynard, T., J. McHutchison, M. Manns, C. Trepo and K. Lindsay *et al.*, 2002. Impact of pegylated interferon alfa-2b and ribavirin on liver fibrosis in patients with chronic hepatitis C. *Gastroenterology*, 122: 1303-1313.
14. Ahmed, A.F., M.F. Mahmoud, M.A. Ouf and E.A. El-Fathaah, 2011. Aminoguanidine potentiates the hepatoprotective effect of silymarin in CCL₄ treated rats. *Ann. Hepatol.*, 10: 207-215.
15. Reitman, S. and S. Frankel, 1957. A calorimetric method for the determination of serum glutamic oxalacetic and glutamic pyruvic transaminases. *Am. J. Clin. Pathol.*, 28: 56-63.
16. Belfield, A. and D.M. Goldberg, 1971. Revised assay for serum phenyl phosphatase activity using 4 amino antipyrine. *Enzyme*, 12: 561-573.
17. Walters, M.I. and R.W. Gerade, 1970. Total and direct bilirubin. *Microchem. J.*, 15: 231-231.
18. Gornall, A.G., C.J. Bardawill and M.M. David, 1949. Determination of serum proteins by means of biuret reaction. *J. Biol. Chem.*, 177: 751-766.
19. Ruiz-Larrea, M.B., A.M. Leal, M. Liza, M. Lacort and H. de Groot, 1994. Antioxidant effects of estradiol and 2-hydroxyestradiol on iron-induced lipid peroxidation of rat liver microsome. *Steroids*, 59: 383-388.
20. Miranda, K.M., M.G. Espey and D.A. Wink, 2001. A rapid, simple spectrophotometric method for simultaneous detection of nitrate and nitrite. *Nitric Oxide*, 5: 62-71.
21. Ellman, G.L., 1959. Tissue sulfhydryl groups. *Arch. Biochem. Biophys.*, 82: 70-77.
22. Bulaj, G., T. Kortemme and D.P. Goldenberg, 1998. Ionization-reactivity relationships for cysteine thiols in polypeptides. *Biochemistry*, 37: 8965-8972.
23. Woessner, J.F.J., 1961. The determination of hydroxyproline in tissue and protein samples. *Arch. Biochem. Biophys.*, 93: 440-447.
24. Gonzalez-Reimers, E., A. Lopez-Lirola, R.M. Olivera, F. Santolaria-Fernandez and L. Galindo-Martin *et al.*, 2003. Effects of protein deficiency on liver trace elements and antioxidant activity in carbon tetrachloride-induced liver cirrhosis. *Biological Trace Element Res.*, 93: 127-139.
25. Lee, J.Y., S.H. Lee, H.J. Kim, J.M. Ha, S.H. Lee, J.H. Lee and B.J. Ha, 2004. The preventive inhibition of chondroitin sulfate against the CCl₄-induced oxidative stress of subcellular level. *Arch. Pharmacol. Res.*, 27: 340-345.
26. Hong, R.T., J.M. Xu and Q. Mei, 2009. Melatonin ameliorates experimental hepatic fibrosis induced by carbon tetrachloride in rats. *World J. Gastroenterol.*, 15: 1452-1458.
27. Yang, F.R., B.W. Fang and J.S. Lou, 2010. Effects of haobie yangyin ruanjian decoction on hepatic fibrosis induced by carbon tetrachloride in rats. *World J. Gastroenterol.*, 16: 1458-1464.
28. Thapa, B.R. and A. Walia, 2007. Liver function tests and their interpretation. *Indian J. Pediatr.*, 74: 663-671.
29. Jusman, S.W.A. and S.A. Halim, 2009. Oxidative stress in liver tissue of rat induced by chronic systemic hypoxia. *Makara Kesehatan*, 13: 34-38.
30. Kirkali, G., S. Gezer, N. Umur, M.A. Zcan and E. Tankurt, 2000. Nitric oxide in chronic liver disease. *Turk. J. Med. Sci.*, 30: 511-515.
31. Nelson, D.L. and M.M. Cox, 2005. *Lehninger: Principles of Biochemistry*. 4th Edn., W.H. Freeman and Company, New York.
32. Tarcin, O., K. Avsar, L. Demirturk, M. Gultepe and B.K. Oktar *et al.*, 2003. *In vivo* inefficiency of pentoxifylline and interferon-alpha on hepatic fibrosis in biliary-obstructed rats: Assessment by tissue collagen content and prolidase activity. *J. Gastroenterol. Hepatol.*, 18: 437-444.
33. Rodriguez-Fragoso, L., M.P. Gonzalez and P. Muriel, 1995. Interferon-alpha 2b increases fibrolysis in fibrotic livers from bile duct ligated rats: Possible participation of the plasminogen activator. *Pharmacology*, 51: 341-346.
34. Muriel, P., 1996. Alpha-interferon prevents liver collagen deposition and damage induced by prolonged bile duct obstruction in the rat. *J. Hepatol.*, 24: 614-621.

35. Fort, J., C. Pilette, N. Veal, F. Oberti and Y. Gallois *et al.*, 1998. Effects of long-term administration of interferon α in two models of liver fibrosis in rats. *J. Hepatol.*, 29: 263-270.
36. Canbakan, B., H. Akin, G. Tahan, O. Tarcin and F. Eren *et al.*, 2009. The effects of pegylated interferon alpha 2b on bile-duct ligation induced liver fibrosis in rats. *Ann. Hepatol.*, 8: 234-240.
37. Kosina, P., V. Kren, R. Gebhardt, F. Grambal, J. Ulrichova and D. Walterova, 2002. Antioxidant properties of silybin glycosides. *Phytother. Res.*, 16: 33-39.
38. Favari, L. and V. Perez-Alvarez, 1997. Comparative effects of colchicine and silymarin on CCl_4 -chronic liver damage in rats. *Arch. Med. Res.*, 28: 11-17.
39. Abdel-Salam, O.M., A.A. Sleem and F.A. Morsy, 2007. Effects of biphenyldimethyl-dicarboxylate administration alone or combined with silymarin in the CCl_4 model of liver fibrosis in rats. *Sci. World J.*, 7: 1242-1255.
40. Cho, Y.K., J.W. Yun, J.H. Park, H.J. Kim and D.I. Park *et al.*, 2009. Deleterious effects of silymarin on the expression of genes controlling endothelial nitric oxide synthase activity in carbon tetrachloride-treated rat livers. *Life Sci.*, 85: 281-290.