



Research Journal of
**Medicinal
Plant**

ISSN 1819-3455



Academic
Journals Inc.

www.academicjournals.com

Antidiabetic Activity of *Cucurbita maxima* Aerial Parts

^{1,2}P. Saha, ¹A. Bala, ¹B. Kar, ¹S. Naskar, ¹U.K. Mazumder, ¹P.K. Haldar and ¹M. Gupta

¹Department of Pharmaceutical Technology, Jadavpur University, Kolkata- 700 032, India

²Guru Nanak Institute of Pharmaceutical Science and Technology, 157/F, Nilgunj Road, Panihati, Kolkata-700114, India

Corresponding Author: U.K. Mazumder, Department of Pharmaceutical Technology, Jadavpur University, Kolkata-700 032, India Tel: +91 9836152837

ABSTRACT

The objective of the present study was to evaluate the antidiabetic activity of methanol extract of aerial parts of *Cucurbita maxima* (MECM) for its purported use in diabetes. Antidiabetic activity of MECM was evaluated in Wistar albino rats against streptozotocin (50 mg kg⁻¹, i.p.) at the doses of 200 and 400 mg kg⁻¹, p.o. for 14 days. Glibenclamide (500 µg kg⁻¹) was used as reference drug. Fasting blood glucose (FBG) levels were measured on day 0, 4, 8 and 15. Antioxidant activity of the extract was determined by measuring lipid peroxide, catalase and glutathione (reduced) levels of liver, kidney and pancreas. In addition, biochemical parameters (SGPT, SGOT, ALP) were estimated. Histological study of liver, kidney and pancreas was also performed. FBG levels were reduced in a treatment-duration dependant manner and 60.88, 67.79 and 64.30% reduction with respect to the initial levels were observed on 15th day with low and high dose of MECM and glibenclamide, respectively. The changes in antioxidant and biochemical parameters observed with diabetic control group were reversed towards normal levels with extract and standard treated groups. Histological observations showed good correlations with other results. The results explored potent antidiabetic activity of the methanol extract of *C. maxima* aerial parts.

Key words: Antidiabetic, cucurbitaceae, glibenclamide, *C. maxima*, streptozotocin

INTRODUCTION

Dietary plants and herbal preparations have recently received considerable attention and have been found to be promising choice over modern synthetic medicines, in a number of studies. In developing countries, all over the world, 80% of population continues to use traditional medicine in primary medical problems (Grover and Yadav, 2004). Research carried out in last few decades has validated several such claims of use of traditional medicinal plants (Tatiya *et al.*, 2001; Zafar *et al.*, 2002) Pumpkin is one such plant that is frequently being used as food as well as traditional medicine for long days.

The pumpkin, *Cucurbita maxima* Duchesne belongs to the family Cucurbitaceae. It is a large climbing herb, annual or perennial. Its aerial part consists of flexible succulent stem with trifoliolate leaves (Kirtikar and Basu, 2003). *Cucurbita maxima* is widely cultivated throughout India and in most warm regions of the world, for use as vegetable as well as medicine. Both of its fruits and the aerial parts are commonly consumed as vegetable. However, the plant has been used traditionally in many countries such as China, India, Yugoslavia, Brazil and America as antidiabetic, antitumor, antihypertensive, anti-inflammatory, immunomodulatory and antibacterial agents (Popovic, 1971;

Jia *et al.*, 2003; Adolfo and Michael, 2005; Caili *et al.*, 2006). Popularity of pumpkin in various traditional system of medicine for several ailments focused the investigators' attention on this plant.

The fruit pulp and seeds of *Cucurbita maxima* have widely been studied for antidiabetic activity. Diabetes mellitus is a chronic metabolic disorder, characterized by fast elevation of blood sugar level. It is a growing public health concern worldwide, causing severe and costly complications including blindness, cardiac and kidney diseases. Synthetic hypoglycemic agents are often found to possess serious side effects, which necessitate the search for suitable antidiabetic agents from plant source (Marles and Farnsworth, 1995). A daily supplement of pumpkin fruit powder was found to reduce blood glucose levels significantly ($p < 0.01$) in the 20 NIDDM diabetics (Chen *et al.*, 1994). The hypoglycemic chemicals of pumpkin include polysaccharides from the fruit pulp, oil from ungerminated seeds and protein from germinated seeds (Zhang and Yao, 2002a,b; Xiong, 2000; Cai *et al.*, 2003). Isolation of several phytochemicals including polysaccharides, phenolic glycosides, 13-hydroxy-9Z, 11E-octadecatrienoic acid from the leaves of pumpkin has been reported (Caili *et al.*, 2006). In addition, preliminary phytochemical study showed the presence of flavonoid in the aerial parts of *Cucurbita maxima*. Number of studies showed potent antidiabetic activity of flavonoids isolated from various plants (Vessal *et al.*, 2003; Matsuda *et al.*, 2002; Aslan *et al.*, 2007; Kamalakkannan and Prince, 2006). Accordingly the present study was carried out to evaluate the antidiabetic activity of aerial parts of *Cucurbita maxima* Duchesne methanol extract (MECM) on streptozotocin (STZ) induced diabetic rats.

MATERIALS AND METHODS

Plant material: The aerial parts of *C. maxima* was collected in June 2009, from Khardah, West Bengal, India and identified by the Botanical Survey of India, Howrah, India. A voucher specimen (P/CM/2/09) was retained in our laboratory for further reference.

Preparation of plant extract: The aerial parts were dried and powdered in a mechanical grinder. The powdered material was extracted with methanol using soxhlet apparatus. This extract was filtered and concentrated *in vacuo* and kept in a vacuum dessicator for complete removal of solvent. The yield was 11.49% w/w with respect to dried powder. Aqueous suspension of MECM was prepared using 2% (v/v) Tween-80 and used for oral administration.

Animals: Healthy Wistar albino rats (160 g \pm 20) were used for the present study. They were maintained at standard laboratory conditions and fed with commercial pellet diet (Hindustan Lever, Kolkata, India) and water *ad libitum*. The animals were acclimatized to laboratory condition for one week before commencement of experiment. The experiments were performed based on animal ethics guidelines of University Animals Ethics Committee.

Acute toxicity study: Healthy Wistar albino rats (160 g \pm 20) of either sex, starved overnight, were divided into five groups (n = 4). Group I-IV animals were orally fed with MECM in increasing dose levels of 0.5, 1.0, 1.5 and 2.0 g kg⁻¹ b.wt, while group V (untreated) served as control. The animals were observed continuously for first 2 h for any gross change in behavioral, neurological and autonomic profiles or any other symptoms of toxicity and mortality if any and intermittently for the next 6 h and then again after 24, 48 and 72 h for any lethality or death. One-tenth and one-fifth of the maximum safe dose of the extract tested for acute toxicity were selected for the experiment (Ghosh, 1984).

Induction of experimental diabetes: A freshly prepared solution of STZ (50 mg kg⁻¹) in ice-cold citrate buffer (0.1 M, pH 4.5) was injected intraperitoneally to the overnight fasted rats (Brosky and Logothelopoulos, 1969). After 72 h of STZ administration, the blood glucose levels were measured and the rats showing blood glucose level >200 mg dL⁻¹ were considered to be diabetic and were used for the present study.

Study on STZ induced diabetic rats: Healthy male Wistar albino rats were divided into five groups (n = 6). Treatment was made for 14 days. Group I: normal rats received only vehicle. Group II, III, IV and V contained STZ induced diabetic rats. Group II received only vehicle and served as diabetic control group. Group III and IV were administered with MECM, 200 and 400-mg kg⁻¹ b.wt. respectively orally; while Group V was treated with the reference drug, Glibenclamide (0.5 mg kg⁻¹ b.wt. p.o.).

Testing of fasting blood glucose level: The fasting blood glucose (FBG) level of each animal was monitored on days 0, 4, 8 and 15. Drop of blood was collected from the tip of the tail vein of each rat and FBG level was measured using One Touch Glucometer, Horizon, from Lifescan, Johnson and Johnson Company.

Estimation of biochemical parameters: On 15th day blood samples were collected from the retro-orbital plexus of the rats and serum was separated for the biochemical estimations of serum glutamic pyruvate transaminase (SGPT), serum glutamic oxaloacetate transaminase (SGOT) (Reitman and Frankel, 1957), alkaline phosphatase (ALP) (Kind and King, 1954). All the analysis were performed using commercially available kit from Span Diagnostics Ltd.

Evaluation of antioxidant properties: After collection of blood, all the animals were sacrificed by euthanasia. Liver, kidney and pancreas were collected from the rats of different groups for the estimation of the tissue lipid peroxide (LPO) (Ohkawa *et al.*, 1979), reduced glutathione (GSH) (Ellman, 1959) and Catalase (CAT) (Luck, 1963) levels for the antioxidant study.

Histology: After sacrificing the rats, parts of pancreas, liver and kidney tissues were collected for the histological studies as well. The tissues were washed in normal saline and fixed by using fixative (picric acid, 40% formaldehyde and glacial acetic acid) for 24 h and dehydrated with alcohol. All tissues were cleaned and embedded in xylene and paraffin. Sections were prepared and then stained with the basic dye haematoxylin and the acid dye eosin for photomicroscopic observation.

Determination of total phenolic compounds in the extract: The amount of total phenolic compounds in MECM was determined using Folin-Ciocalteu's reagent and sodium carbonate solution and the absorbance was measured at 760 nm (Slinkard and Singleton, 1977). A calibration curve of standard pyrocatechol was prepared and the results were expressed as mg of pyrocatechol equivalents /g of dry extract.

Determination of total flavonoid content in the extract: The total flavonoid content of MECM was determined spectrophotometrically (Quettier-Deleu *et al.*, 2000). Briefly 0.5 mL⁻¹ of 2% aluminium chloride in ethanol was mixed with same volume of extract (1.0 mg mL⁻¹).

Absorption readings at 415 nm were taken after 1 h against a blank (ethanol). The total flavonoid content was determined using a standard curve with quercetin (0-50 mg L⁻¹). The mean of three readings was used and expressed as mg of quercetin equivalents/ g of dry extract.

Statistical analysis: Values were presented as mean±SEM. Data were statistically evaluated by one-way analysis of variance (ANOVA) followed by post hoc Dunnett's test using SPSS software. p-values less than 0.01 were considered as statistically significant.

RESULTS

In acute toxicity study, MECM did not show any mortality or toxic effect upto the dose of 2 g kg⁻¹ b.wt. accordingly 200 and 400 mg kg⁻¹ b.wt were taken as low and high dose of MECM for the experiment.

The elevated FBG levels in STZ induced diabetic rats were found to be lowered by MECM treatment upto 60.88 and 67.79% at the dose of 200 and 400 mg kg⁻¹ b.wt respectively (Table1).

After 14 days experiment, the levels of serum enzymes such as SGOT, SGPT and ALP were significantly elevated in the diabetic control groups, while these were resettled to normal level after supplementation with MECM (200 and 400 mg kg⁻¹) and glibenclamide (0.5 mg kg⁻¹) (Fig.1).

As shown in Table 2, lipid peroxide level in liver, pancreas and kidney tissue was increased significantly in STZ induced diabetic rats as compare to those of normal group and these were reduced significantly (p<0.001) after supplementation with MECM. In the STZ induced diabetic control animals, the GSH content was found to be reduced, which was restored to be near normal upon MECM supplementation (Table 3). Similarly catalase activity was reduced with respect to normal control animals; however, both of these were improved in MECM treated group almost like those of the standard drug treated animals (Table 4).

Regarding histological examination of liver, kidney and pancreas tissue, in the diabetic control group, degeneration and necrosis of the tissues were observed in the diabetic groups animals. However, these histopathological changes were found to be restored to the near normal by treatment with MECM. Liver sections of treated rats showed almost complete recovery with little damage in central vein by supplementation with MECM (Fig. 2), damaged glomerulous and cell necrosis in case of kidney sections were recovered to near normal (Fig. 3) while, pancreas sections of MECM treated rats showed dense islets with normal, regular and well arranged cells (Fig. 4). These substantiate the other results of the experiment indicating the potent antidiabetic activity of MECM.

Table 1: Effect of Methanol extract of *C. maxima* (MECM) on fasting blood glucose (FBG) level of control and STZ diabetic rats

Groups	Mean Serum FBG level±SEM (mg dL ⁻¹)				% Change
	Day 0	Day 4	Day 8	Day 15	
NormalControl	82.45±1.09	81.30±2.09	81.08±1.13	83.16±1.38	0.81
Diabetic control	260.30±9.42 ^{a#}	310.35±7.25 ^{a#}	305.33±3.60 ^{a#}	296.65±2.46 ^{a#}	13.96
MECM (200 mg kg ⁻¹)	251.33±4.59	160.50±4.75 ^{b*}	100.17±3.32 ^{b*}	98.33±3.74 ^{b*}	-60.88
MECM(400 mg kg ⁻¹)	253.00±5.34	108.83±3.78 ^{b*}	98.33±4.15 ^{b*}	81.50±2.83 ^{b*}	-67.79
Glibenclamide(0.5 mg kg ⁻¹)	260.85±7.42	230.33±4.43 ^{b*}	167.03±2.91 ^{b*}	93.06±2.78 ^{b*}	-64.30

Values are Mean±SEM; n = 6 in each group. Treatment was done for 14 days. ^aDiabetic control group vs normal control group, #p<0.001,

^bTreated groups vs. diabetic control group, *p<0.001; where the significance was performed by Oneway ANOVA followed by post hoc Dunnett's test

Table 2: Effect of Methanol extract of *C. maxima* (MECM) on tissue lipid peroxide (LPO) levels in control and STZ diabetic rats

Groups	LPO level (nM/mg wet tissue)		
	Pancreas	Liver	Kidney
Normal Control	125.80± 2.60	210.29±0.90	208.43±0.32
Diabetic Control	300.08±5.70 ^{a,##}	390.40±1.08 ^{a,##}	323.24±0.73 ^{a,##}
MECM (200 mg kg ⁻¹)	172.53±2.52 ^{b,**}	282.58±3.45 ^{b,**}	229.87±2.16 ^{b,**}
MECM (400 mg kg ⁻¹)	124.32±2.17 ^{b,**}	188.85±2.79 ^{b,**}	196.77±2.70 ^{b,**}
Glibenclamide(0.5 mg kg ⁻¹)	145.32±2.60 ^{b,**}	236.88±0.62 ^{b,**}	210.29±0.46 ^{b,**}

Values are Mean±SEM; n = 6 in each group. Treatment was done for 14 days. ^adiabetic control group vs normal group, ^{##}p<0.001, ^bTreated group vs diabetic control group, ^{**}p<0.001; where the significance was performed by Oneway ANOVA followed by post hoc Dunnett's test

Table 3: Effect of Methanol extract of *C. maxima* (MECM) on tissue reduced Glutathione (GSH) levels in control and STZ diabetic rats

Groups	GSH level (µg/mg wet tissue)		
	Pancreas	Liver	Kidney
Normal Control	21.88±0.28	69.10±0.80	22.14±0.16
Diabetic Control	9.04±0.29 ^{a,##}	24.09±0.33 ^{a,##}	11.28±0.26 ^{a,##}
MECM (200 mg kg ⁻¹)	14.48±1.09 ^{b,**}	44.95±2.27 ^{b,**}	18.78±1.00 ^{b,**}
MECM(400 mg kg ⁻¹)	17.98±0.73 ^{b,**}	57.64±1.50 ^{b,**}	21.22±0.54 ^{b,**}
Glibenclamide(0.5 mg kg ⁻¹)	18.00±0.16 ^{b,**}	66.31±0.54 ^{b,**}	20.51±0.33 ^{b,**}

Values are Mean±SEM; n = 6 in each group. Treatment was done for 14 days. ^a diabetic control group vs normal group, ^{##}p<0.001, ^bTreated group vs diabetic control group, ^{**}p<0.001; where the significance was performed by Oneway ANOVA followed by post hoc Dunnett's test

Table 4: Effect of Methanol extract of *C. maxima* (MECM) on tissue Catalase (CAT) levels in control and STZ diabetic rats

Groups	CAT level (µM of H ₂ O ₂ decomposed/min/mg wet tissue)		
	Pancreas	Liver	Kidney
Normal Control	0.55±0.04	3.98±0.29	1.78±0.20
Diabetic Control	0.25±0.01 ^{a,##}	1.25±0.06 ^{a,##}	0.41±0.05 ^{a,##}
MECM (200 mg kg ⁻¹)	0.41±0.03 ^{b,*}	2.21±0.06 ^{b,*}	1.45±0.04 ^{b,**}
MECM (400 mg kg ⁻¹)	0.63±0.02 ^{b,**}	3.89±0.05 ^{b,**}	1.79±0.03 ^{b,**}
Glibenclamide(0.5 mg kg ⁻¹)	0.53±0.03 ^{b,**}	3.05±0.30 ^{b,**}	1.40±0.15 ^{b,**}

Values are Mean±SEM; n = 6 in each group. Treatment was done for 14 days. ^a diabetic control group vs normal group, [#]p<0.01, ^{**}p<0.001, ^b Treated group vs. diabetic control group, ^{*} p<0.01, ^{**} p<0.001; where the significance was performed by Oneway ANOVA followed by post hoc Dunnett's test

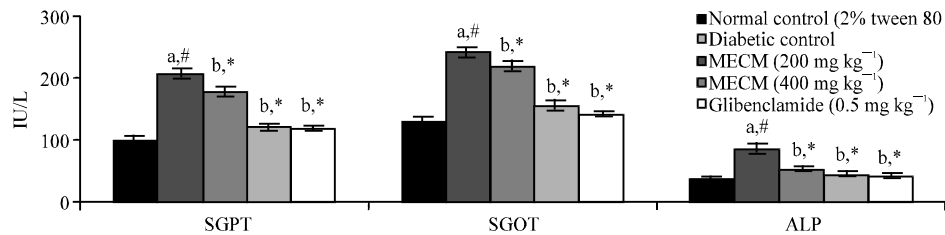


Fig. 1: Effect of MECM on biochemical parameters of STZ induced diabetic rats: Values are Mean±SEM; n = 6 in each group. Treatment was done for 14 days. ^aDiabetic control group vs normal control group, ^{##}p<0.001, ^bTreated groups vs diabetic control group, ^{*}p<0.001; where the significance was performed by Oneway ANOVA followed by post hoc Dunnett's test

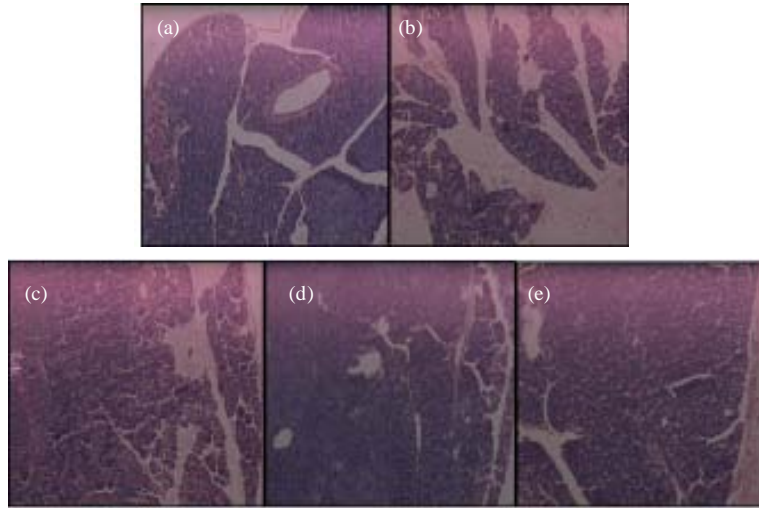


Fig. 2: Histological examinations of 14 days experimental rat pancreas: Pancreatic sections of normal rats (a) showed dense langerhans islets with well preserved cytoplasm and nucleus. Pancreatic sections of STZ intoxicated rats (b) showed loss of cell integrity and islets mass, damaged islets, acini degeneration and polymorphonuclear leucocytes infiltration. Pancreatic sections of low dose and high dose MECM treated rats (c and d) depicted the gradual improvement in islet mass and cell integrity. Pancreatic sections of glibenclamide treated animals (e) showed normal tissue architecture with light damage

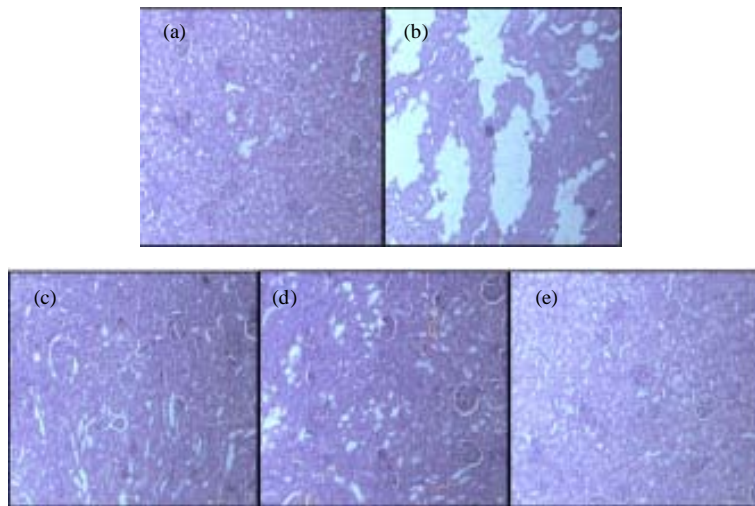


Fig. 3: Histological examinations of 14 days experimental rat kidney: Kidney section of normal rats (a) showed the cortex and medulla portion with lot of well packed glomerulous and well arranged tubules. Kidney section of diabetic control group (b) showed damage cells with hypertrophy and necrosis and derangement of cells with glomerulosclerosis. Kidney section of low dose and high dose MECM treated rats (c and d) depicted improvements as compared to those of diabetic control group, with respect to hypertrophy and necrosis of the glomerular cells. Kidney section of glibenclamide treated rats (e) showed the complete recovery of the damage

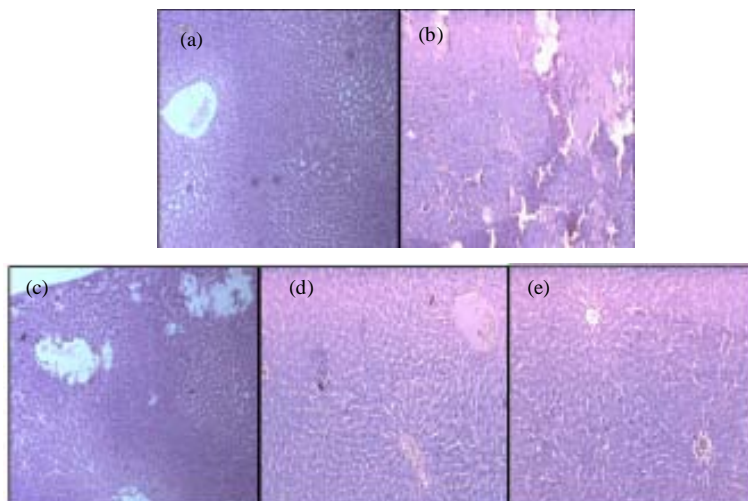


Fig. 4: Histological examinations of 14 days experimental rat liver: Liver section of normal rats (a) showed the well arranged cells and clear large central vein, cytoplasm and nucleus are well preserved. Liver section of diabetic control group (b) showed the complete destruction of hepatocytes, degeneration of central vein, fatty degeneration, loss of cell structure and damage in cell membrane. Liver section of low dose and high dose MECM treated rats (c and d) revealed more or less well arranged hepatocytes, with clear central vein and absence of necrosis. Liver section of glibenclamide treated rats (e) showed complete recovery of hepatocytes and well arranged cells surrounding the central vein

The total phenolic and flavonoid content of the extract were found to be 42.00 ± 0.46 mg pyrocatechol equivalent/g dry extract and 26.50 ± 0.80 mg quercetin equivalent /g dry extract.

DISCUSSION

Streptozotocin, a glucose analogue (2-deoxy-2-(3-methyl-3-nitrosouredio)-D-glucopyranose), is a potent diabetogenic agent and widely used for inducing diabetes in a variety of animals by the selective degeneration and necrosis of pancreatic cells (Merzouk *et al.*, 2000; Elsner *et al.*, 2000). The present data indicated that MECM significantly reduced the elevated fasting blood glucose level with respect to those of diabetic control animals. This antihyperglycemic action may be attributed to the potentiation of pancreatic secretion of insulin from the existing or regenerated cells of islets and its action or to the extrapancreatic mechanisms like enhanced transport of blood glucose to peripheral tissue, increased peripheral utilization of glucose via different enzymatic pathways or inhibition of intestinal absorption of glucose, similar to the studies reported in earlier cases (Palanichamy *et al.*, 1988; Shanmugasundaram *et al.*, 1981; Jasmine and Daisy, 2007a, b; Saha *et al.*, 2008; Okokon *et al.*, 2007).

Serum enzymes including, serum glutamic oxaloacetic transaminase (SGOT), serum glutamic pyruvic transaminase (SGPT) and alkaline phosphatase (ALP) are used in the evaluation of hepatic disorders. Serum enzyme levels were significantly raised to high values in diabetic control animals, reflecting active liver damage or inflammatory hepatocellular disorders (Foreston *et al.*, 1985; Mohamed *et al.*, 2009). Treatment with MECM, like Glibenclamide, caused significant reduction in the activities of these enzymes to normal level, showing the protective effect of the extract.

Hyperglycemia is reported to increase oxidative stress through free radical formation (Trachtman *et al.*, 1993; Ashok *et al.*, 2010). Endogenous oxygen free radicals scavenging enzymes can respond to such conditions of oxidative stress in diabetes with a compensatory mechanism. Concentration of lipid peroxides was increased in liver, kidney and pancreas of diabetic rats, indicating an increased free radical generation and/or exhaustion of endogenous antioxidant system. The present finding showed significant attenuation of the lipid peroxide level by the treatment of MECM as well as glibenclamide. Reduced glutathione is a potent free radical scavenger. Its depletion in diabetic animals indicates high oxidative stress, which was however recovered in the liver, pancreas as well as kidney of the extract treated animals. Catalase is involved in the elimination of H₂O₂ and plays a vital role in cellular stress reduction (Brioukhanov and Netrusov, 2004). Treatment of MECM increased the enzyme level in the tissues of liver, kidney and pancreas and thus may help to minimize the free radical generation and hence oxidative stress in diabetes. Therefore the recovery of the antioxidant status of diabetic rats by treatment with MECM reveals the antioxidant property of MECM by which it can significantly reduce the imbalance between the free radical generation and endogenous antioxidant system. This may be beneficial for minimizing the complications of the disease.

The above antihyperglycemic and antioxidant properties of MECM were supported by the comparative histopathological studies of pancreas, liver and kidney tissues of diabetic control animals as well as extract and standard drug treated animals. Diabetic rats showed reduced number of islet cells which were restored to near normal upon treatment with the extract as was found in the histology of the tissues of treated group animals and that substantiates the cytoprotective action of the extract in diabetic condition. Similar protective effects were observed in case of kidney and liver tissues of the treated groups as well.

CONCLUSION

From the present investigation, therefore, it can be concluded that MECM supplementation is quite beneficial in controlling the blood glucose level. In addition, it possesses potent antioxidant properties, which is useful to reduce the oxidative stress in diabetes and hence may have a protective role on complications associated with diabetes. Hence the aerial parts of *C.maxima* methanol extract can be considered as a potent source of antidiabetic and antioxidant agents, which may be due to the presence of flavonoids, polyphenolic or polysaccharides in the extract. Further studies are ongoing to isolate the bioactive principle(s) from it.

ACKNOWLEDGMENT

Necessary support and cooperation from Dr. Abhijit Sen Gupta, Director-cum-Principal, Guru Nanak Institute of Pharmaceutical Sciences and Technology, Kolkata and Dr. P.K. Ghosh, Registrar, Jadavpur University, Kolkata are hereby gratefully acknowledged.

REFERENCES

- Adolfo, A.C. and H. Michael, 2005. Mexican plants with hypoglycaemic effect used in the treatment of diabetes. *J. Ethnopharmacol.*, 99: 325-348.
- Ashok, P., A. Kyada, P. Subbarao, S. Suthar, D. Singh and K. Vadaliya, 2010. Antioxidant status of a polyherbomineral formulation (Gly-13-C) in STZ-diabetic rats. *Int. J. Pharmacol.*, 6: 157-172.

- Aslan, M., D.D. Orhan, N. Orhan, E. Sezik and E. Yesilada, 2007. *In vivo* antidiabetic and antioxidant potential of *Helichrysum plicatum* ssp. *plicatum* capitulum in streptozotocin-induced-diabetic rats. *J. Ethnopharmacol.*, 109: 54-59.
- Brioukhanov, A.L. and A.I. Netrusov, 2004. Catalase and superoxide dismutase: Distribution, properties and physiological role in cells of strict anaerobes. *Biochemistry*, 69: 949-962.
- Brosky, G. and J. Logothetopoulos, 1969. Streptozotocin diabetes in the mouse and guinea pig. *Diabetes*, 18: 606-611.
- Cai, T.Y., Q.H. Li, H. Yan and N. Li, 2003. Study on the hypoglycemic action of pumpkin seed protein. *J. Chin. Inst. Food Sci. Technol.*, 3: 7-11.
- Caili, F.U., H. Shi and L.I. Quanhong, 2006. A review on pharmacological activities and utilization technologies of pumpkin. *Plant Foods Human Nutr.*, 61: 73-80.
- Chen, Z., X. Wang, Y. Jie, C. Huang and G. Zhang, 1994. Study on hypoglycemia and hypotension function of pumpkin powder on human. *Jiangxi Chin. Med.*, 25: 50-50.
- Ellman, G.L., 1959. Tissue sulphhydryl groups. *Arch. Biochem. Biophys.*, 82: 70-77.
- Elsner, M., B. Guldbakke, M. Tiedge, R. Munday and S. Lenzen, 2000. Relative importance of transport and alkylation for pancreatic beta-cell toxicity of streptozotocin. *Diabetologia*, 43: 1528-1533.
- Foreston, W.C., F.J. Tedesco and E.C. Starnes, 1985. Marked elevation of serum transaminase activity associated with extrahepatic biliary tract disease. *J. Clin. Gastroenterol.*, 76: 502-505.
- Ghosh, M.N., 1984. *Fundamentals of Expt Pharmacology*. 2nd Edn., Scientific Book Agency, Calcutta, pp:192-194.
- Grover, J.K. and S.P. Yadav, 2004. Pharmacological actions and potential uses of *Momordica charantia*: A review. *J. Ethnopharm.*, 93: 123-132.
- Jasmine, R. and P. Daisy, 2007. Effect of crude extract and fractions from *Elephantopus scaber* on hyperglycemia in streptozotocin-diabetic rats. *Int. J. Biol. Chem.*, 1: 111-116.
- Jasmine, R. and P. Daisy, 2007. Hypoglycemic and hypolipidemic activity of *Eugenia jambolana* in streptozotocin-diabetic rats. *Asian J. Biochem.*, 2: 269-273.
- Jia, W., W. Gao and L. Tang, 2003. Antidiabetic herbal drugs officially approved in China. *Phytother. Res.*, 17: 1127-1134.
- Kamalakkannan, N. and P.S.M. Prince, 2006. Antihyperglycemic and antioxidant effect of rutin, a polyphenolic flavonoid, in streptozotocin induced diabetic wistar rats. *Basic Clin. Pharmacol. Toxicol.*, 98: 97-103.
- Kind, P.R.N. and E.J. King, 1954. Estimation of plasma phosphatase by determination of hydrolysed phenol with antipyrin. *J. Clin. Path.*, 7: 322-331.
- Kirtikar, K.R. and B.D. Basu, 2003. *Indian Medicinal Plants*. 2nd Edn., Oriental Enterprises, Uttaranchal, India, pp: 1606-1608.
- Luck, H., 1963. A Spectrophotometric Method for the Estimation of Catalase. In: *Methods of Enzymatic Analysis*, Bergmeyer, H.V. (Ed.). Academic Press, New York, pp: 886-888.
- Marles, R.J. and N.R. Farnsworth, 1995. Antidiabetic plants and their active constituents. *Phytomedicine*, 2: 137-189.
- Matsuda, H., T. Morikawa and M. Yoshikawa, 2002. Antidiabetogenic constituents from several natural medicines. *Pure Applied Chem.*, 74: 1301-1308.
- Merzouk, H., S. Madani, D.S. Chabane, J. Prost, M. Bouchenak and J. Belleville, 2000. Time course of changes in serum glucose, insulin, lipids and tissue lipase activities in macrosomic offspring of rats with streptozotocin-induced diabetes. *Clin. Sci.*, 98: 21-30.

- Mohamed, A.M., F.Z. El-Sharkawy, S.A.A. Ahmed, W.M. Aziz and O.A. Badary, 2009. Glycemic control and therapeutic effect of *Nigella sativa* and *Curcuma longa* on rats with streptozotocin-induced diabetic hepatopathy. *J. Pharmacol. Toxicol.*, 4: 45-57.
- Ohkawa, H., N. Oishi and K. Yagi, 1979. Assay for lipid peroxides in animal tissue by thiobarbituric acid reaction. *Anal. Biochem.*, 95: 351-358.
- Okokon, J.E., B.S. Antia and B.N. Ita, 2007. Antidiabetic effects of *Homalium letestui* (Flacourtiaceae) in streptozotocin induced diabetic rats. *Res. J. Medicinal Plant*, 1: 134-138.
- Palanichamy, S., S. Nagarajan and M. Devasagayam, 1988. Effect of *Cassia alata* leaf extract on hyperglycemic rats. *J. Ethnopharmacol.*, 22: 81-90.
- Popovic, M., 1971. On growing squash and pumpkin (*Cucurbita* sp.) in Yugoslavia. *Savremena Poljoprivreda*, 11: 59-71.
- Quettier-Deleu, C., B. Gressier, J. Vasseur, T. Dine and C. Brunet *et al.*, 2000. Phenolic compounds and antioxidant activities of buckwheat (*Pagopyrum esculentum* moench), hulls and flour. *J. Ethnopharmacol.*, 72: 35-42.
- Reitman, S. and S. Frankel, 1957. A colorimetric method for the determination of serum glutamate oxaloacetate and glutamate pyruvate transaminase. *Am. J. Clin. Pathol.*, 28: 56-56.
- Saha, P., V.T. Selvan, S.K. Mondal, U.K. Mazumder and M. Gupta, 2008. Antidiabetic and antioxidant activity of methanol extract of *Ipomoea reptans* Poir aerial parts in Streptozotocin induced diabetic rats. *Pharmacology*, 1: 409-421.
- Shanmugasundaram, K.R., C. Paneerselvam, P. Samudram and E.R.B. Shanmugasundaram, 1981. The insulinotropic activity of *Gymnema sylvestre* R.Br. an Indian medical herb used in controlling diabetes mellitus, 1981. *Pharmacol. Res. Commun.*, 13: 475-486.
- Slinkard, K. and V.L. Singleton, 1977. Total phenol analysis: Automation and comparison with manual methods. *Am. J. Enol. Vitic*, 28: 49-55.
- Tatiya, A.U., U.V. Deore, P.G. Jain and S.J. Surana, 2011. Hypoglycemic potential of *Bridelia retusa* bark in albino rats. *Asian J. Biol. Sci.*, 4: 84-89.
- Trachtman, H., S. Futterweit and R.S. Bienkowski, 1993. Taurine prevents glucose-induced lipidperoxidation and increased collagen production in cultured rat mesangial cells. *Biochem. Biophys. Res. Commun.*, 199: 759-765.
- Vessal, M., M. Hemmati and M. Vasei, 2003. Antidiabetic effects of quercetin in streptozotocin-induced diabetic rats. *Comp. Biochem. Physiol. C Toxicol. Pharmacol.*, 135C: 357-364.
- Xiong, X.M., 2000. Study on extraction and separation of effective composition of pumpkin polysaccharide and its glucatonic effect. *Chin. Tradit. Patent. Med.*, 22: 563-565.
- Zafar, I., P.M. Asadullah, M. Ismail, B. Ahmad, S. Zakir and G. Saima, 2002. Study of the hypoglycemic activity of *Hedera helix* L. in alloxan-induced diabetic rabbits. *J. Med. Sci.*, 2: 206-208.
- Zhang, Y.J. and H.Y. Yao, 2002. Revealing the effective ingredient in pumpkin for reducing blood sugar. *J. Chin. Cereals Oils Assoc.*, 17: 59-62.
- Zhang, Y.J. and H.Y. Yao, 2002. Study on effect of hypoglycemia of different type pumpkin. *J. Chin. Food Sci.*, 23: 118-120.