



Research Journal of  
**Veterinary  
Sciences**

ISSN 1819-1908



Academic  
Journals Inc.

[www.academicjournals.com](http://www.academicjournals.com)

## Protective Effects of Garlic Extract and Vitamin C Against Cypermethrin Reproductive Toxicity in Male Rats

<sup>1</sup>M.E. Assayed, <sup>2</sup>H.A. Salem and <sup>3</sup>A.A. Khalaf

<sup>1</sup>Department of Forensic Medicine and Toxicology,  
Faculty of Veterinary Medicine, Menofiya University,

<sup>2</sup>Department of Pathology, Faculty of Veterinary Medicine, Menoufiya University

<sup>3</sup>Department of Forensic Medicine and Toxicology, Faculty of Veterinary Medicine,  
Cairo University, Egypt

---

**Abstract:** The toxicological properties of the synthetic pyrethroid insecticide Cypermethrin (CYP) on testes and the fertility parameters of male white rats as well as possible protective roles of two natural elements: garlic extract (GRE, 500 mg kg<sup>-1</sup>) and vitamin C (VTC, 20 mg kg<sup>-1</sup>) against the insecticide toxicity were assessed. CYP was administered orally either alone, concomitantly with each individual stuff, or with their combination (GRE or/and VTC); as repeated daily administration for 5 consecutive days. Present data cleared that CYP adversely affected male reproductive function as revealed by the significant abnormal spermatozoal parameters and histopathological alterations in testicular tissue along the whole experimental period. On the other hand, this investigation fundamentally cleared the protective and/or ameliorative role played by GRE and VTC; either each alone or in combination against the toxicological aspects of Cypermethrin; providing that garlic extract was often more efficient in its protective action against the insecticide toxicity than vitamin C and that the combination of both natural elements was in most cases more advantageous than when each one was administered alone.

**Key words:** Cypermethrin, rat, testes, fertility, garlic extract, vitamin C

---

### INTRODUCTION

Pesticide poisoning is an important cause of morbidity and mortality in developing countries. Every year there are 3 million cases of severe poisoning and 220,000 deaths; the majority of these poisonings and 99% of the resulting deaths occur in the third world (Tinoco and Halperin, 1998). The toxicity of pyrethroid insecticides to mammalian animals has received much attention in recent years because animals exposed to these insecticides exhibited changes in their physiological activities beside other pathological features (Sakr, 2003).

Recent studies have shown that a wide range of pyrethroid pesticides, like Cypermethrin, in trace amounts may lead to serious problems in males and females and a variety of reproductive disorders in human as well as wildlife, including infertility (Elbetieha *et al.*, 2001).

Bhunya and Pati (1988) reported a significant increase in the proportion of dead and abnormal sperms in mice after exposure to the pesticide Cypermethrin. Also, El-Ashmawy *et al.* (1993) reported cytotoxic effects of aerosols of the pyrethroid insecticide Matox® on male rats exposed to Matox® daily up to 2, 4 and 8 week, which exhibited a significant decrease in weights of testis, epididymis, seminal vesicle and prostate glands, after 4 and 8 week beside that the sperm motility percentage and sperm concentration were found to be significantly decreased after 2, 4 and 8 week of exposure.

Meanwhile Hassan *et al.* (1993) studied the effects of oral administration of two synthetic pyrethroid insecticides: Sumicidine and S-3206 on mature male rats at doses of 20.0, 100.0, 1 and

---

**Corresponding Author:** M.E. Assayed, Department of Forensic Medicine and Toxicology,  
Faculty of Veterinary Medicine, Menofiya University, Egypt

5 mg kg<sup>-1</sup> b wt., respectively for 65 successive days and they observed that both pyrethroid insecticides caused significant decrease in the weights of male reproductive organs, sperm cell count, percentage of sperm motility and seminiferous tubules containing spermatozoa as well as significant increase in the percentage of sperm head and tail abnormalities, beside severe degenerative changes in the seminiferous tubules and complete necrosis of many tubules and tubular lumen was either empty or contained few immature sperm cells.

Additionally, Elbetieha *et al.* (2001) noticed that ingestion of Cypermethrin at a concentration of 18.93 or 39.66 mg day<sup>-1</sup> by Sprague Dawley rats resulted in significant increase in the weights of testes and seminal vesicles and significant decrease in epididymal and testicular sperm counts; as well as significant reduction in serum levels of testosterone, follicle-stimulating hormone and luteinizing hormone. The authors further observed significant decrease in the cell layers of testicular seminiferous tubules in treated animals; which contained a large number of immature spermatids; congested blood vessels and marked hemorrhage beside a significant thickening of connective tissue surrounding the tubules.

Moreover, Manna *et al.* (2004) observed oedema between seminiferous tubules, in addition to vacuolation and hyalinization in the tubules of rat testis, after single oral administration of  $\alpha$ -Cypermethrin at 145 mg kg<sup>-1</sup>.

Imai *et al.* (1994) studied the antioxidant properties of three garlic preparations and organosulfur compounds in garlic. They observed that these compounds play an important role in the antioxidative activity of fresh garlic extract. Based on the *in vivo* studies with rodents, there are indications that some of the chemical constituents of garlic can enhance the activities of detoxification enzymes such as Glutathione-S-transferase, Glutathione peroxidase, Glutathione reductase and the conjugating enzyme, gamma-glutamyltranspeptidase ( $\gamma$ GT) (Yang *et al.*, 1994; Manson *et al.*, 1997). Additionally, Vitamin C's role in the prevention of disease and malignancy has been studied over the last several decades. Scientists have showed it could exert chemopreventive effects without apparent toxicity at doses higher than the current recommended dietary allowance of 60 mg day<sup>-1</sup> (Lee *et al.*, 2003). Thus, Grajeda-Cota *et al.* (2004) claimed that it is possible to believe that vitamin C can provide antioxidant-cellular protection against Cypermethrin oxidative toxicity.

The present work is designed to investigate the deleterious effects of repeated oral administration of the pyrethroid insecticide CYP on rat testes in general and certain spermatozoal parameters in particular; which are relative to the reproductive toxicity potential of the insecticide. On the other hand, the possible protective roles of two natural elements: fresh garlic extract (GRE, 500 mg kg<sup>-1</sup>) and vitamin C (VTC, 20 mg kg<sup>-1</sup>) against the insecticide reproductive toxicity were assessed in those white rats, so that CYP was administered orally either alone, concomitantly with each individual stuff, or with their combination (GRE or/and VTC); as repeated daily administration for 5 consecutive days.

## MATERIALS AND METHODS

### The Insecticide

Cypermethrin® (CYP), obtained from National Chemical and Pesticide Co. A type-II pyrethroids cyanopyrethroids having the chemical name [ $\alpha$ -Cyano-(3-phenoxyphenyl) methyl ( $\pm$ )-cis/trans-3-(2,2-dichlorovinyl)2,2-dimethylcyclo-propanecarboxylate] and molecular formula C<sub>22</sub>H<sub>19</sub>O<sub>3</sub>NCl<sub>2</sub>. The compound was diluted with distilled water to concentration levels in which 1 mL of diluted working solution contained 25 mg Cypermethrin.

### Natural Elements

#### Garlic

Fresh peeled cloves of garlic (*Allium sativum*, purchased from Egyptian market) were sliced into small pieces and ground in clean mortar using a mortar pestle to produce a fine paste. The working

solution was then prepared by dissolving 5 g of the paste in 100 mL of distilled water, where 1 mL of the extract contains 50 mg of crude garlic. Garlic fresh extract was orally administered to rats by the aid of a stomach tube fitted to a graduated syringe, at a dose level of 500 mg kg<sup>-1</sup> body weight for 5 consecutive days/week (Singh *et al.*, 1995).

#### **L-Ascorbic Acid (Vitamin C)**

A pure form of L (+) ascorbic acid aqueous solution was used as the second putative natural protector; supplied by E. Merck Science Inc., Darmstadt, West Germany. A freshly prepared aqueous solution of L-ascorbic acid was orally administered to the treated rats throughout the experiments, either solely or in combination with garlic extract, in a dose level of 20 mg kg<sup>-1</sup> b.wt. (Double the human recommended therapeutic dose of 10 mg kg<sup>-1</sup> b.wt. day<sup>-1</sup>) for 5 successive days/week (Khan and Sinha, 1993).

#### **Animals**

Seventy-five apparently healthy male white rats (*Rattus rattus*) of Wistar strain were used throughout the whole work. These animals were kept under hygienic and environmental conditions. A well-balanced ration and water was supplied *ad libitum*.

#### **Experimental Design**

This study was carried out on a total of 75 sexually mature male rats categorized into five main groups; 15 rats each. Rats in the first four groups were orally administered Cypermethrin and/or natural protectors individually or in combination daily for 60 days, in a dose of 55.1 mg kg<sup>-1</sup> b.wt. (1/5 LD<sub>50</sub>) for 5 successive days/week; while the fifth group was kept without treatment, served as a control group.

#### **Scheduled Time of Sacrifice**

At each of the 30th, 45th and 60th days of the experiment, 5 rats from each group were sacrificed by severing of the neck vessels and testes and *Caudae epididymidis* were dissected out and used for running a comprehensive testicular pathological examination and spermatozoal analysis. The spermatozoa were carefully examined for mass motility, live and dead sperms, spermatozoal head and tail abnormalities and the concentration of sperm cells per epididymis.

#### **Methods Used for Epididymal Spermatozoal Examination**

##### **Mass Motility**

The epididymal sperm content was obtained by maceration of tail of epididymis on a dry, clean and warm slide; mixing well with one drop of warm normal saline solution 0.9% and immediately examined under the (X10) objective lens of a light microscope supplied with a temperature-controlled hot stage (adjusted at 37°C) for determination of mass motility percentage of spermatozoa, expressed as replicates of ten according to Bearden and Fuquay (1980).

##### **Live and Dead Sperms**

A drop of epididymal content of each rat was mixed with an equal drop of eosin-nigrosin stain, prepared in accordance with Barth and Oko (1994). Thin films were made by spreading the stained content onto clean slides and quickly dried on a hot plate.

Eosin is a differential stain; unable to pass through living cell membrane but can pass through non living ones. A background nigrosin stain made the unstained sperm heads visible. One hundred sperm cells per rat were scored for determining the incidence of live and dead sperms, expressed in percent.

### **Spermatozoal Abnormalities**

A drop of epididymal content was treated similarly as mentioned in live and dead sperms procedures and then the percentage of abnormal sperms was determined, including head and tail abnormalities.

### **Sperm Cell Concentration**

The concentration of the sperm cells was determined according to the technique adopted by Bearden and Fuquay (1980), using the Improved New Pauer haemocytometer and haemocytometer pipette of erythrocytes for counting of sperm cells:

- The whole epididymis was thoroughly macerated so as to bring about most - if not all - the epididymal content and then the content was diluted with 100  $\mu$ L eosin aqueous solution (1%).
- The diluted stained content was withdrawn up to the mark 0.5 on the erythrocyte pipette; the pipette was then filled up to mark 101 by 1% eosin aqueous solution.  
The eosin killed sperms so that their counting could be accomplished (no motility) as well as staining the sperm heads to be easily counted.
- The contents in the pipette bulb were mixed and the sperm heads were counted in five large squares (80 small squares).
- The sperm cell concentration per epididymis was calculated using the following equation:

$$\text{Sperm concentration/epididymis} = \frac{N}{80} \times 400 \times 200 \times 100 \times 10$$

Where:

- N = Counted sperm number
- 80 = No. of small squares in five large squares
- 400 = Total No. of small squares in chamber
- 10 = Depth of haemocytometer chamber
- 200 = Dilution factor on pipette
- 100 = Dilution factor of epididymal content

Additionally, determination of index weights of rats testes (I.W.) were calculated according to the equation of Bearden and Fuquay (1980):

$$\text{I.W.} = \frac{\text{Organ weight}}{\text{Body weight}} \times 100$$

### **Histopathological Examination**

Testes were then preserved in 10% buffered neutral Formaline solution for about 2 week and then submitted to histopathological examination according to Bancroft *et al.* (1996).

### **Statistical Analysis**

Data were expressed as arithmetical Mean $\pm$ Standard error of the mean. Least Significance Difference test (LSD) was carried out and the Analyses of Variance (ANOVA) were conducted to obtain the significance of the treatments compared with the control, using the Statistical Analysis System.

## RESULTS

### Results of Testicular Weight and Spermatozoal Analysis

Reading the data arranged in (Table 1) reveals that the testes index weights of Cypermethrin-treated rats (CYP group) exhibited highly significant reduction, at day 30 of the experiment; where it was significant at days 45 and 60 of the experiment. On the other hand, oral treatment of male rats with either whole garlic extract (CYP+GRE) or L-ascorbic acid (CYP+VTC) prior to Cypermethrin oral administration induced significant augmentation in the testes index weights at days 30 and 45 of the experiment; while failed to produce significant alteration in testes index weight at day 60 as compared with (CYP) group. Moreover, the combined administration of both natural elements (whole garlic extract+L-ascorbic acid) concomitantly with Cypermethrin (CYP+GRE and VTC) caused a significant increase in the testicular index weight only at day 30 of the experiment; while such increase was statistically non significant at days 45 and 60 of the experimental period, as compared with (CYP) group. No significant difference in the testicular index weights was found between control group and each of (CYP+GRE) group at day 60 and (CYP+VTC) group at days 45 and 60 of the experiment.

Concerning the percentage of mass motility, data in (Table 2) indicate that oral dosing of rats with Cypermethrin alone (CYP-group) induced highly significant reduction in sperm mass motility along the whole period of the experiment; in comparison with the control group. The concomitant administration of either garlic extract (CYP+GRE) or L-ascorbic acid (CYP+VTC) caused highly significant elevations in the mass motility percentage at all the experimental periods when compared with (CYP) group values. It can be noticed that the elevation in sperm mass motility percentage produced by garlic extract administration (CYP+GRE) is much more pronounced than that produced by L-ascorbic acid administration (CYP+VTC) at days 30 and 45 and even overwhelmed the effect of the combined administration of garlic extract and L-ascorbic acid (CYP + GRE and VTC) at day 30 of the experiment.

Meanwhile, the data (Table 3) revealed that oral administration of Cypermethrin alone (CYP group) resulted in highly significant reduction in the viability of spermatozoa of treated rat all over the experimental periods; as compared with the control group. However, the parallel administration of garlic extract and L-ascorbic acid; either separately or in the form of combined administration with Cypermethrin gavage; highly significantly increased the percentage of live spermatozoa along the whole period of the experiment when compared with corresponding values in (CYP) group.

Additionally, (Table 4) displays the mean values of epididymal sperm cell concentration ( $\times 10^6$  per epididymis) of control and treated rats at different time periods of the experiment and

Table 1: Effect of Cypermethrin oral administration alone and with natural protectors on testes index weight (g) of albino rats at different time periods

| Time (days) | Control   | CYP          | CYP+GRE     | CYP+VTC     | CYP+GRE and VTC |
|-------------|-----------|--------------|-------------|-------------|-----------------|
| 30          | 2.04±0.16 | 1.37±0.13a** | 1.83±0.11b* | 1.77±0.08b* | 1.77±0.06b*     |
| 45          | 1.66±0.09 | 1.20±0.06a*  | 1.65±0.04b* | 1.55±0.11b* | 1.49±0.06       |
| 60          | 1.69±0.05 | 1.12±0.09a*  | 1.45±0.03   | 1.33±0.06   | 1.36±0.05       |

a: Significantly different from control group; b: Significantly different from CYP group; c: Significantly different from CYP+GRE group; d: Significantly different from CYP+VTC group; \*: Significant ( $p < 0.05$ ); \*\*: Highly significant ( $p < 0.01$ )

Table 2: Effect of Cypermethrin oral administration alone and with natural protectors on sperm mass motility (%) of albino rats at different time periods

| Time (Days) | Control | CYP        | CYP+GRE    | CYP+VTC     | CYP+GRE and VTC |
|-------------|---------|------------|------------|-------------|-----------------|
| 30          | 78±5.82 | 28±5.83a** | 66±2.44b** | 56±0.44bc** | 58±3.74**       |
| 45          | 76±2.44 | 30±5.47a** | 60±4.47b** | 50±4.47b**  | 56±5.09b**      |
| 60          | 82±3.74 | 22±5.83a** | 58±3.74b** | 58±5.83b**  | 60±3.16b**      |

a: Significantly different from control group; b: Significantly different from CYP group; c: Significantly different from CYP+GRE group; d: Significantly different from CYP+VTC group; \*\*: Highly significant ( $p < 0.01$ )

Table 3: Effect of Cypermethrin oral administration alone and with natural protectors on live sperm (%) of albino rats at different time periods

| Time (Days) | Control   | CYP          | CYP+GRE      | CYP+VTC      | CYP+GRE and VTC |
|-------------|-----------|--------------|--------------|--------------|-----------------|
| 30          | 84.2±1.93 | 46.2±2.51a** | 71.8±2.43b** | 77.0±1.22b** | 80.6±2.15b**    |
| 45          | 87.4±2.37 | 35.4±2.50a** | 69.8±2.13b** | 70.6±1.07b** | 79.0±1.81bd**   |
| 60          | 84.0±1.70 | 28.2±1.82a** | 67.6±1.43b** | 74.0±2.91b** | 76.0±1.22b**    |

<sup>a</sup>: Significantly different from control group; <sup>b</sup>: Significantly different from CYP group; <sup>c</sup>: Significantly different from CYP+GRE group; <sup>d</sup>: Significantly different from CYP+VTC group; \*\*: Highly significant (p<0.01)

Table 4: Effect of Cypermethrin oral administration alone and with natural protectors on sperm cell concentration (× 106/epididymis) of albino rats at different time periods

| Time (Days) | Control   | CYP          | CYP+GRE      | CYP+VTC      | CYP+GRE and VTC |
|-------------|-----------|--------------|--------------|--------------|-----------------|
| 30          | 46.8±1.65 | 28.8±0.66a** | 36.8±1.24b** | 31.6±0.67    | 37.6±0.92bd**   |
| 45          | 50.2±1.65 | 20.8±0.86a** | 31.8±0.86b** | 32.2±1.55b** | 38.0±1.22bcd**  |
| 60          | 48.0±1.51 | 16.8±1.28a** | 34.2±1.74b** | 31.8±0.22b** | 41.6±0.92bcd**  |

<sup>a</sup>: Significantly different from control group; <sup>b</sup>: Significantly different from CYP group; <sup>c</sup>: Significantly different from CYP + GRE group; <sup>d</sup>: Significantly different from CYP+VTC group; \*\*: Highly significant (p<0.01)

Table 5: Effect of Cypermethrin oral administration alone and with natural protectors on sperm cell abnormalities (%) of albino rats at different time periods: A- Head Abnormalities

| Time (Days) | Control  | CYP          | CYP+GRE     | CYP+VTC      | CYP+GRE and VTC |
|-------------|----------|--------------|-------------|--------------|-----------------|
| 30          | 1.0±0.28 | 13.8±0.66a** | 4.6±0.50b** | 5.6±0.50b**  | 5.0±0.70b**     |
| 45          | 1.4±0.24 | 14.6±0.74a** | 5.0±0.63b** | 5.8±0.37b**  | 5.4±0.92b**     |
| 60          | 1.6±0.50 | 15.8±0.86a** | 4.2±0.37b** | 6.4±0.51bc** | 6.6±0.50bc**    |

<sup>a</sup>: Significantly different from control group; <sup>b</sup>: Significantly different from CYP group; <sup>c</sup>: Significantly different from CYP+GRE group; <sup>d</sup>: Significantly different from CYP+VTC group; \*\*: Highly significant (p<0.01)

Table 6: Effect of Cypermethrin oral administration alone and with natural protectors on sperm cell abnormalities (%) of albino rats at different time periods: B- Tail Abnormalities

| Group time | Control  | Group A      | Group B      | Group C       | Group D       |
|------------|----------|--------------|--------------|---------------|---------------|
| 30         | 3.0±0.44 | 33.8±1.80a** | 13.6±1.07b** | 12.2±0.37b**  | 9.0±1.00bc**  |
| 45         | 2.8±0.37 | 35.0±3.27a** | 13.0±1.00b** | 12.4±0.92b**  | 7.6±1.07bcd** |
| 60         | 3.4±0.50 | 41.6±1.20a** | 16.6±1.02b** | 10.6±0.67bc** | 10.0±0.54bc** |

<sup>a</sup>: Significantly different from control group; <sup>b</sup>: Significantly different from CYP group; <sup>c</sup>: Significantly different from CYP+GRE group; <sup>d</sup>: Significantly different from CYP+VTC group; \*\*: Highly significant (p<0.01)

defines that Cypermethrin oral administration to male rats for a period of 60 days (CYP-group) produced highly significant decrease in the epididymal sperm cell concentration along the three periods of the experiment in comparison with control group. It is also evident that co-administration of either garlic extract (CYP+GRE) or L-ascorbic acid (CYP+VTC) with Cypermethrin oral gavage resulted in highly significant elevation in the concentration of rat spermatozoa; just at days 45 and 60 of the experiment when each protector was given separately and at days 30, 45 and 60 when the two elements were given in combination (CYP+GRE and VTC). The ameliorative effects of each of garlic extract and L-ascorbic acid were statistically even out, while the protective effect of their combination (CYP+GRE and VTC) was only slightly evidenced at 45 and 60 days of the experiment.

Regarding the sperm cell head and tail abnormalities, tabulated data in (Table 5, 6) revealed that oral Cypermethrin administration to male rats (CYP group) for 60 days caused highly significant increases in both the head and tail abnormalities at all periods of the experiment; as compared with control group. sperm head abnormalities were in the form of detached heads (headless sperms) truncated heads (bulb heads) and elongated heads (banana heads). The sperm tail abnormalities were in the form of curved, bent and coiled tail-sperms. Data also cleared that concomitant administration of Cypermethrin and garlic extract or L-ascorbic acid; each as a separate element (CYP+GRE or CYP+VTC), or together in a combined form (CYP+GRE and VTC); produced highly significant reduction in the frequencies of both head and tail abnormalities, compared with the corresponding

values of abnormalities in (CYP) group. It is also obvious that the ameliorative effects of both garlic extract and L-ascorbic acid against head abnormalities were equivalent except at day 60 of experiment, where the ameliorative effect of garlic extract exceeded that of L-ascorbic acid and even that of the combination of both protectors. The reverse was true in case of tail abnormalities; where L-ascorbic acid exerted highly significant ameliorative effect more than that of garlic extract at day 60 of the experiment.

### Morphological Findings of Testes

#### Grossly

The testes of Cypermethrin-treated rats were hypotrophied, showing external pitecheal haemorrhages all over the whole experiment.

#### Thirty Days Post-Exposure

##### Microscopically

The testicular tissue of Cypermethrin alone-treated rats exhibited degeneration and desquamation of spermatocyte series and spermatids giant cells into the lumen of seminiferous tubules (SNT); with most of the spermatogonial cells (type 1, 2) showed pyknotic nuclei and necrobiotic changes in their cytoplasm. The interstitial connective tissue was clearly thickened by oedema (Fig. 1). Testes of rats treated with both garlic extract and Cypermethrin showed features of regeneration of most SNT germinal epithelium; beside apparently normal interstitial tissue (Fig. 2). In contrast, those rats treated with ascorbic acid plus Cypermethrin showed only mild regeneration of SNT germinal epithelium and many tubules still had desquamated spermatocyte series in their lumen (Fig. 3). Amazingly, testes of rats received the combination of both protectors plus Cypermethrin still suffered congestion in the interstitial blood vessels in some areas, focal thickness of the interstitial connective tissue and slight regeneration of some SNT germinal epithelium and spermatocytic series (Fig. 4).

#### Forty-Five Days Post-Exposure

Testes of rats treated with Cypermethrin alone exhibited the same picture as mentioned before in the 30 days exposure period; in addition to separation of SNT away from each others due to destruction of the connecting interstitial tissue (Fig. 5). The testicular tissue of rats received garlic

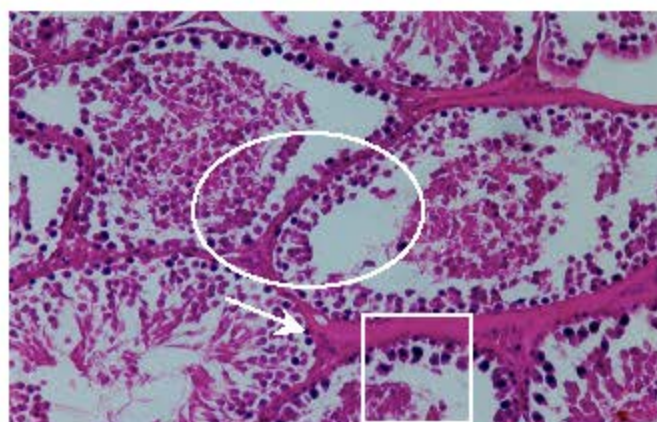


Fig. 1: Testis of CYP alone-treated rat (30 days) showing severe degeneration of SNT spermatocyte series, spermatid giant cells (o), necrobiotic changes and nuclear pyknosis of germinal epithelium (□) and thick oedematous interstitial connective tissue (†) (H & E, X 20)



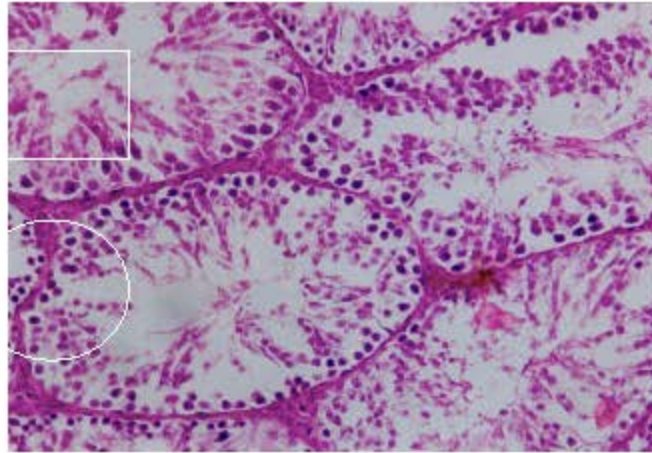


Fig. 2: Testis of CYP+GRE treated rats (30days) showing regeneration of most seminiferous tubules germinal epithelium, primary and secondary spermatocytes and spermatids (□), with reduction of the thickness of interstitial tissue (↓) and presence of intact spermatozoa in the lumen of the tubules (○) (H & E, X 20)

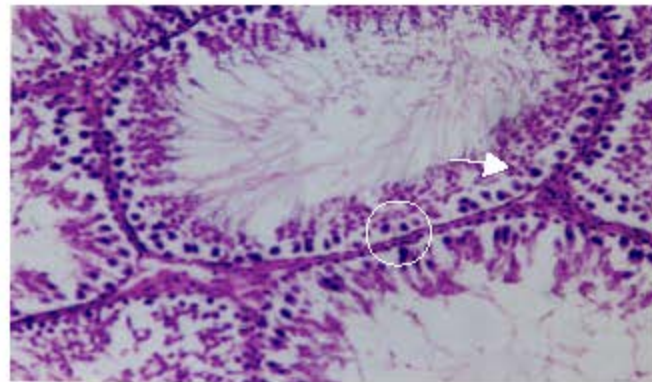


Fig. 3: Testis of Vit. C + Cyper.-treated rat (45 days) showing slight regeneration in some SNT; other SNT still suffered degenerated spermatozoa and spermatozoa giant cells collected in their lumen (H and E, X 20)

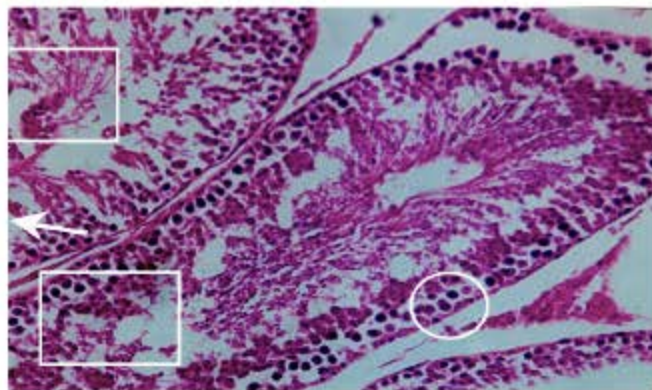


Fig. 4: Testis of CYP +GRE and VTC treated rats (30 days) showing slight congestion in the interstitial blood vessels in some areas (○), focal thickness of the interstitial connective tissue (↓) and slight regeneration of some SNT germinal epithelium and spermatocyte (□) (H and E, X 20)

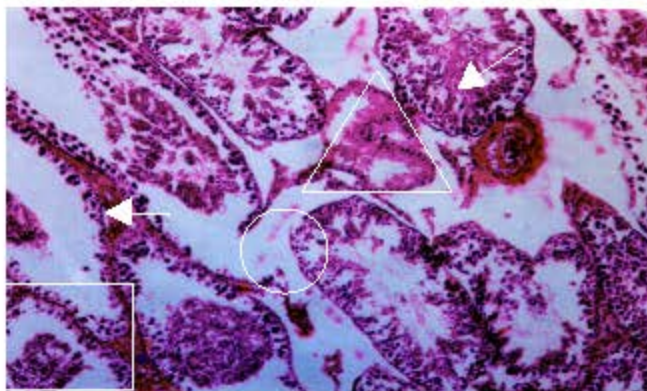


Fig. 5: Testis of CYP alone treated rats (45 days) reveals disintegration of interstitial tissue and separation of some SNT (▲), presence of spermatid giant cells (○), necrosis in the germinal epithelium with desquamated cells gathered in the lumen (□). The interstitial artery is congested and shows endothelial proliferation (Δ) (H and E, X10)

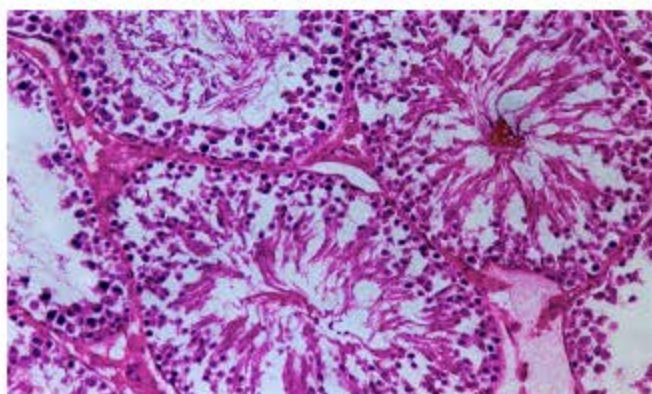


Fig. 6: Testis of CYP+GRE treated rats (45 days) showing almost complete regeneration of SNT germinal epithelium and the spermatocyte series and normal interstitial connective tissue (H and E, X 20). CYP GRE and VTC treatment (45 days) showed similar picture, Figure not included

extract and Cypermethrin (Fig. 6) and the testicular tissue of rats received combined protectors treatment showed almost complete regeneration in SNT epithelium and also SNT were firmly connected by thin intact interstitial tissue. Rare blood vessels were sometimes filled with eosinophilic serous fluid. In those rats treated with ascorbic acid and Cypermethrin, the testes displayed slight regeneration in some SNT; other SNT still suffered desquamated epithelial cells which collected in their lumen. Some tubules showed spermatid giant cells with increase in secondary spermatocytes, while other SNT exhibited loss of secondary spermatocytes layer beside large number of spermatid giant cells. Atrophy and detachment of adjacent SNT tubules from the interstitial tissue was obvious (Fig. 7).

#### Sixty Days Post-Exposure

Rats dosed with Cypermethrin alone exhibited more or less similar testicular lesions to those recorded in 30 days and 45 days periods of exposure; in addition to dilatation and congestion of the

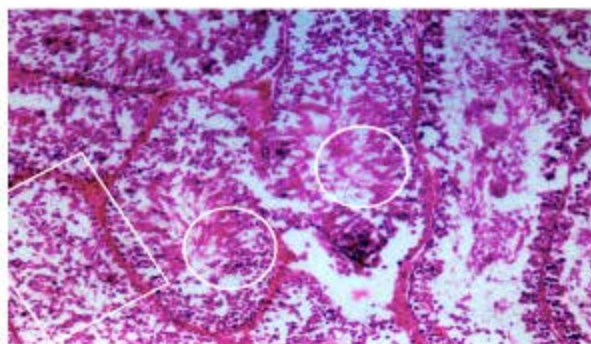


Fig. 7: Testis of CYP + VTC treated rat (45 days) showing slight regeneration in some SNT (□); other SNT still suffered degenerated spermatozoa and sperm giant cells collected in their lumen (○) (H and E, X 20)

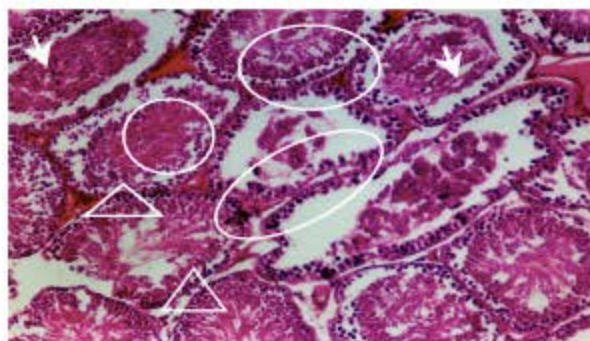


Fig. 8: Testes of CYP alone-treated rats (60 days) showing severe degeneration and desquamation of SNT germinal epithelium with desquamated cells gathered in the lumen (○), dilatation and congestion of the testicular large blood vessels (Δ) with interstitial oedema (↓) (H and E, X10)

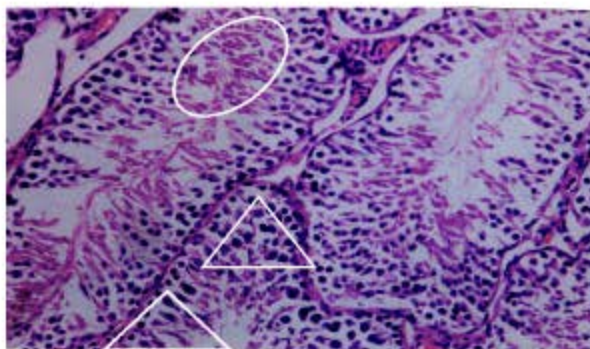


Fig. 9: Testis of CYP+GRE treated rats (60 days) showing moderate regeneration of epithelium of most SNT, with separated sperm giant cells into their lumen (Δ). Interstitial oedema with congestion and dilatation of interstitial blood vessels were also noticed in some fields (○) (H and E, X20)

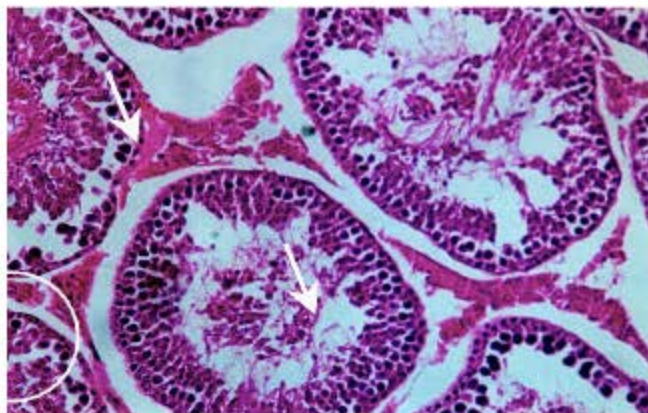


Fig. 10: Testis of CYP+VTC treated rats (60 days) showing regeneration features in cells of most SNT (c), but with separation of the tubules from each others (▲) (H and E, X20)

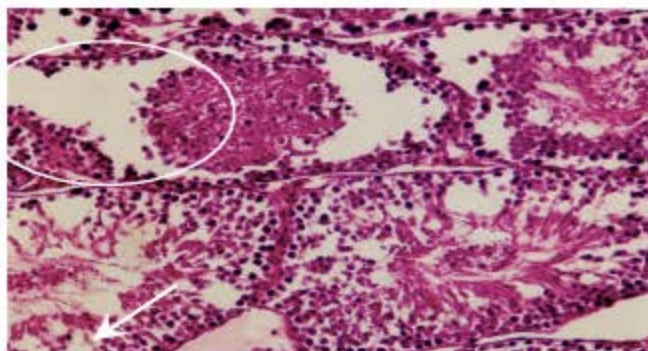


Fig. 11: Testis of CYP + GRE and VTC treated rats (60 days) days showing slight regeneration of most SNT epithelium. Many germinal epithelial layers of SNT were observed degenerated and desquamated and collected in their lumen (c). Very little interstitial oedema was observed (▲) (H and E, X20)

testicular blood vessels (Fig. 8). Testicular tissues of rats received garlic extract with Cypermethrin showed moderate regeneration of epithelium of most SNT; with separated spermatid giant cells into their lumen. Interstitial oedema with congestion and dilatation of interstitial blood vessels were also noticed in some fields (Fig. 9). Testes of rats administered ascorbic acid with Cypermethrin showed regeneration features in cells of most SNT. However, there was separation of the tubules from each others (Fig. 10). The combined protector treatment with Cypermethrin failed to produce complete regeneration of most SNT epithelium. Many germinal epithelial layers of SNT were observed degenerated and desquamated. Very little interstitial oedema was occasionally observed (Fig. 11).

## DISCUSSION

Pesticide exposure is associated with infertility. There is much concern that exposure to environmental contaminants causes decreased sperm counts, impairment of sperm motility, reduced fertilization ability, producing abnormal sperm in men and wildlife (Elbetieha *et al.*, 2001). The results of the present study revealed that oral administration of Cypermethrin at a dose of 55.1 mg kg<sup>-1</sup> b.wt. (1/5 LD<sub>50</sub>) for 60 successive days to male white rats induced deleterious effects on male fertility as

elucidated by the significant decrease in testicular index weight, sperm mass motility and spermatozoal concentration in the epididymis; beside the significant increase in the percentage of dead sperms and sperm head and tail abnormalities.

The observed decrease in testicular index weight of male rats in this study may be attributed partly to the direct cytotoxic action of the insecticide on testes, as revealed by histopathological changes in the testicular tissue of disintegrated germinal epithelium, spermatocytes, spermatids and immature sperms. Such decrease could also be referred to the reduced testosterone synthesis and disruption of normal androgen status (Abd-Allah, 1995).

In agreement with our results are those reported by Hassan *et al.* (1993), El-Ashmawy *et al.* (1993), Essawy *et al.* (1994), Abd-Allah (1995), Yousef *et al.* (2003a) and El-Demerdash *et al.* (2004), who recorded significant reduction in the index weight of testes of exposed animals following exposure to Cypermethrin or other closely related type-II pyrethroids. Opposite to our result was that of Elbetieha *et al.* (2001) who recorded increased absolute weight of testes in Cypermethrin-exposed male rats.

Regarding the spermatozoal parameters of male rats treated with the insecticide Cypermethrin over a period of 60 days; it was shown that the pyrethroid induced significant decrease in sperm mass motility, live spermatozoa and spermatozoal concentrations; while the percentage of sperm abnormalities displayed a significant elevation.

Present results are in accordance with the results reported by Hassan *et al.* (1993), El-Ashmawy *et al.* (1993), Essawy *et al.* (1994), Abd-Allah (1995), Elbetieha *et al.* (2001), Yousef *et al.* (2003a) and El-Demerdash *et al.* (2004) who found that long-term exposure to synthetic pyrethroid insecticides produced significant decrease in the percentage of sperm motility, live sperms, concentration of sperm cells and significant increase in the sperm cells abnormalities; including head and tail morphology.

The observed decrease in male fertility parameters following exposure to Cypermethrin could be partly explained by the fact that the pesticide acted directly on the testes; leading to degenerative and necrobiotic changes in spermatogonial and spermatocytes and/or could influence the androgen biosynthesis pathway. The other explanation is that the neurotoxic agents like Cypermethrin, acting directly on the brain, hypothalamus or anterior pituitary gland might indirectly affect the testes through interfering with the hypothalamo-hypophyseal control function and will possibly affect sexual activity.

The direct cytotoxic action of Cypermethrin was confirmed through our histopathological results recorded in the testes of treated rats; which denoted the presence of necrobiotic changes extensively observed in the spermatogonial germ cells as well as spermatocytes and spermatids in the seminiferous tubules; with detachment of degenerated cells in the lumen of seminiferous tubules and congestion of testicular vessels.

These findings are in accordance with Sobhy (1991) and Hassan *et al.* (1993) who reported that pyrethroids cause severe degenerative and necrotic pathological lesions in the seminiferous tubules, so the tubules may be seen lined with a layer of Sertoli cells, then the degeneration observed increases to cause severe hypoplasia and complete necrosis. Also, the destructed interstitial tissue and the separation of adjacent seminiferous tubules observed in testes of treated rats at the 45th and 60th of the experiment resemble to certain extent those recorded by Abd-Allah (1995) who observed widely separated destructed seminiferous tubules from each other at the 60th day of experiment. Likely, Cypermethrin was found to reduce fertility in male rats through affecting on testosterone, Follicle-Stimulating Hormone (FSH) and Luteinizing Hormone (LH) as well as the number of cell layers of the seminiferous tubules (Elbetieha *et al.*, 2001).

Pyrethroids also can interact competitively with androgen receptors and Sex Hormone Binding Globulin (SHBG) causing disruption of the endocrine system by mimicking the effect of the female

hormone, estrogen, leading to lowered sperm counts (Eil and Nisula, 1990; Go *et al.*, 1999); therefore, Cypermethrin was suggested to be one of the endocrine disruptors (Yousef *et al.*, 2003b).

El-Ashmawy *et al.* (1993) declared that the reduction in sperm cell concentration could also be attributed to reduction in meiotic index of the testicular cells, which might be due to the capability of pyrethroid insecticides to penetrate through the Blood-Testes Barrier (BTB) and hence gaining access to the germ cells of the seminiferous tubules.

Moreover, Bhunya and Pati (1988) reported a significant increase in the proportion of dead and abnormal sperms in mice after exposure to the pesticide Cypermethrin. On the other hand, the sperm abnormalities could be assumed as a consequence of mutational changes in genes responsible for spermatogenesis or could be due to changes in differentiation during gene expression involving transcriptional stages and translation of the genetic message (Pant *et al.*, 1995).

The significant protective action of fresh garlic extract against reproductive toxicity of Cypermethrin in male rats could be explained on the basis of several cooperating aspects. First of all, the capability of garlic to inhibit potential mutagens that interact with DNA molecules in testicular germ cells and hence prevent the production of deformed or mutated spermatozoa. Sinclair (2000) mentioned that DNA damage in germ cells may lead to the production of mutated spermatozoa, which in turn may result in spontaneous abortion, malformations and/or genetic defects in the offspring.

A second factor may be that garlic biological constituents could amazingly hinder the process of lipid peroxidation and the formation of lipid peroxides and other Reactive Oxygen Species (ROS) in the semen and/or the plasma membranes of spermatozoa, owing to the strong antioxidant as well as free radical scavenging properties of garlic organosulphur ingredients. Amagase (1997) and Awazu and Horie (1997) declared that garlic extract and its organosulfur components exhibit a powerful capability to scavenge ROS and inhibit the formation of lipid peroxides.

The results also showed that vitamin C (L-ascorbic acid) displayed an ameliorative effect on different spermatozoal endpoints of Cypermethrin-treated rats. Our data agree with those recorded by Ishihara *et al.* (2000) who reported significant improvement in rat spermatogenesis and by Yousef *et al.* (2003b) who declared enhancement of rabbit sperm characteristics, Lipid Peroxidation (LPO), ejaculate volume, sperm concentration, total sperm output, sperm motility index, total motile sperm, packed sperm volume, initial hydrogen ion concentration (pH) and reduction of abnormal and dead sperm frequencies. The ameliorating effect of vitamin C (injected intraperitoneally) was also recorded by Khan and Sinha (1993) against changes in sperm count and sperm head morphology in mice; as a result of treatment with different types of pesticides. They reported that out of the three doses of vitamin C used; the middle and higher ones (20 and 40 mg kg<sup>-1</sup> body wt/day, respectively) afforded more significant amelioration, whereas the lower dose (10 mg kg<sup>-1</sup> body wt/day) of this vitamin (equivalent to the human therapeutic dose) was the least effective. Ascorbic acid also acts as an electron donor and/or hydrogen atom donor; this characteristic makes it a potent antioxidant. Because ascorbic acid is more reactive than polyunsaturated lipids by a factor of about 10<sup>3</sup>, it competes well with poly-unsaturated lipids in membranes against peroxy radicals (Niki and Noguchi, 1997). Moreover, Cederberg *et al.* (2001) revealed that vitamin C is a hydrophilic molecule that can scavenge several radicals, among them the hydroxyl radical and it acts as an important co-factor for many detoxification as well as scavenging enzymes.

Vitamin C, acting as a potent antioxidant and free radical scavenger, further helps reconstitution of the depleted GSH as it ameliorates the oxidative stress and enhance, as an important enzyme co-factor, the activities of GSH detoxification enzyme system hence promotes normal sperm cell production (Grajeda-Cota *et al.*, 2004).

Based on the aforementioned obtained data, we conclude that Cypermethrin is a toxic chemical pesticide that produced significant reproductive toxicity in treated male rats as revealed by the severely affected spermatozoal parameters and the altered testicular index weight and the characteristic

morphopathological lesions observed. Furthermore, this investigation fundamentally cleared the protective and/or ameliorative role played by garlic extract and vitamin C; either each alone or in combination against the reproductive toxicological features of Cypermethrin. This study also indicated that garlic extract was often more efficient in its protective action against the insecticide than vitamin C and that the combination of both natural elements was in most cases more advantageous than when each one was administered alone.

## REFERENCES

- Abd-Allah, A.E.Y., 1995. Effect of some pesticides on reproduction. Ph. D Thesis, (Toxicology) Fac. Vet. Med. Cairo University.
- Amagase, H., 1997. Antioxidant and radical scavenging effects of aged garlic extract and its constituents. In: Antioxidants and Disease. Th Congress on Clinical Nutrition. Banff, Alberta, Canada, pp: 28.
- Awazu, S. and T. Horie, 1997. Antioxidants in Garlic. II. Protection of Heart Mitochondria by Garlic Extract and Diallyl Polysulfide from the Doxorubicin-induced Lipid Peroxidation. In: Nutraceuticals: Designer Foods III Garlic, Soy and Licorice, Lanchance, P.P. (Ed.), pp: 131-138.
- Bancroft, J.D., A. Stevens and D.R. Turner, 1996. Theory and Practice of Histopathological Techniques. 4th Edn, Churchill Livingstone, Eidinburg, London, Melbourne, New York.
- Barth, A.D. and R.J. Oko, 1994. Abnormal Morphology of Bovine Spermatozoa. Iowa State University Press/Am., pp: 8-12.
- Bearden, H.J. and J.W. Fuquay, 1980. Applied Animal Reproduction Reston Publishing Co., Inc. Reston, Virginia, pp: 157-165.
- Bhunya, S.P. and P.C. Pati, 1988. Genotoxic effects of a synthetic pyrethroid insecticide, cypermethrin, in mice *in vivo*. Toxicol. Lett., 41: 223-230.
- Cederberg, J., C.M. Simsan and U.J. Eriksson, 2001. Combined treatment with vitamin E and vitamin C decreases oxidative stress and improves fetal outcome in experimental diabetic pregnancy. Ped. Res., 49: 755-762.
- Eil, C. and B.C. Nisula, 1990. The binding properties of pyrethroids to human skin fibroblast androgen receptors and to sex hormone binding globulin. J. Steroid Biochem., 35: 409-414.
- El-Ashmawy, I.N., A.D. Zakaria; S.M.A. Hemed, S. El-Fikey and Y.A. Hussein, 1993. Cytotoxic effects of the pyrethroid insecticide (Matox) with reference to its influence on the reproductive hormone. Vet. Med. J., Giza, 3: 125-130.
- Elbetieha, A., S.I. Da'as, W. Khamas and H. Darmari, 2001. Evaluation of the toxic potential of cypermethrin pesticide on some reproductive and fertility parameters in the male rats. Arch. Environ. Contam. Toxicol., 41: 522-528.
- El-Demerdash, F.M., M.I. Yousef, F.S. Kedwanyand and H.H. Baghdadi, 2004. Role of  $\alpha$ -tocopherol and beta-carotene in ameliorating the fenvalerate-induced changes in oxidative stress, hemato-biochemical parameters and semen quality of male rats. J. Environ. Sci. Health B., 39: 443-459.
- Essawy, G.S., H.A. El-Banna, H.M. Sobhy and Y.S. Ibrahim, 1994. Influence of Lambda-cyhalothrin on fertility and blood parameters in male rats. Vet. Med. J., Giza, 42: 71-75.
- Go, V. *et al.*, 1999. Estrogenic potential of certain pyrethroid compounds in the MCF-7 human breast carcinoma cell Line. Environ. Health Perspect., 107: 3.
- Grajeda-Cota, P., M.V. Ramirez-Mares and E.G. de Mejia, 2004. Vitamin C protects against *in vitro* cytotoxicity of cypermethrin in rat hepatocytes. Toxicology *in vitro*, 18: 13-19.
- Hassan, A.B., G.A. Soliman, A.A. Farag and H.M. Sobhy, 1993. Effect of the synthetic pyrethroids sumicidin and S- 3206 on male rat fertility. Vet. Med. J., Giza, 41: 33-38.

- Imai, J., N. Ide, S. Nagae, T. Moriguchi, H. Matsuura and Y. Itakura, 1994. Antioxidant and radical scavenging effects of aged garlic extract and its constituents. *Planta Med.*, 60: 417-420.
- Ishihara, M., M. Itoh, K. Miyamoto, S. Suna, Y. Takeuchi, I. Takenaka and F. Jitsunari, 2000. Spermatogenic disturbance induced by di-(2-ethylhexyl) phthalate is significantly prevented by treatment with antioxidant vitamins in the rat. *Int. J. Androl.*, 23: 85-94.
- Khan, P.K. and S.P. Sinha, 1993. Antimutagenic efficacy of higher doses of vitamin C. *Mutat. Res.*, 298: 157-161.
- Lee, K.W., H.J. Lee, Y.J. Surh and C.Y. Lee, 2003. Vitamin C and cancer chemoprevention: Reappraisal. *Amer. J. Clin. Nutr.*, 78: 1074-1078.
- Manna, S., D. Bhattacharyya, T.K. Mandal and S. Das, 2004. Repeated dose toxicity of alfa-cypermethrin in rats. *J. Vet. Sci.*, 5: 241-245.
- Manson, M.M., H.W.L. Ball, M.C. Barrett, H.L. Clark, D.J. Judah, G. Williamson and G.E. Neal, 1997. Mechanism of action of dietary chemoprotective agents in rat liver: Induction of phase I and II drug metabolizing enzymes and aflatoxin B1 metabolism. *Carcinogenesis*, 18: 1729-1738.
- Niki, E. and N. Noguchi, 1997. Protection of Human Low-Density Lipoprotein from Oxidative Modification by Vitamin C. In: *Vitamin C in Health and Disease*, Packer, L. and J. Fruchs (Eds.). Marcel Dekker, Inc., New York, pp: 183-192.
- Pant, N., S.C. Srivastava, A.K. Prasad, R. Shanker and S.P. Srivastava, 1995. Effects of carbaryl on the rats male reproductive system. *Vet. Hum. Toxicol.*, 37: 421-425.
- Sakr, S.A., 2003. Pyrethroid inhalation-induced hepatotoxicity in albino rats. Thesis, Umm Al-Qura University, Makkah, Saudi Arabia.
- Sinclair, S., 2000. Male infertility: Nutritional and environmental considerations. *Altern. Med. Rev.*, 5: 28-38.
- Singh, S.P., S.K. Abraham and P.C. Kesavan, 1995. *In vivo* radioprotection with garlic extract. *Mutat. Res.*, 345: 147-153.
- Sobhy, H.M., 1991. Effect of Sumicidin and S-3206 insecticides (synthetic pyrethroids) on foetal development and male fertility in rats. Ph.D Thesis, (Pharmacology). Cairo University.
- Tinoco, R. and D. Halperin, 1998. Poverty, production and health: Inhibition of erythrocyte cholinesterase via occupational exposure to organophosphate insecticides in Chiapas. Mexico. *Arch. Environ. Health*, 53: 29-35.
- Yang, C.S., T.J. Smith and J.Y. Hong, 1994. Cytochrome-P450 enzymes as targets for chemoprevention against chemical carcinogenesis and toxicity: Opportunities and limitations. *Can. Res.*, 54: 1982-1986.
- Yousef, M.I., F.M. El-Demerdash, Kamel and K.S. Al-Salhen, 2003a. Changes in some hematological and biochemical indices of rabbits induced by isoflavones and cypermethrin. *Toxicology*, 189: 223-234.
- Yousef, M.I., G.A. Abdallah and K.I. Kamel, 2003b. Effect of ascorbic acid and Vitamin E supplementation on semen quality and biochemical parameters of male rabbits. *Anim. Reprod. Sci.*, 76: 99-111.