



Research Journal of
**Veterinary
Sciences**

ISSN 1819-1908



Academic
Journals Inc.

www.academicjournals.com

Cryptococcosis: A Garded Mycosis Threat

J.B. Nayak, M.N. Brahmabhatt, C.V. Savalia, M. Pal and B.B. Bhandari
Department of Veterinary Public Health, Veterinary College,
Anand Agricultural University, Anand-388 001, India

Abstract: Cryptococcosis is an important cosmopolitan, infectious, mycotic disease of man and animals caused by the yeast, *Cryptococcus neoformans* which exists as saprobe in the environment. The disease is also known as Busse Buschke's disease, European blastomycosis or Torulosis. The disease was considered as sleeping disease in older days became an awakening giant in present era. It is predicted that for every million patients with AIDS, 50,000-1,00,000 will contract cryptococcosis. Moreover, cryptococcosis is difficult to eradicate because of lack of data on the prevalence of infection in specific areas sporadic nature of the disease and occurrence in severe immunosuppression status.

Key words: Cryptococcosis, global incidence, animal infection, prevalence, diagnosis

INTRODUCTION

Cryptococcosis is an important cosmopolitan, infectious, mycotic disease of man and animals caused by the yeast, *Cryptococcus neoformans* which exists as saprobe in the environment. The disease is also known as Busse Buschke's disease, European blastomycosis or Torulosis. The disease was considered as sleeping disease in older days became an awakening giant in present era. It is predicted that for every million patients with AIDS, 50,000-1,00,000 will contract cryptococcosis. Moreover, cryptococcosis is difficult to eradicate because of lack of data on the prevalence of infection in specific areas, sporadic nature of the disease and occurrence in severe immunosuppression status. The infection commonly starts following inhalation of the organism. The primary infection may remain localized into the lungs or disseminate throughout the body. Over a period of more than one hundred years ago, in 1894 *Cryptococcus neoformans* was discovered when this yeast was isolated independently from peach juice in Italy, by Sanfelice (1984) and from the tibial lesion of a patient in Germany by Busse (1894) and Buschke (1895), simultaneously. Sanfelice studied the pathogenicity of organisms in laboratory animals and gave name as *Saccharomyces neoformans* to the pathogen. In 1905, Von Hansemann presented the first case of cryptococcal meningitis. Reports of infection due to other species of *Cryptococcus* (*C. albidus* and *C. laurentii*) are extremely rare. In 1902, Frothingham reported cryptococcosis in a horse. There are reports of cryptococcosis in wide variety of animals. The first case of cryptococcosis in man directly attributed to the environment contaminated with pigeon droppings (Littman, 1959). The first record of association of the yeast with mastitis of goat and buffalo was established by Pal (1975), respectively (Pal, 1996). Environmental prevalence of *C. neoformans* was reported in New Zealand for the first time by Pal and Baxter (1985). The study on cryptococcosis in man and animals was reviewed keeping in view its association in AIDS patients (Nayak *et al.*, 2010).

Corresponding Author: J.B. Nayak, Department of Veterinary Public Health, Veterinary College,
Anand Agricultural University, Anand-388 001, India

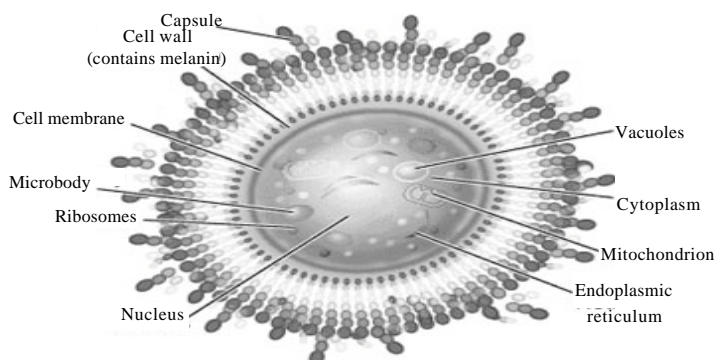


Fig. 1: An idealized depiction of *C. neoformans* cell

Etiology

Of total 37 species of genus *Cryptococcus*, *C. neoformans* is the major human pathogen. A few cases of cryptococcosis caused by other species viz., *C. albidus* and *C. laurentii* have been reported in the literature. *Cryptococcus neoformans* is a non-motile, Gram-positive basidiomycetous, encapsulated round to oval yeast like fungus measuring 4 to 6 μm in diameter (Fig. 1). A 1 to 30 μm thick mucoid polysaccharide capsule surrounds the yeast cells. In its natural environment the capsule is thinner and the yeast smaller, while thicker capsules tend to be found in the infected tissues of the patients.

The polysaccharide capsule, the phenol oxidase enzyme of *C. neoformans* and the ability of organisms to grow at 37°C, are major virulence factors contributing to the pathogenesis. Recent data suggest that phospholipase enzyme may also play role in virulence of the pathogen. *C. neoformans*, encapsulated, usually spherical yeast of which two varieties are recognized, *C. neoformans* var. *neoformans* and *C. neoformans* var. *gattii*. *C. neoformans* var. *neoformans* may possess five serotypes A, B, C, D and AD (Pal and Dave, 2006).

Taxonomic Classification

Kingdom = Fungi
Phylum = Basidimycota
Subphylum = Basidimycotina
Order = Sporidiales
Family = Sporidiobolaceae
Genus = *Cryptococcus*
Species = *C. neoformans*, *C. albidus* and *C. laurentii* (Lodder, 1970)

Pathogenesis

The pathogenesis of cryptococcosis is determined by three broad factors-the status of the host defense mechanism, the virulence of the strain of *C. neoformans* and the size of the inoculum. To be classified as a pathogen, an organism must be able to cause infection under certain conditions. By this definition, *C. neoformans* can certainly be classified as a pathogen. The factors that make *C. neoformans* a pathogen can be divided into two major groups. The first comprises the basic characteristics needed to establish an infection and survive in the human host; the second comprises the virulence factors that affect the degree of pathogenicity. To enter the alveolar spaces of the lungs and establish pulmonary

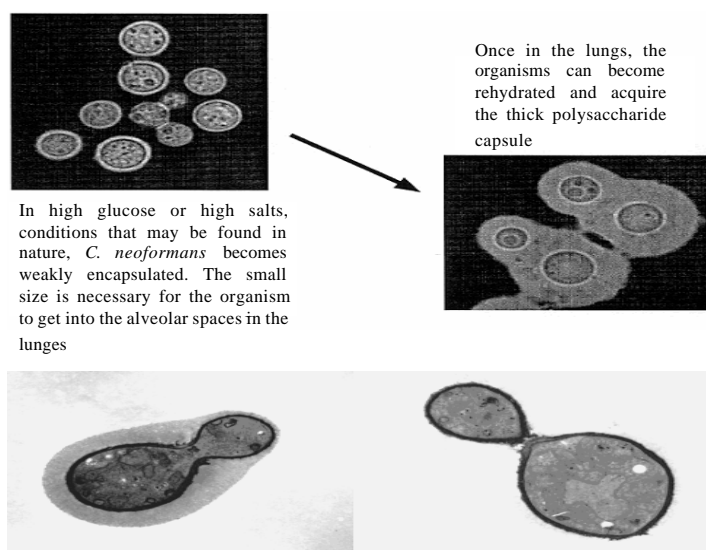


Fig. 2: *C. neoformans* showing the polysaccharide capsule

infection, an organism must produce viable forms smaller than 4 μm in diameter. The typical vegetative form of *C. neoformans* is the yeast form with a cell diameter of 2.5 to 10 μm . The organism can also undergo sexual reproduction and since it is a basidiomycete (*Filobasidiella neoformans*), it forms basidiospores. Once inside the lungs, the yeast cells become rehydrated and acquire the characteristic polysaccharide capsule (Fig. 2). The virulence factors are capsule, cryptococcal products, melamin production, mannitol production and potential factors such as superoxide dismutase, proteases, phospholipase B and lysophospholipase and organism's ability to grow at 37°C are probably the dominant virulence factors. The evidence indicates that the capsule is a key virulence factor for *C. neoformans* having antiphagocytic and immunosuppressive effect. Phenol oxidase enzyme produces melanin, which protects against oxidant stress. (Chander, 2002). *Cryptococcus* sp. reaches humans by inhalation of smaller forms (1-2 μ) of aerosolized yeast cells. The organism remains dormant in the lungs until the immune system weakens and then reactivates and disseminate to the central nervous system, other body sites such as the skin, bone, joint, eye and heart. In dairy animals, the yeast is introduced into the udder by contaminated milking machines or contaminated intramammary preparations. Primary cutaneous infection may occur by accidental inoculation of the fungus into the skin following trauma (Pal and Dave, 2006). The organism primarily transmitted via the respiratory route and the alveolar macrophages ingest the yeast. Phagocytosis and destruction of the unencapsulated yeast cells readily occur, whereas encapsulated organisms are more resistant to phagocytosis. A cryptococcal polysaccharide capsule has antiphagocytic properties. The antiphagocytic properties of the capsule block recognition of the yeast by phagocytes and inhibit leukocyte migration into the area of fungal replication.

Ecology

Current information suggests that in nature, the two-varieties of *C. neoformans* reside in separate environmental niches. *C. neoformans* var. *neoformans* found worldwide in soil

contaminated by bird droppings (especially pigeons), roosting sites and rotting vegetation. Birds do not become infected, probably because their relatively high body temperature. Cryptococcus can be found in pigeon GI tract (Staib and Schulz-Dieterich, 1984). However, birds are likely to distribute the yeasts in nature. In avian nesting areas, the yeast cells possess minimal capsules and hence the cells are dry and easily aerosolized. In this state, the yeast cells are smaller and capable of being inhaled to the level of the alveolus. In recent years, a natural association has been recognized between *C. neoformans* var. *gattii* and flowering eucalyptus trees, such as the red river gum tree (*Eucalyptus camaldulensis*) and forest red gum (*E. tereticornis*). These trees have been widely exported around the world. *C. neoformans* var. *gattii* never cultured from bird guano (Ellis and Pfeiffer, 1990).

Epidemiology

Cryptococcosis is an important cosmopolitan, highly infectious mycozoosis. It causes considerable morbidity and mortality in humans as well as animals (Mitchell and Perfect, 1995). Infection is more commonly encountered in persons receiving prolonged treatment with steroids, antibiotics and cytotoxic drugs. Disease occurs in all hosts (immuno-competent as well as immuno-compromised hosts, particularly suffering with AIDS, leukemia. The fungus is neurotropic in nature and has a predilection for CNS, it may also infect other organs (Thomas, 2004). Cryptococcosis is the second most common opportunistic mycosis in HIV infected persons. No significant difference exists in the incidence of infection related to age, race, or occupation (King, 2005).

The disease is reported from many countries of world including India (Kwon-Chung and Bennett, 1992). Global incidence of cryptococcal meningoencephalitis in AIDS patients ranges from 2-33% (Table 1).

Transmission via organ transplantation has been reported when infected donor organs were used. Cryptococcosis, one of the AIDS defining infections, once considered as sleeping disease, became an awakening giant within a couple of years and has now been predicted as the Mycosis of the future with a predilection that for every million patients with AIDS, 50,000-100,000 will contract cryptococcosis. Chronic meningitis is a main manifestation of this infection. During three successive studies each of four years expanding of a period of 12 years (1992 – 2004) at All India Institute of Medical Science, increase rate from 20 to 49% of cryptococcosis in AIDS patients was observed (Banerjee, 2005) (Fig. 3). However, a review in 2001, on the status of cryptococcosis in India strangely reveals more cases from the northern part, where the HIV prevalence rate is low compared to high HIV prevalent states in the southern or western India. Since then the overall scenario has not changed much. This discrepancy probably is due to under reporting and misdiagnosis of cases. As cryptococcosis is not considered as Notifiable disease its real picture regarding prevalence and incidence is not available.

Table 1: Global Incidence of cryptococcosis in AIDS patients

Country	Incidence (%)
Central Africa	2-33
Zaire (Kinshasa)	6-25
USA	7-8
Netherlands	6.1
Brazil	5.8
France	5.8
Belgium	5.4
UK	3.2
Germany	5.0
India	6-8

Pal and Dave (2006)

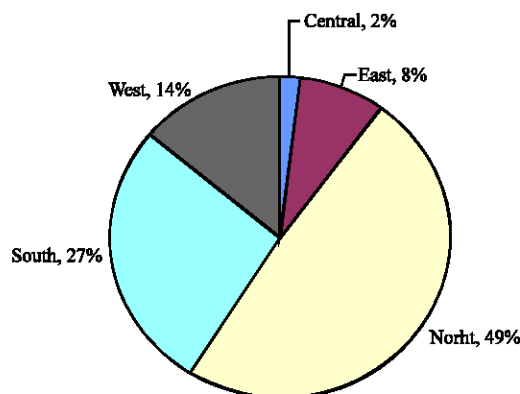


Fig. 3: Cryptococcus clinical report: 1941-2001

The avian droppings and soil are considered the main reservoir of *C. neoformans* where it may survive for more than 20 years (Nayak *et al.*, 2010). It is estimated that 1g of dry pigeon excreta may contain up to 50 million viable cells of *C. neoformans* (Pal, 2007). The visits to such natural site may become a point source of infection to man and animal. The zoo attendants, pet bird keepers, bird enthusiast, pigeon breeder and person engaged in the cleaning of historical buildings, old monuments are more likely to expose to cryptococcal infection (Thomas, 2004). Pulmonary cryptococcosis in pigeon handlers and primary cutaneous cryptococcosis in bird fanciers are reported from India and other countries (Baes and van Cutsem, 1985).

As such there is no sex difference in occurrence of diseases but as the males are more frequently engaged in vulnerable occupations, the reports are more in men than in women. Moreover, no age difference in natural infection as disease has been reported from all age groups. Sequelae of the disease are meningitis, which may lead to permanent neurological damage and mortality rate is about 12% (CDC, 2005).

Clinical Spectrum

Human Infections

The incubation period is usually 2 to 4 weeks. The lungs are initial site of infection to precipitate. Patients exhibit signs of dyspnea and cough, but asymptomatic infections and meningitis also occur. Fever is often absent in patients with pulmonary cryptococcosis which is characterized with cough, chest pain, sputum production, pneumonia, night sweats and weight loss. Cutaneous lesions are found in approximately 10 per cent of the cases and they are characterized as nodules, papules, vesicles, tumors, ulcers, abscesses and superficial granuloma. Endophthalmitis, vulvar lesion and osseous lesions were also observed at times (Pal and Dave, 2006).

In human the clinical manifestations of cryptococcosis are varied and can be divided into different forms on the basis of involvement of a system as: *Cerebro meningial cryptococcosis*, *Pulmonary cryptococcosis*, *Visceral cryptococcosis*, *Osseous cryptococcosis*, *Cutaneous cryptococcosis*, *Mucocutaneous cryptococcosis* etc. (Kwon-Chung and Bennett, 1992).

Cerebro meningial cryptococcosis

Maher and Mwandumba, (1994) reported cryptococcal meningitis in 31 patients (16 Men, 15 Women, aged 19-54 years) during July 1991-January 1993, with the clinical presentation of

headache (97%), neck stiffness (74%), fever (61%) and altered consciousness (58%). Mwaba *et al.* (2001) studied neurological manifestation of 149 patients with AIDS during 1990-1998 and found that 149 patients (21.5%) showed meningeal cryptococcosis. Kanaly *et al.* (2007) reported cerebellar cryptococcoma in 58 years old man having resected squamous cell carcinoma of the larynx and pulmonary nodules.

Pulmonary cryptococcosis

Gugnani *et al.* (1972) isolated *Cryptococcus neoformans* from sputum of zoo attendant in the Delhi Zoological Park. *Cryptococcus neoformans* was cultured from 13 (3%) of 469 specimen examined from respiratory tract with bronchopulmonary disease in Delhi (Randhawa and Pal, 1977). *Cryptococcus neoformans* was cultured from sputum (5.71%) having bronchopulmonary disorders (Thomas, 2004). Out of 159 cases of pulmonary fungal infections, 13 (8%) were diagnosed as cryptococcosis (Newson and Hardy, 1982). Cryptococcal pulmonary infections in six out of seven patients in USA were reported (Mille *et al.*, 1990). Muller and Fishman (2003) reported four cases of pulmonary cryptococcosis in solid organ recipients (kidney n = 2, heart n = 2). Zhao *et al.* (2003) in China noted a case of pulmonary cryptococcosis in a child.

Visceral cryptococcosis

In USA, Zappi *et al.* (1995) reported visceral cryptococcosis in a 44 year old man whose PM examination revealed cryptococcal pneumonia and *C. neoformans* was demonstrated in the liver, spleen and other organs (Yamazaki *et al.*, 1999). The rate of cryptococcosis 0.14 to 0.26% studied epidemiology of visceral mycoses cases from 1969-1994 in Japan.

Osseous cryptococcosis

Go Vender *et al.* (1988) described localized cryptococcal osseous lesions in two cases. Witte *et al.* (2000) isolated cryptococcal organism in a 68 year old man having pain and swelling in the left elbow by fine needle aspiration biopsy.

Cutaneous cryptococcosis

Murakawa *et al.* (1996) diagnosed *C. neoformans* infection in 202 AIDS patients in USA, of these, 12(5.9%) cases expressed cutaneous lesions. *Cutaneous cryptococcosis* was reported in women (aged 32 years) having multiple papules with a central hemorrhagic crust on her face (Baker and Reboli, 1997). Thomas (2004) reported *Cutaneous cryptococcosis* in 7.69% cases.

Animal Infections

Cryptococcosis has been recorded in wide variety of animals.

Cattle and Buffalo

The yeast is known to cause mastitis in cow, buffalo, goat and sheep (Pal and Mehrotra, 1983). Monga *et al.* (1970) reported cryptococcal mastitis in cows by isolating the fungus from 5 out of 432 milk samples examined in Haryana. Similarly, *C. neoformans* was isolated from the mastitic milk (6.67% samples) of Holstein-Friesian cows from Gujarat (Thomas, 2004).

Horse

An extensive cryptococcal nasal granuloma in a 13 year old stallion was reported in Australia (Roberts *et al.*, 1981).

Dog and Cat

Majority of cases are reported in cats and dogs. Both the sexes are affected and 10 months to 14 years of age are infected. Maximum cases have been diagnosed in large breeds such as Boxer, Doberman, Pinscher, German shepherd and Great Dane. The sick dog exhibits signs of depression, anorexia, fever, lethargy, nasal discharge, cough, vomiting, dyspnea, intermittent diarrhea, weight loss, conjunctivitis, dilated pupil, optic neuritis, chorioretinitis, facial paralysis, ataxia, neck pain, head tilt, lameness, paraplegia, paresis, seizure, superficial lymphadenomelany and ulcerated lesions in the skin. About 25% of the reported cases of canine cryptococcosis show cutaneous lesions (Pal and Dave, 2006).

Birds

The highest incidence of *C. neoformans* from pigeon was reported upto 79.3% (Colom-Valiente *et al.*, 1997) and in Gujarat (India) the prevalence rate of *C. neoformans* in avian excreta was 5.21% (Thomas, 2004). Emmons *et al.* (1977) isolated *C. neoformans* from 16 of 19 premises and 63 of 111 specimens of pigeon droppings sites but not isolated from 20 pigeon examined. It appeared to grow as a saprophytes. Franger (1962) isolated cryptococci from faeces of 48 pigeons, 13 fowl, 7 pheasants, 10 housemartins, 4 jackdaws and 3 chaffinches.

Eucalyptus Trees

Cryptococcus neoformans var. *gatti* has been consistently isolated from decaying wood of eucalyptus trees (Sorrell *et al.*, 1996). In India, *C. neoformans* var *gatti* also isolated from eucalyptus trees (Chakrabarti *et al.*, 1997).

Cryptococcosis in AIDS Patients

Cryptococcus neoformans is the major cause of meningitis in AIDS patients (Thomas, 2004). Chronic meningitis is a main manifestation of disease. The disease can be considered as a Mycosis of the future as from Every million patients with AIDS 50,000-100,000 will contract cryptococcosis (Banerjee, 2005). Out of 431 patients with HIV infection, 15 were diagnosed positive for cryptococcal meningitis (Kalra *et al.*, 1999). Inverarity *et al.* (2002) studied 229 patients in Thailand and of this 15% showed cryptococcal meningitis. The pandemic of AIDS has lead to a simultaneous and dramatic rise in the incidence of cryptococcal disease and a reduction in the average age of affected patients (King, 2005).

Nosocomial Infection

Nosocomial fungal infection have increasing day by day and cryptococcosis is one of them. There is very few documentation regarding the cryptococcosis through nosocomial infections. *Cryptococcal meningitis* was diagnosed in a 92 day old boy who was not HIV infected and survived after treatment and from history it was found that mother was HIV infected with cryptococcal meningitis and died 14 days postpartum. There was no possible other source for cryptococcal infection in infant excluding mother-to-child transmission or through medical personnel and the instruments (Sirinavin *et al.*, 2004). Nosocomial infection from one positive patient to patient in adjacent bed due to airborne route or through respiratory care procedure performed with contaminated instruments by medical personnel may play vital role in spread of cryptococcosis (Roberts *et al.*, 1981).

Occupational Disease

Cryptococcosis is not associated to specific occupation. However, the types of occupations at grater risk in which workers are exposed to large amounts of dust containing

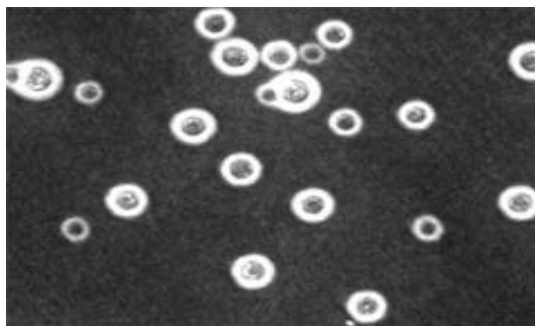


Fig. 4: Thick, wide, circular, refractile, gelatinous capsules

soil contaminated with avian excreta. Gugnani *et al.* (1972) isolated *C. neoformans* from the sputum of employee of Zoological Garden of Delhi. Emmons *et al.* (1977) reported pneumonitis among workers engaged in cleaning, demolishing old buildings or towers, which had sheltered pigeons for many years. Two cases of Cryptococcosis were diagnosed in young boys who had been trapping pigeons (Procknow *et al.*, 1965). Two miners died and on post-mortem showed HIV associated Cryptococcosis (Charalambous *et al.*, 2001).

Cryptococcosis as Zoonosis

Wegner and Staib (1983) reported cryptococcal infection of CNS in a 69 year old female patient who had kept the budgerigar as a pet bird. Baes and van Cutsem (1985) diagnosed cryptococcosis in a 53 year old male pigeon fancier with long standing asthma.

Cryptococcal infection in a 28 year old male AIDS patients with meningoencephalitis. The epidemiological associations showed habitat of *C. neoformans* in fecal matter of birds (Bohle *et al.*, 1986).

Diagnosis

Diagnosis of Cryptococcosis can be made by direct microscopic examination of clinical specimens in India ink or Nigrosin stain (10%) for the demonstration of thick, wide, circular, refractile, gelatinous capsule (Fig. 4). The capsule appears as hollow capsule (Pal, 1989).

Cultural Examination

The Clinical specimen such as CSF, sputum, skin exudates, nasal exudates, urine, pus, tissue aspirate should be inoculated on selective medias like Pal's sun flower seed media and Bird seed agar, incubate at 30°C. Development of light to dark brown color colonies helps in rapid identification of *C. neoformans*. The microscopic morphology of the isolate is studied in NARAYAN stain is used to study morphology of cultural isolate.

Histopathology

The necropsy or biopsy tissues can be processed by using Mayer's mucicarmine, Masson-Fontana, Periodic Acid-Schiff (PAS) to demonstrate cryptococcal yeast cells.

Animal Pathogenicity Test

Swiss albino mice weighing 25 g are employed to verify the pathogenicity of the organism. Culture is inoculated through intracerebral or intraperitoneal route, mice will die in 7-10 days (Pal, 2005).

Molecular Test

The PCR, RAPD and PMS (Pyloris Mass Spectrometry) are used in epidemiological studies.

Serological Tests

Latex agglutination test is a immunological test that is performed to detect the circulating cryptococcal antigen in serum, CSF, urine and Broncho Alveolar Lavage (BAL). This test is used to monitor the prognosis of the patient.

Treatment

The treatment depends on the involvement of organ and host immune status. Ketoconazole (100-200 mg day⁻¹) is found effective for known for non-meningeal cryptococcosis. *Cryptococcal meningitis* have been successfully managed with intraconazole (50-400 mg day⁻¹). A combination therapy of Amphotericin B (0.7 mg/kg/day IV) and flucystosine(150 mg/kg/dayPO) is suggested for 2 weeks to treat cryptococcal meningitis after two weeks therapy is shifted to Fluconazole (400 mg/kg/day) for 10 week (Chander, 2002). Prostate may serve as a protective site for *C. neoformans* therefore urine samples obtained after prostatic massage may direct the physicians to prolong fluconazole therapy (Mitchell and Perfect, 1995). Clotrimazole and Fluconazole found to be most effective chemotherapeutic agent (Thomas, 2004).

Animal cryptococcosis can be treated with Amphotericin B (0.25-1.00 mg kg⁻¹, IV), Flucytosine (25-50 mg kg⁻¹, orally), Fluconazole (2.5-5.0 mg kg⁻¹, orally), Itraconazole (10 mg kg⁻¹, orally) and Ketoconazole (10 mg kg⁻¹, orally).

Prevention and Control

Cryptococcosis is difficult to eradicate because of Lack of data on the prevalence of infection in specific areas, sporadic nature of the disease and occurrence in immunosuppression status (Mitchell and Perfect, 1995). Immunocompromised persons should avoid visiting avian habitats and dusty environment. The workers at pet bird shop, pigeon farming and zoological garden should apply face mask at work to avoid inhalation of infectious agent. Decontamination of avian excreta and habitat with 5 per cent formalin is imperative to prevent the spread of agent in the environment.

Future Scope of Research

Future research should be directed on the development of novel vaccine, Effective immunotherapy and chemotherapy. Generation of proper data on prevalence and surveillance of the disease also required.

REFERENCES

- Baes, H. and J. van Cutsem, 1985. Primary *Cutaneous cryptococcosis*. Dermatologica, 171: 357-361.
- Baker, D.J. and A.C. Reboli, 1997. *Cutaneous cryptococcosis*. N. Engl. J. Med., 336: 998-998.
- Banerjee, U., 2005. Progress in diagnosis of opportunistic infections in HIV/AIDS. Indian J. Med. Res., 121: 395-406.
- Bohle, C., M. Sinn, E. Werner and F. Staib, 1986. *Cryptococcus neoformans* meningoencephalitis in AIDS. Klin. Wochenschr, 64: 165-172.
- Buschke, A., 1895. Uber eine durch Coccidien Hervergerufene Krankheitdes menschen. Dtsch. Med. Wochenschr, 21: 14-14.

- Busse, O., 1894. Über parasitäre zelleinschlüsse und ihre zuchtung. Zentralbl. Bakteriolog., 16: 175-180.
- CDC., 2005. *Cryptococcosis*: Technical Information. CDC., USA.
- Chakrabarti, A., M. Janata, P. Kumar, L. Chatha, A. Kaushal and A.A. Padhye, 1997. Isolation of *Cryptococcus neoformans* var. *gatti* from *Eucalyptus camaldulensis* in India. J. Clin. Microbiol., 35: 3350-3352.
- Chander, J., 2002. Medical Mycology. 2nd Edn., Mehta Publishers, New Delhi, India.
- Charalambous, S., G.J. Churchyard, J. Murray, K.M. De Cock and E.L. Corbett, 2001. Persistent radiological changes following military tuberculosis in miners exposed to silica dust. Int. J. Tuberculosis Lung Dis., 5: 1044-1050.
- Colom-Valiente, M.F., M. Alberdi, I. Meseguer and J.M. Torreso-Rodriguez, 1997. Isolation of *Cryptococcus neoformans* from environmental samples in Alicante. Revista Iberoamericana De Micologia, 14: 63-64.
- Ellis, D.H. and T.J. Pfeiffer, 1990. Natural habitat of *Cryptococcus neoformans* var. *Gati*. J. Clin. Microbiol., 28: 1642-1644.
- Emmons, C.W., C.H. Binford, J.P. Utz and K.J. Kowng-Chung, 1977. Medical Mycology. 3rd Edn., Lea and Febiger, Original from the University of Wisconsin-Madison, Philadelphia, ISBN: 0812105664.
- Franger, P., 1962. The finding of cryptococci in excrements of birds. Cesk. Epidemiol. Microbiol. Immunol., 11: 135-139.
- Go Vender, S., V. Ganpath, R.W. Charles and K. Cooper, 1988. Localized *Osseous cryptococcal* infection. Report of 2 cases. Acta Orthopaedica, 59: 720-722.
- Gugnani, H.C., N.P. Gupta and J.B. Shrivastava, 1972. Presence of *Cryptococcus neoformans* in Delhi Zoological Park and its recovery from the sputum of an employee. Indian J. Med. Res., 60: 182-185.
- Inverarity, D.,Q. Bradshaw, P. Wrightand and A. Grant, 2002. The spectrum of hiv-related disease in rural central thailand. Southeast Asian J. Trop. Med. Public Health, 33: 822-831.
- Kalra, S.P., D.S. Chadha, A.P. Singh, P.C. Sanchetee and A.K. Mohapatra, 1999. Cryptococcal meningitis in acquired immunodeficiency syndrome. J. Assoc. Phys. India, 47: 958-961.
- Kanally, C.W., L.A. Selznick, T.J. Cummings and D.C. Adamson, 2007. *Cerebellar cryptococcoma* in a patient with undiagnosed sarcoidosis: Case report. Neurosurgery, 60: 571-571.
- King, J.W., 2005. *Cryptococcosis*. Mycoses, 48: 122-125.
- Kwon-Chung, K.J. and J.E. Bennett, 1992. *Cryptococcosis*. In: Medical Microbiology, Kwon-Chung, K.J. and J.E. Bennett (Eds.). Lea and Febinger Philadelphia, pp: 397-446.
- Littman, M.L., 1959. Cryptococcosis (Torulosis): Current concepts and therapy. Am. J. Med., 27: 976-998
- Lodder, J., 1970. The Yeasts: A Taxonomic Study. North Holland Publishing Co., Amsterdam.
- Maher, D. and H. Mwandumba, 1994. Cryptococcal meningitis in lilongwe and Blantyre, Malawi. J. Infect., 28: 59-64.
- Mille, W.T.Jr., J.M. Edelman and W.T. Miller, 1990. Cryptococcal pulmonary infection in patients with AIDS. Radiology, 175: 725-728.
- Mitchell, T.G. and J.R. Perfect, 1995. *Cryptococcosis* in the era of AIDS-100 years after the discovery of *Cryptococcus neoformans*. Clin. Microbiol. Rev., 8: 515-548.
- Monga, D.P., L.N. Mohapatra and D.S. Kalra, 1970. Bovine mastitis caused by *Cryptococcus neoformans*. Indian J. Med. Res. 58: 1203-1205.

- Muller, N.J. and J.A. Fishman, 2003. Asymptomatic pulmonary *Cryptococcosis* in solid organ transplantation. *Trans. Infect. Dis.*, 5: 140-143.
- Murakawa, G.J., R. Kerschmann and T. Berger, 1996. Primary *Cutaneous cryptococcus* infection and AIDS. *Arch. Dermatol.*, 132: 545-548.
- Mwaba, P., J. Mwansa, C. Chintu, J. Pobee, M. Scarborough, S. Portsmouth and A. Zumla, 2001. Clinical presentation natural history and cumulative death rates of 230 adults with primary *Cryptococcal meningitis* in Zambian AIDS patients treated under local conditions. *Postgraduate Med. J.*, 77: 769-773.
- Nayak, J.B., M.N. Brahmabhatt, C.V. Savalia, Y.A. Chatur and C.D. Bhong, 2010. *Cryptococcosis* in man and animals. *Vets Commun.*, 5: 32-36.
- Newson, B.D. and J.D. Hardy, 1982. Pulmonary fungal infection. *J. Thoracic Cardiovascular Surgery*, 83: 218-226.
- Pal, M., 1975. A study of *Cryptococcosis* with special reference to its epidemiology. Ph.D. Thesis, University of Kolkatta.
- Pal, M. and B.S. Mehrotra, 1983. *Cryptococcal mastitis* in dairy animals. *Mykosen*, 26: 615-616.
- Pal, M. and M. Baxter, 1985. Isoaltion of *Cryptococcus neoforman* from the environment using a simplified sunflower seed medium. *Proc. N.Z. Microbiol. Soc.*, 29: 155-158.
- Pal, M., 1989. *Cryptococcus neoformans* var *neoformans* and munia birds. *Mycoses*, 32: 250-252.
- Pal, M., 1996. Recent Advances in *Cryptococcosis*. In: *Fungal Infections-An Update*, Laxmi, V., (Ed.). Nizam's Institute of Medical Sciences, Hyderabad, India.
- Pal, M., 2005. Importance of zoonoses in public health. *Indian J. Anim. Sci.*, 75: 586-591.
- Pal, M. and P. Dave, 2006. *Cryptococcosis*: A global fungal zoonosis. *Intas Polyvet*, 7: 412-420.
- Pal, M., 2007. *Zoonoses*. 2nd Edn., Satyam Publishers, Jaipur, India, pp: 183-184.
- Procknow, J.J., J.R. Binford, J.W. Rippon, C.F. Diener and F.L. Archer, 1965. A severe mastitis problem associated with *Cryptococcus neoformans* in a large dairy herd. *Am. J. Vet. Res.*, 13: 121-128.
- Randhawa, H.S. and M. Pal, 1977. Occurance and significance of *Cryptococcus neoformans* in the respiratory tract of patients with bronchopulmonary disorders. *J. Clin. Microbiol.*, 5: 5-8.
- Roberts, M.C., R.H. Sutton and D.K. Lovell, 1981. A protracted case of *cryptococcal granuloma* in a stallion. *Aust. Vet. J.* 57: 287-291.
- Sanfelice, F., 1984. Contributo alla morfologia e biologia dei blastomiceti. *Ann. Igene. Sper.*, 4: 463-495.
- Sirinavin, S., U. Intusoma and S. Tuntirungsee, 2004. Mother-to-child transmission of *Cryptococcus neoformans*. *Pediatr. Infect. Dis. J.*, 23: 278-279.
- Sorrell, T.C., A.G. Brownlee, P. Ruma, R. Malik, T.J. Pfeiffer and D.H. Ellis, 1996. Natural environmental sources of *Cryptococcus neoformans* var *Gatti*. *J. Clin. Microbiol.*, 34: 1261-1263.
- Staib, F. and J. Schulz-Dieterich, 1984. *Cryptococcus neoformans* in faecal matter of birds kept in cages control of *C. neoformans* habitats. *Zentrablat Bakteriologie Hygiene Abstract Origin B*, 179: 179-186.
- Thomas, L., 2004. Prevalence of *Cryptococcus neoformans* in man, animal and environment. M.Sc. Thesis, Veterinary Public Health, Anand Agricultural University.

- Wegner, H.H. and F. Staib, 1983. Mortal cryptococcosis in a pet bird enthusiast. Case report. A contribution of the pathology, diagnosis and epidemiology of cryptococcosis. Zentralblatt Bakteriologie, Microbiologie, Hygiene, A256: 231-238.
- Witte, D.A., I. Chen, J. Brandy, L.D. Truong and M.L. Strowski, 2000. Cryptococcal osteomyelitis. Acta Cytologica, 44: 815-818.
- Yamazaki, T., H. Kume, S. Murase, E. Yamashita and M. Arisawa, 1999. Epidemiology of visceral mycoses. J. Clin. Microbiol., 37: 1732-1738.
- Zappi, E., M. Zappi and F. Zugibe, 1995. Disseminated *Cryptococcosis* and sudden death report of an autopsy case. Am. J. Forensic Med. Pathol., 16: 38-41.
- Zhao, S.Y., Z.F. Jiang and Z.H. Ren, 2003. Causes and diagnostic procedure of diffused lung disease in 28 children. Zhonghua Er Ke Za Zhi, 41: 542-545.