



Research Journal of  
**Veterinary  
Sciences**

ISSN 1819-1908



Academic  
Journals Inc.

[www.academicjournals.com](http://www.academicjournals.com)

## Pathological Changes and the Effects of Ascorbic Acid on Lesion Scores of Bursa of Fabricius in Broilers Under Chronic Heat Stress\*

W. Aengwanich

Stress and Oxidative Stress Research Unit,  
Faculty of Veterinary Medicine and Animal Science,  
Mahasarakham University, Maha Sarakham 44000, Thailand

**Abstract:** The present study was undertaken to understand the effect of chronic heat stress on the pathological changes and the effects of ascorbic acid on lesion scores of bursa of Fabricius in broilers. Broilers were maintained at an environmental temperature of  $33\pm 1^\circ\text{C}$  for 21 days. Broilers were divided into 4 groups, i.e., broilers received ascorbic acid in their diets at 0 (group 1), 200 (group 2), 400 (group 3) and 800 (group 4)  $\text{mg kg}^{-1}$ , respectively. The pathological changes and effects of ascorbic acid on lesion scores of bursa of Fabricius in heat stressed broilers were investigated. The results revealed the following information: After broilers were under heat stress for 21 days, bursa of Fabricius shrunk. The cortex area of the bursa increased while the medulla area decreased. Moreover, the number of lymphocytes in both the cortex and medulla of the bursa in broilers under heat stress decreased. The lesion scores of the bursa of the broilers in groups 2 and 3 were lower than those of group 1 ( $p < 0.05$ ). These results indicate that heat stress had an effect on the bursa of Fabricius and ascorbic acid at  $200 \text{ mg kg}^{-1}$  in a diet was a suitable level to improve the abnormality in the bursa of Fabricius in broilers under chronic heat stressed.

**Key words:** Ascorbic acid, pathology, bursa of Fabricius, broilers, chronic, heat stress

### INTRODUCTION

Bursa of Fabricius is an important ovallike shaped gland which is found at the proctodaeal region of the coeca in birds (Whittow, 2000). This organ is known to be a primary lymphoid organ in birds where immunologically competent cells are produced, while it is also a secondary or peripheral lymphoid organ which produces antibodies (Tsuji and Miyoshi, 2001).

Heat stress is one of the most important factors adversely affecting overall poultry production in the tropics. Moreover, it was reported to cause a reduction in antibody production in chickens (Zulkifi *et al.*, 2000; Marshaly *et al.*, 2004; Naseem *et al.*, 2005). Furthermore, Bartlett and Smith (2003) reported that high temperature affects the development of a specific immune response in chickens. Ascorbic acid has been widely used to reduce stress in chickens, because it decreases corticosterone levels in the blood circulation (Nockels *et al.*, 1973; Sheila and Cheryl, 1978). Amakye-Anim *et al.* (2000) reported that ascorbic acid improved immuno responsiveness and increased disease resistance in chickens by optimizing the function of the immune system. Moreover, ascorbic acid can moderate the activity of the B-cell.

However, information concerning the effects of ascorbic acid on pathological changes of bursa of Fabricius in broilers under chronic heat stress is limited. As such, the purpose of this study was to conduct an experiment related to the effects of ascorbic acid on pathological changes and lesion scores of bursa of Fabricius in broilers under chronic heat stress. Results from this preliminary study would provide fundamental knowledge for using ascorbic acid to reduce heat stress in poultry production in tropical regions.

## MATERIALS AND METHODS

One hundred and forty four, symptomatically disease- free, day old broiler chicks were obtained from a commercial hatchery. They were incubated for 21 days before being placed in layer cages. Experiments began after a 7 day adaptation period in cages at 26-28°C environmental temperatures. The chicks were fed on standard broiler starter (commercial feed) with continuous light and water supply.

The experiment was designed as a Randomized Complete Block Design (RCBD) with 4 treatments, i.e., supplementation of diets with ascorbic acid (99.5% purity; Fluka) at 0, 200, 400 and 800 mg kg<sup>-1</sup>. On day 1 of the experimental period (28 days of age), broilers were transferred into environmentally controlled housing and kept in wire - floored layer cages. All broilers were subjected to a 5 h episode of heat stress at 33±1°C each day. Relative humidity was 60-70%. A total mixed diet (Table 1) with the four levels of ascorbic acid was fed *ad libitum*.

On day 21 of the experimental period (49 days of age), three randomly selected broilers per experimental unit were killed by cervical dislocation. The bursa of Fabricius of each bird was collected. The organs were fixed in 10% buffered formalin, then sectioned and stained with Hematoxylin and Eosin (H and E) for microscopic examination (Luna, 1968). Pathological changes of bursa of Fabricius were studied. Before comparing the effect of ascorbic acid on the bursa of Fabricius in heat stressed broilers, lesion scores of abnormal findings in the bursa of broilers were performed. The lesion scores revealed the following: Score 0 (100%): Normal finding; Score 1 (80%): Some follicles in the bursa shrunk. Space between the follicle septum was found; Score 2 (60%): Each lobule in the bursa shrunk more than those in score 1 and each follicle was separated from the others. The space between follicles within the bursa was larger than the spaces in score 1; Score 3 (40%): Each follicle in the bursa shrunk more than the follicles in score 2. Each follicle in the bursa was completely separated from the others and the space between follicles within the bursa was larger than the spaces in score 2 (Fig. 1).

Data were analyzed by using of the ANOVA procedure of Statistical Analysis System (SAS, 1990). Means were separated by Duncan's multiple range tests (Duncan, 1955). The level of significance was determined at p<0.05.

Table 1: Total mixed feed ration for growing broilers

Ingredients	Percentages of mixed
Corn No. 2	62.60
Fish meal 58%	10.00
Soy bean meal china 44%	23.00
Rice bran oil	2.96
Premix*	0.50
Alimethionine	0.25
L-Lysine	0.14
Limestone	0.50
Salt	0.20
DCP (Rock 16%)	0.30
DCP (Rock 18%)	0.15
Total	100.00

\*: Each kg contains 50 Vitamin A D<sub>3</sub>E 500/1000 (400 mg); Vitamin E<sub>20</sub> (2,000 mg); Vitamin B<sub>1</sub> (180 mg); Vitamin B<sub>2</sub> (100 mg); Vitamin B<sub>3</sub> (310 mg); Vitamin B<sub>12</sub> 1% (120 mg); Vitamin K<sub>3</sub> 51% (100 mg); Niacin, B<sub>5</sub> (2, 700 mg); D- calciumpentothinate (1,000 mg); Folic acid (50 mg); Biotin, 2% (750 mg); Chlorine chloride 50% (20, 000 mg); Magnesium sulphate (19,600 mg); Potassium iodide, KI (44 mg); Cobalt chloride (35 mg); Zinc Oxide, ZnO (1,980 mg); Copper sulphate, Cu<sup>2+</sup>. 5 H<sub>2</sub>O (210 mg); ferrous sulphate, Fe. 7H<sub>2</sub>O (40,600 mg); Selenium (150 mg); Dicalcium phosphate (406.37 g)

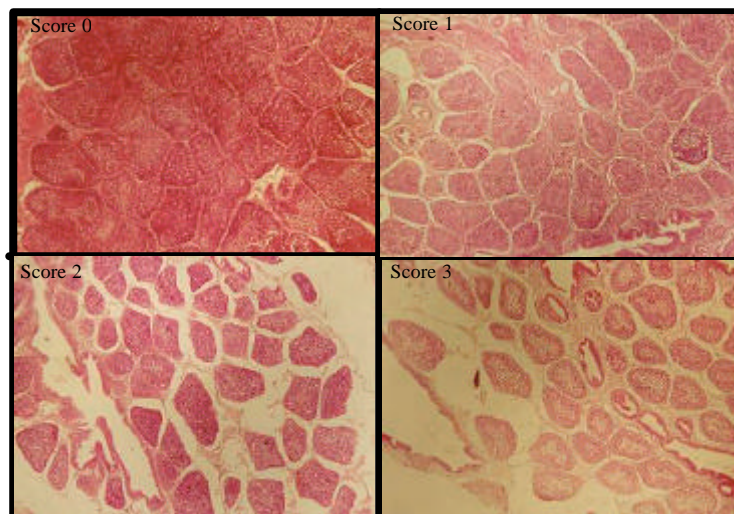


Fig. 1: Lesion scores of bursa of Fabricius in broilers were under chronic heat stress (H and E, 5X)

## RESULTS AND DISCUSSION

### Pathological Changes of Bursa of Fabricius in Broilers under Chronic Heat Stress

Generally, bursa of Fabricius in the test broilers were composed of many follicles in the gland (Fig. 2a). Each follicle was divided into 2 parts i.e., cortex and medulla by basement membrane. Large lymphocytes (P), medium lymphocytes (L), lymphoblast (B), reticular-cells (E) and mesenchymal cells (M) were found in the medulla and cortex, respectively (Fig. 2b). The general histological structure of the bursa of Fabricius in this study was similar to those in many other studies such as embryo chick (Ackerman, 1962), native geese (Gulmez and Aslan, 1999), chicken (Tsuji and Miyoshi, 2001; Cui *et al.*, 2004; Dimitrov and Nikiforov, 2005). After broilers were under heat stress for 21 days, the bursa of Fabricius shrunk. The cortex area of the bursa increased while the medulla area decreased. Therefore, the ratio between the cortex and medulla area of the bursa of Fabricius in heat stressed broilers increased. Moreover, the number of lymphocytes in both the cortex and medulla of the bursa in broilers under heat stress decreased (Fig. 2d). This phenomenon was in accordance with the report of Maqbool *et al.* (2004), they found that bursa of heat stressed broiler were atrophied.

Effects of ascorbic acid on lesion scores of bursa of Fabricius in broilers under chronic heat stress.

Lesion scores of the bursa of Fabricius of broilers receiving ascorbic acid at 200 and 400 mg kg<sup>-1</sup> in their diets were lower than control group (0 mg kg<sup>-1</sup>) (p<0.05).

This phenomenon demonstrates that after broilers were exposed to high ambient temperature, corticosterone stored in the adrenal cortex was released into the blood circulation to help the broilers increase their metabolism (Richard, 1998). Corticosterone caused bursa of Fabricius atrophy (Daghir, 1995). When heat stressed broilers received 200 and 400 mg kg<sup>-1</sup> of ascorbic acid in their diets, it decreased the corticosterone level in their blood circulation. As a result, the lesion scores of bursa of Fabricius of heat stressed broilers that received ascorbic acid at 200 and 400 mg kg<sup>-1</sup> were lower than the control group. This result was in contrast with the report of Maqbool *et al.* (2004). They found that when heat stressed broilers received ascorbic acid, no specific pathological changes of bursa of Fabricius were observed.

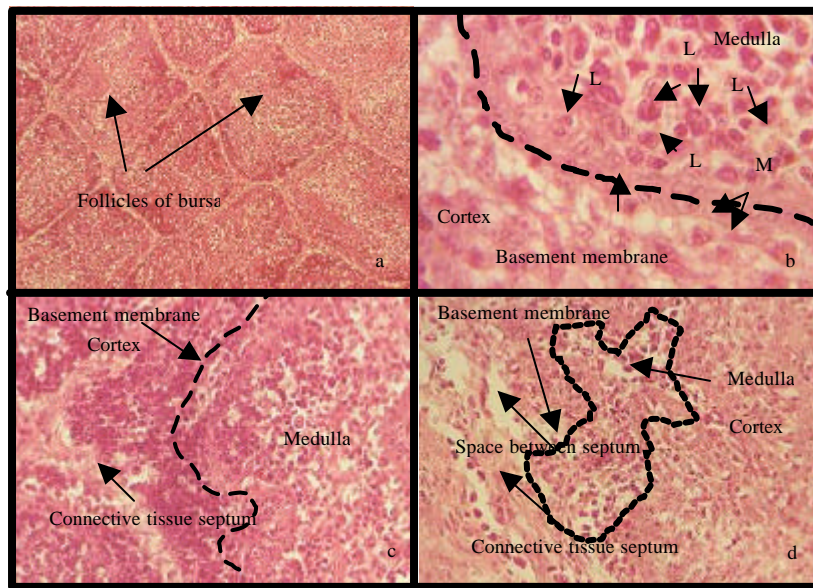


Fig. 2: Normal finding of bursa of Fabricius (H and E, 10X) (a); normal finding of cortex and medulla part of bursa of Fabricius that divided by basement membrane (H and E, 100X) (b); normal finding of each follicle in bursa of Fabricius (H and E, 40X)(c); characteristics in bursa of Fabricius (atrophy or shrinking) in broilers were under chronic heat stress (H and E, 40X)(d); (P = large lymphocyte, B = lymphoblast, L = medium lymphocyte, E = reticular cells, M = mesenchymal cells)

## CONCLUSIONS

Bursa of Fabricius shrinking in broilers maintained at  $33\pm 1^{\circ}\text{C}$  for 21 days was observed. The number of lymphocytes in both the cortex and medulla of bursa of Fabricius in heat stressed broilers decreased. When heat stressed broilers received ascorbic acids at 200 and 400  $\text{mg kg}^{-1}$  in their diets, lesion scores of bursa of Fabricius were lower than those of the control group. All above documents indicated that high environmental temperature caused atrophy to bursa of Fabricius in broilers and ascorbic acid at 200  $\text{mg kg}^{-1}$  was a suitable level for protection of the bursa of Fabricius in broilers under chronic heat stress.

## REFERENCES

- Ackerman, G.A., 1962. Electron microscopy of the bursa of Fabricius of the embryonic chick with particular reference to the lympho-epithelial nodules. *J. Cell Biol.*, 13: 127-146.
- Amakye-Anim, J., T.L. Lin, P.Y. Hester, D. Thiagarajan, B.A. Watkins and C.C. Wu, 2000. Ascorbic acid supplementation improved antibody response to infectious bursal disease vaccination in chickens. *Poult. Sci.*, 79: 680-688.
- Bartlett, J.R. and M.O. Smith, 2003. Effects of different levels of zinc on the performance and immunocompetence of broilers under heat stress. *Poult. Sci.*, 82: 1580-1588.
- Cui, H., P. Xi, D. Junliang, L. Debing and Y. Guang, 2004. Pathology of lymphoid organs in chickens fed a diet deficient in zinc. *Avian Pathol.*, 33: 519-524.

- Daghir, N.J., 1995. Poultry Production in Hot Climate. CAB International, Wallingford, UK., pp:101-123.
- Dimitrov, D.S. and I.P. Nikiforov, 2005. Histological and histochemical studies of Harderian gland, lacrimal gland and bursa of Fabricius in mulard ducks (*Anas sterilis*) with chlamydial infection. Bulgarian J. Vet. Med., 8: 119-127.
- Duncan, D.B., 1955. Multiple ranges and multiple F-test. Biometric, 11: 1-42.
- Gulmez, N. and S. Aslan, 1999. Histological and histometrical investigations on bursa of Fabricius and thymus of native geese. Trak. J. Vet. Anim. Sci., 23: 163-171.
- Luna, L.T., 1968. Manual of Histologic Staining Methods of the Armedforce Institute of Pathology. McGraw-Hill Book Company, New York, pp: 1-39.
- Maqbool, A., S.A. Khan, K. Khan, A. Aslam and B. Anwar, 2004. Effects of ascorbic acid and acetylsalicylic acid supplementation on performance of broiler chicks exposed to heat stress. Pak. Vet. J., 24: 109-112.
- Marshaly, M.M., G.L. Hendricks, M.A. Kalama, A.E. Gehad, A.O. Abbas and P.H. Patterson, 2004. Effect of heat stress on production parameters and immune response of commercial laying hens. Poult. Sci., 83: 889-894.
- Naseem, S., M. Younus, B. Anwar, A. Ghafoor, A. Aslam and S. Akhter, 2005. Effect of ascorbic acid and acetylsalicylic acid supplementation on performance of broiler chicks exposed to heat stress. Int. J. Poult. Sci., 4: 900-904.
- Nockels, C.F., G.A. Lopez and R.W. Phillips, 1973. Influence of vitamin A and C on corticosterone and carbohydrate metabolism in chickens. Poult. Sci., 52: 1261-1269.
- Richard, J.J., 1998. Physiological management and environmental triggers of the ascites syndrome. Poult. Int. Asia Pacif. Edn., 37: 28-33.
- SAS, 1990. SAS/STAT User's Guide: Statistics, Release 6.04 Edn., SAS Institute, Inc., Cary, NC.
- Sheila, K.S. and F.N. Cheryl, 1978. Effect of age, sex and ascorbic acid ingestion on chicken plasma corticosterone levels. Poult. Sci., 57: 527-533.
- Tsuji, T. and M. Miyoshi, 2001. A scanning and transmission electron microscopic study of the lymphoreticular framework in the chicken Fabricius' bursa. Med. Bull. Fukuoka Univ., 28: 63-75.
- Whittow, G.C., 2000. Sturkie's Avian Physiology. Academic Press, Florida.
- Zulkifi, I., M.T. Norma, D.A. Israf and A.R. Omar, 2000. The effect of early age feed restriction on subsequent response to high environmental temperature in female broiler chickens. Poult. Sci., 79: 1401-1407.