



Trends in  
**Medical Research**

ISSN 1819-3587



Academic  
Journals Inc.

[www.academicjournals.com](http://www.academicjournals.com)

## Biochemical and Histopathological Studies of Herbal Cream Against Uv Radiation Induced Damage

M.S. Ashawat, Saraf Shailendra and Saraf Swarnlata  
Institute of Pharmacy, Pt. Ravishankar Shukla University,  
Raipur (C.G.), 492010, India

**Abstract:** The present study was to prepare and characterized herbal cosmetic cream comprising extracts of *G. glabra*, *C. longa* (roots), seeds of *P. corlifolia*, *C. tora*, *A. catechu*, *P. granatum*, fruits of *E. officinale*, leaves of *C. asiatica*, dried bark of *C. zeylanicum* and fresh gel of *A. vera* for the protection of skin against UV induced aging. To investigate the antioxidant activity of cream formulations the UV radiation induced oxidative stress was generated in rats and protective effects were measured after topically applied ( $2 \text{ mg cm}^{-2} \text{ day}^{-1}$ ) for thirty days. The level of antioxidant enzymes (catalase and superoxidedismutase), non-enzyme components (ascorbic acid level and melanodialdehyde) and ascorbic acid were estimated. The structural changes were observed by using histological techniques. Results showed significant improvement in superoxidedismutase, catalase, total protein and ascorbic acid level with decreased melanodialdehyde level. The treatment with such herbal extracts containing creams could be utilized for the protection of photo induced intrinsic oxidative stress as well as structural alterations in skin.

**Key words:** Enzymes, photo protective, *C. asiatica*, oxidative stress, antioxidants

### INTRODUCTION

Ultraviolet irradiation from the sun causes deleterious effects on human skin, like sunburn, immune suppression, cancer and premature aging (Photoaging) (Cooper *et al.*, 1992). Sunburn and immune suppression occur accurately in response to excessive exposure to sun, whereas skin cancer and photoaging result from accumulated damage caused by repeated sun exposure. Skin cancer is the most prevalent form of cancer in humans, typically occurs in photoaged skin (Weinstock, 1994) Kaminer, 1995) and characterized by wrinkles, laxity, uneven pigmentation, brown spots and leathery appearance (Gilchrest and Yarr, 1992). Photoaging is induced by prolonged exposure of all portions of the solar spectrum, including UV-A and UV-B and infrared region (Kligman and Crosby, 1992; (Kligman and Zhenge, 1994), which generates free radical species i.e., considered as reactive oxygen. Reactive oxygen is considered to play an important role in cutaneous pathology. Enzymic and nonenzymic antioxidant substances can prevent oxidative damage. Grossly photo damaged skin appears wrinkled and atrophic, with mottled pigmentation. Histologic and ultra structural studies have shown that alterations in photo-aged skin are most found in dermal connective tissue (Smith, 1962).

Although clinical evidences for photo damage can remain inapparent for many years, ultraviolet radiation induced changes in superoxidedismutases, catalase, melanodialdehyde, ascorbic acid and total protein level in skin were observed in several models. Microscopically, as the skin ages normally, the dermis becomes hypocellular, the vasculature remains intact and collagen forms a stable with increased cross-linked matrix. By contrast, the epidermis of photoaged skin becomes acantholic (thickened) and

the vessels tortures. Antioxidants protect the human body against damage by Reactive Oxygen Species (ROS). Antioxidants could be very specific for inhibition of ROS formation, while others bind with and inactivate them (Harmani and Parihar, 1998).

The herbs as biological additives in form of extracts are utilizing since long period of time in the cosmetic formulation (Mazzio and Soliman, 2004; Ashawat *et al.*, 2005) and also scientific evidences proven that many plant extracts showed their photo protective activity (Katiyar, 2000, Katiyar and Elmet, 2001; Ashawat *et al.*, 2006a, b). The present investigation was undertaken to evaluate the effect of prepared cream formula containing different proportion of extracts i.e., *C. asiatica*, *E. officinale*, *P. granatum*, *A. catechu*, *C. tora*, *C. longa*, *C. Zeylanicum*, *G. glabra*, *P. corlifolia* and fresh gel of *A. vera* for protection of premature skin aging induced by ultraviolet radiations in rat model.

## MATERIALS AND METHODS

### Chemicals

The chemicals i.e., dichromate acetic acid, ethylenediaminetetraacetic acid (EDTA), sodiumcyanide, nitroblue tetrazolium, riboflavin, thiobarbituric acid, di-nitrophenylhydrazine, 2-4 di-nitrophenylhydrazine, thiourea, bovine serum albumin, folins ciocalteus (AR grades) were purchased from, Fluka and Merck India Ltd.

### Formulation Studied

An optimized herbal aqueous base cream was prepared accordingly to method (Ashawat *et al.*, 2006a). The optimized formula consisting of natural base like sesame oil 2%, almond oil 3%, honey 2%, jajoba oil, tea tree oil 0.5% each with blend of herbal extracts; *C. asiatica* 0.64 %, *G. glabra* 0.64%, *P. granatum* 0.17%, *A. catechu* 0.5%, *C. zeylanicum* 0.35%, *P. corlifolia* 0.64%, *C. tora* 0.64%, *C. longa* 0.17% and fresh *A. vera* gel 0.65%.

### Animal Housing

Albino rats (Wistar strain) were used for the present study (body weight 175 to 200 g). The animals were kept in well-ventilated area of the period of experiment till thirty days. The animals were housed in polypropylene cages at controlled temperature ( $25\pm 2^\circ\text{C}$ ), relative humidity ( $60\pm 5\%$ ) and light. Rats were fed with standard laboratory diet and drinking water was given through drinking bottles through out the experiment. Care was taken to avoid coprophagy (by using metabolic cages). The animals were maintained as per CPCSEA (Committee for the Purpose of Control and Supervision of Experiments on Animals) regulations and the experiment was cleared by IAEC (Institutional Animal Ethics Committee).

### Animal Grouping

To evaluate the protective effects of the herbal cream on the oxidative stress markers, the three groups of six animals each were prepared i.e., E1, E2 and E3. The study pattern was designed according to following manner.

E1: Control group (With out the UV and formulation treatment, on same diet and environment).

E2: UV treated group

E3: Formulation treated

### Methods of Biological Estimation

#### UV Treatment to Animals

In present study two broad ultraviolet range lamps (200-400 nm) were used to induce photo stress on the skin area of rats. The intensity of light (irradiance) was regularly checked before each test, by using a suitable broadband solarimeter (UV meter). The intensity of exposed radiation was

calibrated by using solarimeter. The irradiance of  $3.6 \pm 0.4 \text{ mW cm}^{-2}$  was exposed to achieve the  $5 \text{ J cm}^{-2}$  intensity of exposed light radiation. Irradiance of source was determined by using the Surya mapi (SPW.QA CEL India). The doses of  $2.5 \text{ mg cm}^{-2}$  cream formulations were applied to E3 group animals before irradiation to UV light.

The time of light exposure is calculated in the following way accordingly to OECD Test Guidelines:

$$T\{\text{Min}\} = \frac{\text{Irradiation Dose (J cm}^{-2}\text{)} \times 1000}{\text{Irradiance (mW cm}^{-2}\text{)} \times 60}$$

#### **Tissue Preparation for Biochemical and Histological Studies**

After thirty days study, rats were sacrificed by decapitation and their skins were surgically dissected out under aseptic conditions. The excess fascia and blood clots from the skin were removed by washing with chilled physiological saline buffer (pH 7.2).

Skin tissues were weighed and minced on glass plate over ice bags to make colloid and then allowed to homogenate. The homogenate were centrifuged at 5000 rpm for 10 min and supernatant fractions were collected and stored in deepfreeze for study of different biochemical parameters.

For histological studies, skin tissues were fixed in freshly prepared 10% chilled neutral formalin for 12 h at  $4^\circ\text{C}$ . After fixation, skin tissue was rinsed in distilled water for several times and dehydrated in graded alcohol series, cleared in zylene and embedded in paraffin wax to make tissue blocks. All the tissue blocks were labeled accordingly to groups. The  $8 \mu\text{m}$  thick series sections were prepared by using rotary microtome. Sections were stained with hematoxylin and eosin stains for demonstration of ultra structural epidermal and dermal changes (Meenakshi *et al.*, 2005).

UV protecting effects of cream formulation was studied by estimation of biochemical parameters i.e., Catalase (Sinha, 1972), Superoxidedismutase (SOD) (Winterbourn *et al.*, 1975), Malondialdehyde (MDA) (Buege and Aust, 1978), Ascorbic acid (Natelson, 1971) and Total Protein (Adeghate, 1999) in each set of experiment.

#### **Statistical Analysis**

The statistical analysis was carried out by using SPSS soft ware (version 14.0) and results were expressed as mean $\pm$ SEM. The significance of difference between mean values for the various treatments was tested using the unpaired student t-test  $p < 0.05$  was considered as statistically significant (Mahajan, 1989).

### **RESULTS AND DISCUSSION**

The antioxidant enzymes, such as SOD, catalase and glutathione peroxidase constitute a mutually supportive team of defense against Reactive Oxygen Species (ROS). The high reactivity of ROS can trigger a host of disorders in biological systems. Endogenous antioxidant enzymes are responsible for preventing or neutralizing the free radical induced damages of tissues.

In the present investigation the elevated level of end products of lipid peroxidation in skin of rats treated with UV radiations were observed. The increase in MDA level in skin tissues suggests enhanced lipid peroxidation leading to tissue damage and failure of antioxidant defense mechanisms to prevent formation of excessive free radicals (Table 1). Pretreatment with cream ( $2 \text{ mg cm}^{-2}$  day topically) significantly reversed these changes. Veerendra *et al.* (2002) showed a significant decrease the levels of malondialdehyde (MDA) after the treatment of *C. asiatica* aqueous extracts. Hence it is possible that extracts exert their effects due to the antioxidant activity.

Table 1: Effect of CAA4 on Malondialdehyde (MDA) ascorbic acid and total protein in UV treated rats

Groups	Treatment	Dose	Malondialdehyde (MDA) nmoles/mL±SEM	Ascorbic acid mg/100 mL±SEM	Total Protein (TP) (µg mL±SEM)
I	Control	Vehicle	1.016±0.89	3.430±0.256	559.17±18.97
II	UV Treated	3.6 mW cm <sup>-2</sup>	1.683±0.090 <sup>+</sup>	2.383±0.154 <sup>++</sup>	491.67±9.50 <sup>++</sup>
III	UV Treated plus CAA4	3.6 mW cm <sup>-2</sup> Plus 2.5 mg cm <sup>-2</sup>	1.058±0.088 <sup>*</sup>	3.258±0.218 <sup>**</sup>	548.33±13.25 <sup>**</sup>

All values are represented as Mean±SEM (n = 6), p-value: +<0.001; ++<0.01 When compared with control untreated animals, \*<0.001; \*\*<0.01 When compared with UV treated group

Table 2: Effect of CAA4 on Catalase (CAT) and superoxidizedismutase (SOD) in UV treated rats

Groups	Treatment	Dose	Catalase (µ moles of H <sub>2</sub> O <sub>2</sub> utilized/min./mg of protein±SEM)	Superoxidizedismutase (SOD) (Percentage inhibition of NBT reduction±SEM)
I	Control	Vehicle	41.96±3.14	56.33±4.18
II	UV Treated	3.6 mW cm <sup>-2</sup>	22.16±3.22 <sup>++</sup>	38.33±4.20 <sup>+++</sup>
III	UV Treated plus CAA4	3.6 mW cm <sup>-2</sup> Plus 2.5 mg cm <sup>-2</sup>	34.54±3.55 <sup>***</sup>	50.50±3.03 <sup>***</sup>

All values are represented as Mean±SEM (n = 6), p-value: ++<0.01; +++<0.05 When compared with control untreated animals, \*\*\*<0.05 when compared with UV treated group

Present study also showed that the catalase level was significantly ( $p < 0.01$ ) decreased in UV induced oxidative stress, but the level of catalase was significantly increased ( $p < 0.05$ ) after the treatment with cream as compared to E2 group rat model (Table 2).

The level of superoxidizedismutase (SOD) was significantly low in UV induced oxidative stress rats when compared to control untreated animals. The level of SOD in E3 group was found to be significantly high as compared to E2 group (Table 1).

The reduction in total protein level appears to correlate with the reduction in collagen matrix or degeneration of tissues bundles. Total protein level was found significantly reduced ( $p < 0.01$ ) as compared to control group as shown in Table 1, irradiation of UV radiations noticeably inhibited total protein level. It has been reported that UVB irradiation showed an inhibitory effect of UV on decreased amino acid uptake (Hiroto and Shinji, 2003).

The enzyme catalase, is also responsible to catalyze the reduction of H<sub>2</sub>O<sub>2</sub> to H<sub>2</sub>O and O<sub>2</sub> (Cotgreave *et al.*, 1988). In oxidative stress the level of catalase are reduced. Oxidative stress is an outcome of imbalance between ROS production and antioxidant defenses, which in turn, evokes a series of events to regulating the cellular functions (Bandopadhyay and Banerjee, 1999). The Gr-E2 showed the declined levels of catalase as compared to Gr-E1, while found significantly ( $p < 0.01$ ) increased level of catalase were observed in gr-E3. The level of Ascorbic acid (Vitamin-C) was significantly ( $p < 0.01$ ) reduced after the UV exposure when compared with control untreated animals. While the level of ascorbic acid were found significantly high in group Gr-E3, therefore it was clearly indicated that the extracts present in cream scavenges the free radicals by showing the increase of ascorbic acid level as compared to UV induced oxidative stress in rats (Table 2).

The histological changes were observed after the ultra structural studies. From the histological studies it was noted that the features of UV irradiated skin (Gr E2) were similar to that of a chronic allergy contact dermatitis, showed moderate to severe spongiosis (Hirose *et al.*, 2006).

It was evidenced from the literature that some cases with vesiculation and a superficial perivascular lymphohistocytic infiltrate with exocytosis. Ultra structural changes in collagen fibers bear a remarkable similarity to those seen in photodamaged skin. The collagen was damaged to an extent (Fig. 1) are shown in UV exposed group samples.

The elastosis was observed severe, but was not only confined to the upper dermis, as it is with the UVB, but more dense were found deeply in to the dermis, which are the sign of UVA. The cellular structure of Gr-E2 (Fig.1) showed that the thickness of epidermis, this might be due to the eruption of photo allergic dermatitis and hyperkeratosis and photoaging of the follicular mouths (Jones and

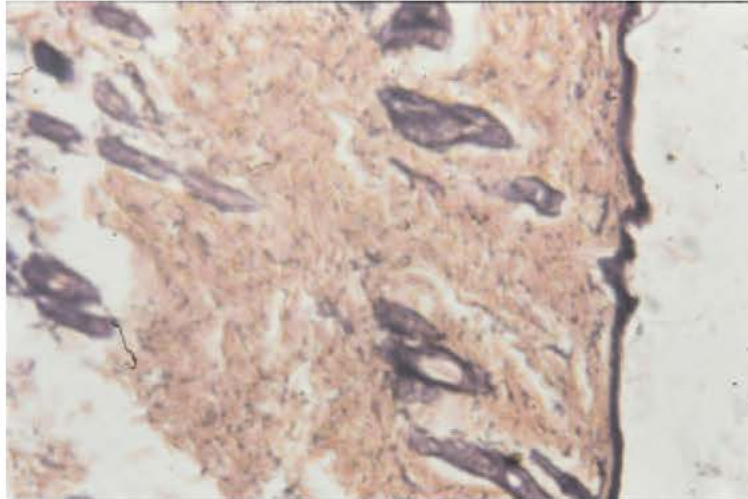


Fig. 1: Microphotograph of rat skin after UV exposure

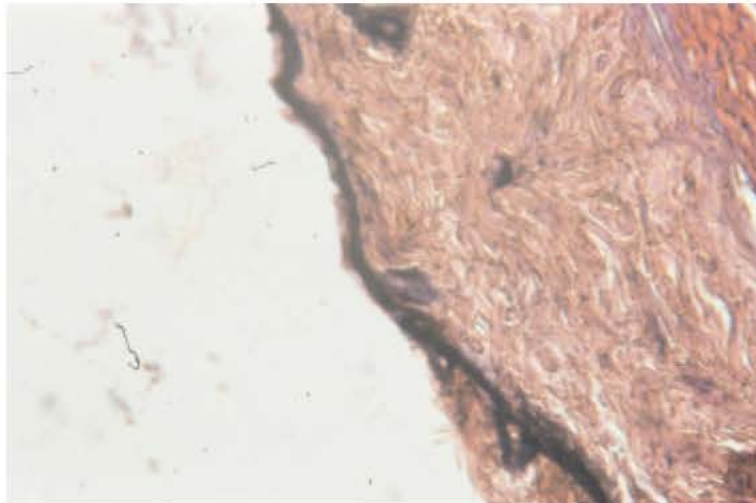


Fig. 2: Microphotograph of rat skin after formulation treatment

Veale, 2004). The thinning of dermis area was occur in the Fig. Gr-E2 might be due to plunging of the follicular mouths. Such conditions also occurred due to topical application of allergens and chronic exposure to UV radiations (Lisa *et al.*, 1997). The Gr-E2 photograph showed the papillary dermis, there was an increased number of fibroblasts and vertically oriented collagen bundles. This discontinuous and fibroblastic collagen bundle structure might be due to UV intensity and chronicity of UV dose. The changes in epidermal region were found in-group Gr-E2 as compared to group E1 due to the UV irradiation. The cellular structure of UV exposed area showed liquefaction degeneration of basal cell layer of the epidermis region (Fig. 1). The normal skin showed normal arrangement of connective tissues, while the UV exposed and Gr-E3 treated animal skin showed regenerative changes in the connective tissues, oedema and fibrinoid changes were marked immediately below the epidermis. Figure 1 of Gr-E2 showed drastic changes in the collagen degeneration as compared to Gr-E1 and Gr-E3, this might be due to prevention of premature elastotic degeneration of collagen, which clearly indicated the chronic UV exposure symptoms (Lewis *et al.*, 2004). The Fig. 2 of Gr-E3 histological

evidences showed remarkable protection level of collagen bundles and elastic fibers. Many polyphenolic components like epigallocatechin, stilbenes, coumarins, cinnamic acids, coca, tea etc. were tested for the prevention of melanoma skin cancer (Linden *et al.*, 2003; Kim *et al.*, 2001; Krutmann, 2001).

Heinrich *et al.* (2006) shows the photoprotective efficiency of flavanols and found that high flavanols groups showed the significant decrease in minimal erythema dose (Campos *et al.*, 2006). Bioflavonoids are helpful to maintain the skin biological activity in terms of photoprotection, because the association of bioflavonoids acted by different mechanism such as antioxidant and absorbs ultraviolet rays, which suggest photoprotective effects of botanical extracts.

It is evident from the results of the present investigation that the herbal extracts in cream formulation possess photo protective and anti aging properties.

## CONCLUSION

Study suggests that extracts containing cream formulation may also have a role in preventing the aspect of photo aging attributable to enzymic and nonenzymic mediated dermal damages. Such formulations should also address the merits of cosmetic in relation to sun protecting formulation.

## ACKNOWLEDGMENTS

The authors wish to thank AICTE(RPS) and UGC (major research project) for providing instrumental facility. The authors are also thankful to Director, Head Cosmetics Laboratory, Institute of Pharmacy, Pt. Ravishankar Shukla University, Raipur (CG) for providing experimental facilities.

## REFERENCES

- Adeghate, E. and J. Singh, 1999. An on-line method for the measurement of total protein output in biological fluids and secretory tissues after stimulation of intrinsic nerves and identification of neurotransmitters using immunohistochemical techniques. *Brain Res. Brain Res. Protoc.*, 3: 270-277.
- Ashawat, M.S., S. Saraf and S. Saraf, 2005. Antisoalar activity of *R. damnesia* and *T. erecta*, *Planta Indica.*, 2: 26-28.
- Ashawat, M.S., S. Saraf and S. Saraf, 2006a. Cosmetic potentiality of Plant extracts and natural oils. *Bioscie. Biotechnol. Res. Asia*, 3: 181-188.
- Ashawat, M.S., S. Saraf and S. Saraf, 2006b. Sunscreen properties of natural skin care lotion. *Plant Arch.*, 6: 253-256.
- Bandopadhyay, V., D. Das and R.K. Banerjee, 1999. Reactive oxygen species oxidative damage and pathogenesis. *Curr. Sci.*, 77: 658-655.
- Buege, J.A. and S.D. Aust, 1978. The thiobarbituric acid assay methods. *Enzymology*, 52: 306.
- Campos, P.M., M.D. Maria, A.K. Gianeti, M.L. Yara and R.G. Lorena, 2006. *In vitro* antioxidant and *in vivo* photoprotective effects of an association of bioflavonoids with liposoluble vitamins. *Photochem. Photobiol.*, 82: 683-688.
- Cooper, K.D., L. Oberhelman and T.A. Hamilton, 1992. UV exposure reduces immunization rates and promotes tolerance to epicutaneous antigens in human. *Proc. Natl. Acad. Sci.*, 89: 8497-8499.
- Cotgreave, I.A., P. Moldeus and S. Orrenius, 1988. Host biochemical defense mechanism against pro-oxidants. *Ann. Rev. Pharmacol. Toxicol.*, 28: 189-212.
- Gilchrest, B.A. and M. Yaar, 1992. Aging and Photoaging of the skin: Observations at the cellular and molecular level. *Br. J. Dermatol.*, 127: 41, 25-30.

- Harmani, T. and M.S. Parihar, 1998. Reactive oxygen species and oxidative DNA damage. Indian J. Physiol. Pharmacol., 42: 442-449.
- Heinrich, U., N. Karin, T. Hagen, S. Helmut and S. Wilhelm, 2006. Long term ingestion of high flavanol cocoa provides photoprotection against UV induced erythema and improves skin condition in women. J. Nutr., 136: 1565-1569.
- Hirose, E., S. Hirabavanshi, K. Hori, F. Kasai and M.M. Watanabe, 2006. UV protection in the phytosymbiotic ascidian *Didemnum molle* inhabiting different depths. Zool. Sci., 23: 57-63.
- Hiroto, Y. and K. Shinji, 2003. Effects of ultraviolet irradiation on the protein synthesis of human skin cell. A study with a monochromatic ultraviolet irradiation apparatus. Ind. Health, 41: 88-93.
- Jones, S.K. and D.J. Veale, 2004. The Connective Tissues Disease. In: Text book of Dermatology. 3rd Vol., Burns, T. (Ed.), Black Well Publisher, Christopher Griffinths, UK., pp: 212-214.
- Kaminer, M.S., 1995. Photodamages: Magnitude of problems. In: Photodamage. Gilcrest, B.A. (Ed.), Cambridge Mass, Blackwell Publishing Ltd. UK., pp: 1-10.
- Katiyar, S.K., 2000. Green tea and Skin. Arch Dermatol., 136: 989-994.
- Katiyar, S.K. and C.A. Elmet, 2001. Green tea polyphenolic antioxidants and skin photoprotection. Int. J. Oncol., 18: 1307-1313.
- Kim, J., J.S. Hawang, Y.K. Cho, Y. Han, Y.J. Jeon and K.H. Yang, 2001. Protective effects of epigallocatechin-3-gallate on UVA and UVB induced skin damage. Skin Pharmacol. Applied Skin Physiol., 14: 11-19.
- Kligman, L.H. and M.J. Crosby, 1992. The synergistic effects of UVA and UVB in tumorigenesis. Photobiochem. Photobiol., 55: 108-109.
- Kligman, L.H. and P. Zheng, 1994. The protective effects of a broad spectrum sunscreen against chronic UVA radiation in mice. A histological and ultrastructure assessment. J. Soc. Cosmet. Chem., 45: 21-23.
- Krutmann, J., 2001. New development in photoprotection of human skin. Skin Pharmacol. Applied Skin Physiol., 14: 401-407.
- Lewis, K.G., L. Bercovitch, S.W. Dill and B.L. Robinson, 2004. Acquired disorders of elastic tissue: Increased elastic tissue and solar elastotic syndromes. J. Am. Acad. Dermatol., 51: 1-21.
- Linden, K.G., P.M. Carpenter, C.E. Mc Laren, R.J. Barr and P. Hite, 2003. Chemoprevention of non melanoma skin cancer: Experience with polyphenol from green tea. Recent Results Cancer Res., 163: 165-671.
- Lisa, M., D.K. Cochen, T. Skopicki, H.C. Wallace and Jr. Levers, 1997. Histopathology of the skin. Lippincott, Raven Publisher, Philadelphia.
- Mahajan, B.K., 1989. Methods in Biostatistics. 5th Edn., Medical Publishers (P) Ltd., New Delhi.
- Mazzio, E. and A. Soliman, 2004. Tropical treatment for dyshidrosis (pompholyx) and dry skin disorders. US Patent No. 801520.
- Meenakshi, J., V. Jayaraman, K.M. Ramakrishnan and M. Babu, 2005. Ultrastructural differentiation of Abnormal Scars. Ann Burn Fire Disast., 1: 2-11.
- Natelson, S., 1971. Techniques of Clinical Chemistry, Charles Thomas, US., pp: 286.
- Sinha, A.K., 1972. Colorimetric assay of catalase. Anal. Biochem., 47: 389.
- Smith, J.G., E.A. Davidson, W.M. Sames and R.D. Clark, 1962. Alterations in human dermal connective tissue with age and chronic sun damage. J. Invest. Dermatol., 39: 47-50.
- Veerendra, K.M.H. and Y.K. Gupta, 2002. Effect of different extracts of *Centella asiatica* on cognition and markers of oxidative stress in rats. J. Ethnopharmacol., 79: 253-60.
- Weinstock, M.A., 1994. Epidemiology of non-melanoma skin cancer: Clinical issues, definitions and classification. J. Invest. Dermatol., 102: 4S-5S.
- Winterbourn, C.C., R.E. Hawkins, M. Brian and R.W. Carrell, 1975. The estimation of red cell superoxide dismutase activity. J. Lab. Clin. Med., 85: 337-341.