



Trends in
Medical Research

ISSN 1819-3587



Academic
Journals Inc.

www.academicjournals.com

Oral Health and Evaluation of Skeletal Development in Children with Renal Disease

¹Sadullah Kaya, ²Nihal Hamamci, ³Izzet Yavuz, ¹Özkan Adigüzel and ³Emin Caner Tümen

¹Department of Operative Dentistry,

²Department of Orthodontics,

³Department of Paediatrics, Faculty of Dentistry, Dicle University, Diyarbakir, Turkey

Abstract: The aim of this study was to monitor the oral health of children with chronic renal disease and skeletal development in children with renal disease. Thirty-six children (aged 3-13 years) were given a full clinical and radiological dental examination to evaluate skeletal development and tooth changes. After the first diagnosis and careful examination, enamel defects were clinically detected in a total of 11 children (30.5%). Of these, eight children clinically affected (22.2% of all those examined) exhibited localized hypoplasia of the primary canines, which was determined in only 3% of healthy control children. This increased prevalence is probably due to disordered calcium and phosphate metabolism. Chronological ages were recorded and hand-wrist radiographs were taken in our clinic. According to our results, skeletal development is slower than chronological development and this is statistically significant. Dental and medical care should be closely integrated for children with renal disease in order to avoid undesirable dental sequelae.

Key words: Chronic renal failure, skeletal age, enamel hypoplasia, dental health

INTRODUCTION

Chronic Renal Failure (CRF) may be defined as a loss of nephron functions, renal functions and excretory waste collection. A loss of regulatory and excretory functions in the kidneys may lead to various complications and oral symptoms needing to be borne in mind in dental treatments (Greenberg and Glick, 2003).

The oral symptoms occurring in patients exhibiting CRF are seen after systemic symptoms and are not specific in the diagnosis of kidney deficiency disease. Dentists should determine dental indications in the awareness that this disease may affect other systems (Ferguson and Whyman, 1998).

Earlier studies have demonstrated enamel changes of permanent teeth in pediatric patients with nephrotic syndrome, CRF. In a previous study of permanent teeth of 49 children in different stages of CRF, enamel hypoplasia was observed in 12% and discoloration or opacities in 39%. The preferred localization of these lesions on permanent incisors in congenital nephropathies indicates an early insult to enamel formation of the secondary dentition at the time when kidney disease becomes manifest (Martin *et al.*, 1999).

The oral manifestations of CRF include an ammonia-like smell, dysgeusia, stomatitis, gingivitis, decreased salivary flow, xerostomia and parotitis (Al-Nowaiser *et al.*, 2003).

The prevalence of dental caries in patients with CRF is low. It has been reported that plaque pH is directly correlated with the salivary urea nitrogen concentration. The pH was significantly more alkaline in children with renal failure compared with a group of renal transplant children and a group

Corresponding Author: Dr. Izzet Yavuz, Department of Pediatrics Dentistry, Faculty of Dentistry,
University of Dicle 21280, Diyarbakir, Turkey
Tel: +90-412-2488101-3426 Fax: +90-412 2294299

of healthy controls. The pH and buffer capacity of whole unstimulated saliva in a group of adults with end-stage renal failure undergoing haemodialysis was also greater compared with those of controls. Enamel hypoplasia is frequently seen in patients with renal disease, particularly CRF. The location of hypoplastic enamel in the permanent dentition corresponds with age at the onset of CRF (Al-Nowaiser *et al.*, 2003; Rojas *et al.*, 1991).

Children with Chronic Kidney Disease (CKD) exhibit extrarenal systemic manifestations of the disease, similar to those seen in adults. Unique to paediatric patients, however, are the effects of CKD on growing bone. Skeletal deformity is commonly seen in children with renal obstructive disorder related to CKD and is most apparent in the bones that are growing most rapidly at a given age (Craig, 2005).

Researchers have reported that a number of problems may appear in oral tissue and skeletal systems in addition to the many systemic complications in patients with CRF (Akoğlu, 1970; Tuğsel and Akkemik, 1996; Yalçın, 1998).

Dialysis and renal transplantation are important procedures in the management of patients with End-Stage Renal Disease (ESRD). Dental care for patients with ESRD undergoing haemodialysis, who are usually candidates for kidney transplantation, includes the management not only of existing oral problems but also of potential infections in the oral and maxillofacial regions (Hong *et al.*, 1999).

The objectives were to monitor the oral health of children with chronic renal disease and skeletal development in children with renal disease of oral hygiene compared with the general medical care needed by these children, who would benefit from the incorporation of a dental service into the general medical program.

Children with renal disease need to be monitored closely by their general dental practitioner in close collaboration with the paediatric nephrologist.

Further studies should focus on the influence of skeletal alterations adjacent to areas of enamel formation.

MATERIALS AND METHODS

This prospective study involved an oral examination of 36 children aged between 3 and 13 years (20 male, 16 female), examined whilst seated in a dental chair, with the aid of an operatory light. Present study was conducted between 2005-2006 years. Hand-wrist radiographs, bitewing radiographs and orthopantomograms were taken and copies were forwarded to the primary care dentist if the child had one (Numm *et al.*, 2000).

RESULTS

All images were examined and hand-wrist radiographs were evaluated in terms of bone development according to the Greulich-Pyle atlas.

The hand-wrist radiograph of a nine-year-old male patient with CRF is shown in Fig. 1, that of a normal nine-year-old male according to the Greulich-Pyle atlas in Fig. 2, that of a nine-year-old female patient in Fig. 3 and that of a normal nine-year-old female according to the Greulich-Pyle atlas in Fig. 4.

The hand-wrist radiography data obtained were statistically analysed in the Biostatistics Department using Student's t-test for two independent means.

All teeth were examined using the WHO criteria and the indices recorded as the dmfs/dmft index (decayed, missing and filled surfaces/teeth in the primary dentition) and the DMFS/DMFT index (decayed missing and filled surfaces/teeth in the permanent dentition) (Numm *et al.*, 2000).

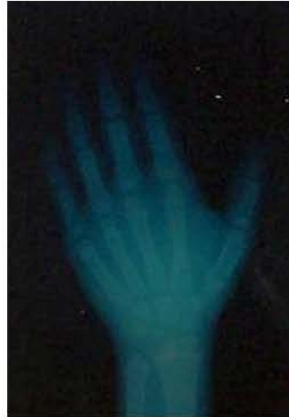

Fig. 1: Hand-wrist radiography of a nine-year-old male patient with chronic renal failure

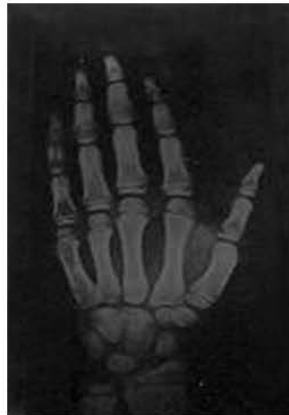

Fig. 2: Image of a normal nine-year-old male according to the Greulich-Pyle atlas

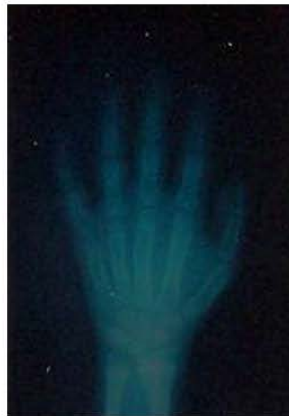

Fig. 3: Hand-wrist radiography of a nine-year-old female patient




Fig. 4: Image of a normal nine-year-old female according to the Greulich-Pyle atlas

Table 1: Statistically significant correlation between chronological and skeletal age ($p < 0.01$)

No. of patients	Chronologic age mean	Std. deviation	Skeletal age mean	Std. deviation	Sig. p
36	7.81	3.41	5.74	2.88	$p < 0.01$

Table 2: Prevalence of dental caries in 36 paediatric renal patients, expressed as the sum of decayed, missing or filled teeth and diagnosed using combined clinical and radiographic indices

Teeth and surfaces	Primary dentition		Permanent dentition	
	Teeth (dmft)	Surfaces (dmfs)	Teeth (DMFT)	Surfaces (DMFS)
Dental caries experience	0.2-1.0	0.4-2.6	0.2-1.1	0.4-1.6
95% confidence intervals				
Median	0.0	1.0	0.0	1.0

d = Decayed, m = Missing, f = Filled, Primary teeth; D = Decayed, M = Filled, F = Filled, Permanent teeth. t/T = No. of teeth affected; s/S = No. of surfaces of teeth affected

Enamel opacities were assessed in the permanent dentition using the Developmental Defects of Enamel index i.e., into demarcated opacities (a defect involving the translucency of the enamel but which can be white, yellow or brown in colour with a clear boundary), diffuse opacities (also involving an alteration in enamel translucency, although the defect can appear as lines or patchy or irregular cloudy areas, which appear confluent with the adjacent normal enamel) and hypoplasia (a defect associated with a reduced local thickness of the surface enamel presenting as pits or grooves or larger sheets of missing enamel) (Numm *et al.*, 2000).

According to the data obtained from CRF patients, a statistically significant correlation at the $p < 0.01$ level was determined between chronological and skeletal age and these values are shown in Table 1.

Using our diagnostic criteria, the proportion of our patients with CRF with enamel hypoplasia was lower than that reported in other research. An increased plaque score was observed in both the primary dentition and permanent dentition.

Prevalence of dental caries in 36 paediatric renal patients, expressed as the sum of decayed, missing or filled teeth and diagnosed using combined clinical and radiographic indices, is shown in Table 2.

DISCUSSION

The dental disease indices for a group of 36 young children with congenital nephropathies in renal function were similar to those recorded by earl (Numm *et al.*, 2000; Al-Nowaiser *et al.*, 2003). The

main difference of our study is focused with particular attention to influence of factors on oral and dental health and skeletal development. There is a need for careful and modified treatment planning in dental practices in terms of diseases in the medically high risk group such as kidney deficiency (Esser, 1992).

A loss of cortical bone in the mandibular angulus has been reported from radiographies taken from patients with CRF. In biopsies taken from non-decalcified iliac crests, a close correlation has been determined between cortical bone loss in the angulus and the degree of renal osteodystrophy and it has been claimed that the degree of cortical thickness loss in the mandibular angulus can be indicated as a parameter in the diagnosis of metabolic bone loss (Scutellari *et al.*, 1996).

Scutellari *et al.* (1996) determined radiological anomalies in 57.7% of patients entering haemodialysis and mandibular bone lesions in 15.5%.

Scheutzel and Ritter (1989) determined radiographic changes in the jaw bones of children with CRF.

Clark and Wysocki (1988) suggested the cause of the radiological and dental differences seen in CRF patients as changes in phosphorus and calcium metabolism.

Yalçın (1998) analysed patients' jaw radiographs and determined a statistically significant correlation between reduction in the trabecular structure and duration of dialysis and parathormone and ALP values. He also emphasised that there was a significant correlation between loss of lamina dura and duration of dialysis and PTH and serum values. The study also determined that no statistically significant alterations occurred between dialysis duration and pathological changes and that the existing changes appeared prior to dialysis.

Scutellari *et al.* (1996) took panoramic and skeletal radiographs from 45 CRF patients with an average age of 47.8 years and examined the spinal, pelvic, clavicular, shoulder, hand and skull bones. They evaluated the panoramic radiographs alone of the control group consisting of 45 individuals without kidney disease. They determined radiographic abnormalities in the hand, shoulder and pelvic bones of 51.1% of dialysis patients and stated that these were seen together with maxillary lesions in 86.9%.

In the control group, making use of the mandibular reference point, they identified a 15.5% level of mandibular crest resorption (osteoporosis).

Jaffe *et al.* (1990) stated that the peak point in bone age development was reached later in children with CRF.

Wolff *et al.* (1985) reported a delay in tooth age and bone age in patients observed to have CRF and maintained that delays in bone maturation were more frequently observed.

In our study, too, bone development followed a slower course compared to chronological age development in patients with CRF.

In our study, only 30.5% of the 36 patients presented with enamel hypoplasia of primary teeth at clinical examination. Using our diagnostic criteria, the proportion of our patients with CRF with enamel hypoplasia was lower than that reported by Wolff *et al.* (1985).

In the present study, patients with CRF undergoing haemodialysis displayed oral and salivary changes. Further research into oral and salivary changes in these patients after kidney transplantation may provide additional information on the relationships between the oral cavity and saliva and renal insufficiency (Hong *et al.*, 1999).

A significantly greater proportion of children with CRF was caries-free compared with the control children. Both the mean dmft and DMFT were significantly lower in the CRF children, which is in agreement with earlier research (Al-Nowaiser *et al.*, 2003).

The low caries prevalence can in part be attributed to the significantly greater mean salivary urea concentration and buffering capacity compared with the controls. In addition, the total count of

Streptococcus mutans was significantly lower in the CFR children and it is well established that *S. mutans* plays an important role in the initiation and progression of dental caries (Loesche, 1986; Hanada, 2000).

Earlier studies in children with CRF demonstrated developmental defects of enamel in permanent teeth, mainly in the presence of congenital nephropathies manifesting themselves in the first years of life (3-5). In general, primary teeth are less susceptible to developmental defects than permanent teeth (Martin *et al.*, 1999).

The prevalence of enamel defects was significantly greater in the permanent teeth of the CRF children, which is in agreement with the work of earlier researchers who reported that these defects coincide with onset and severity of CRF. Other researchers have also determined an increased prevalence, which may reflect the early onset of the disease and is probably due to disordered calcium and phosphate metabolism (Numm *et al.*, 2000; Jaffe *et al.*, 1986; Warady *et al.*, 1989).

A patient with CRF who is undergoing dialysis or renal transplantation is susceptible to a number of infections. Transient, usually asymptomatic bacteraemias occur in a wide variety of dental manipulations, particularly those involving the mucous membranes. Certain bacteraemias may cause serious complications in these already compromised patients. Therefore, antimicrobial prophylaxis is essential when these patients undergo bacteraemia-causing dental procedures (Michael, 1979).

In conclusion, CRF has been observed to have a negative impact on skeletal age development and the skeletal age of such patients lags behind chronological age.

The proportion of CRF children with dental caries was significantly lower than in the matched controls. This is most likely due to the effect of a greater salivary urea concentration and buffering capacity, which may inhibit the growth of *S. mutans*.

Enamel defects were detected in almost one-third of these patients, either by clinical or histopathological examination, mainly in patients with an early decline of renal function in the first months of life.

The increased plaque score in both the primary dentition and permanent dentition may be a reflection of the perceived importance and on the influence of vitamin D in CRF.

REFERENCES

- Akoğlu, E., 1970. What is the Dialysis and Chronic Renal Failure. Türk Nefroloji Derneği, Haemodialysis Hand Book, pp: 13-20.
- Al-Nowaiser, A., G.J. Roberts and R.S. Trompeter *et al.*, 2003. Oral health in children with chronic renal failure. *Pediatr. Nephrol.*, 18: 39-45.
- Clark, D.B. and G.P. Wysocki, 1988. Dentin in chronic renal failure: An ultrastructural study. *J. Oral Pathol.*, 17: 60-69.
- Craig, B.L., 2005. Renal Osteodystrophy: A Pediatric Perspective. *Growth Hormone IGF Res.*, 15: 42-47.
- Esser, E., 1992. Medical high-risk patient in the dental practice. *Dtsch Zahnärztl Z.*, 47: 11-17.
- Ferguson, C.A. and R.A. Whyman, 1998. Dental management of people with renal disease and renal transplants. *N. Z. Dent. J.*, 94: 125-130.
- Greenberg, M.S. and M. Glick, 2003. *Burket's Oral Medicine Diagnosis and Treatment*. 10th Edn. Philadelphia, pp: 417-419.
- Hanada, N., 2000. Current understanding of the cause of dental caries. *Jap. J. Infect. Dis.*, 53: 1-5.
- Hong, S.K., W.L. Sung, C.C. Sung and K.K. Young, 1999. Oral manifestations and salivary flow rate, pH and buffer capacity in patients with end-stage renal disease undergoing hemodialysis. *Oral Surg. Oral Med. Oral Pathol. Oral Radiol. Endodontol.*, 88: 316-319.

- Jaffe, E.C., G.J. Roberts and C. Chantler *et al.*, 1986. Dental findings in chronic renal failure. *Br. Dent. J.*, 160: 18-20.
- Jaffe, E.C., J. Roberts and C. Chantler *et al.*, 1990. Dental maturity in children with chronic renal failure assessed from dental panoramic tomographs. *J. Int. As Dent. Child*, 20: 54-58.
- Loesche, W.J., 1986. Role of streptococcus mutans in human dental decay. *Microbiol. Rev.*, 50: 353-380.
- Martin, J.K., B. Roger and P. Thomas, 1999. Enamel hypoplasia of primary teeth in chronic renal failure. *Pediatr. Nephrol.*, 13: 68-72.
- Michael, H., 1979. Chow and Devereaux S. Peterson. Dental management for children with chronic renal failure undergoing hemodialysis therapy. *Oral Surg. Oral Med. Oral Pathol.*, 48: 34-38.
- Numm, J.H., J. Sharp and H.J. Lampert *et al.*, 2000. Oral health in children with renal disease. *Pediatr. Nephrol.*, 14: 997-1001.
- Rojas, P.S., M.A. Mora and P.G. Gordillo *et al.*, 1991. DMF index in patients with end-stage kidney disease. *Pract. Odontol.*, 12: 9-11.
- Scheutzel, P. and W. Ritter, 1989. Alterations of teeth and jaws in children with chronic renal failure. *Dtsch. Zahnärztl. Z.*, 44: 115-118.
- Scutellari, P.N., C. Orzincolo and P.L. Bedani *et al.*, 1996. Radiographic manifestations in teeth and jaws in chronic kidney insufficiency. *Radiol. Med. Torino*, 92: 415-420.
- Tuğsel, Z. and Ö. Akkemik, 1996. Hemodiyaliz ile tedavi edilen kronik böbrek yetmezliği hastalarının dişhekimliği yönünden önemi. *İzmir Dişhekimleri Odası Dergisi*, 8: 8-10.
- Warady, B.A., M. Koch and D.W. O'Neal *et al.*, 1989. Plasma fluoride concentration in infants receiving long-term peritoneal dialysis. *J. Pediatr.*, 115: 436-439.
- Wolff, A., H. Stark and H. Sarnat *et al.*, 1985. The dental status of children with chronic renal failure. *Int. J. Pediatr. Neph.*, 6: 127-132.
- Yalçın, S., 1998. Kronik böbrek yetmezli hastaların çene kemiklerinde görülen değişikliklerin radyografik incelenmesi. *Dişhekimliği Dergisi*, 30: 232-237.