



Trends in
Medical Research

ISSN 1819-3587



Academic
Journals Inc.

www.academicjournals.com

Encopresis: From a Surgical View in Comparison to Psychiatric Management

¹G. El-Maadawy, ¹M. Balbola, ¹M. Shahin,
¹N. Salm, ²G. Khafagy, ³Us. Gheida and ⁴Sh. El-Maadawy

¹Department of Surgery, Faculty of Medicine,
Al-Azher University, New Damietta, Egypt

²Department of Pediatric, Kafer El-sheikh LRC, Egypt

³Department of Radiology, Faculty of Medicine, Tanta University, Egypt

⁴Department of Psychiatry, Ministry of Health Hospitals, Egypt

Abstract: It is an overview about encopresis, its definition, diagnosis and to focus on the role of surgery in its management. A prospective study designed to be held in multi centers in delta region of Egypt in the period from October 2002 to December 2008. Eighty five children diagnosed to be encopretic were the subject of this study. They underwent some surgical procedures and passed the integrated multi-therapeutic programs. Manometric, defecography, rectal ultrasound and recently MRI scan (in 17 child); were performed pre-operatively and during follow up period. Treatment considered effective when the child has been clean for 6 months at least. Twenty six children were primary non-retentive type (Group A: 30.6%) and fifty nine child were secondary retentive type (Group B: 69.4%); forty five child of them were due to organic causes (52.9%) needed surgical intervention. Hypotonic external sphincter was found in 7 Cases in group A (5.9%) and in 19 cases (22.4%) in group B; while thin internal sphincter was found in 5 cases in group A (8.2%) and in 11 cases in group B (12.9%). All children in group A and 24 children in group B (10 of them were underwent surgical procedures before) i.e., fifty child (58.8%); all were joined the integrative multi-therapeutic program with success rate 58% soiling free after 6 months and increased to (84%) after one year and no remission after about three years follow up; while in group B: 45 cases (52.9%) children of 59 patients underwent surgery with success rate (88.8%). Clinical and psychiatric examination in addition to anal manometry, defecography, rectal sonography and recently MRI are the main tools in diagnosis of encopresis. The integrative multi-therapeutic program is very effective (84%) with no remission in management of primary non-retentive encopretic children while surgery is the way to manage the secondary retentive encopretic children with (88.8%) success rate.

Key words: Encopresis, surgery, clinical, psychiatric examination, children

INTRODUCTION

Passage of normal stools in an abnormal place and at abnormal times after the age of four years without organic causes, is more likely to be related to a psychological disturbance, (Freeman, 1993; Behrman *et al.*, 2000). The term Encopresis is sometimes used in-correctly

Corresponding Author: G. El-Maadawy, Department of Surgery, Faculty of Medicine,
Al-Azher University, New Damietta, Egypt

to describe chronic idiopathic constipation with fecal soiling. Encopresis is, in fact, defined as passage of stool, often normal, in inappropriate places and at inappropriate times; (Freeman, 1989). Another definition made by Fennig and Fenning (1999) is the involuntary or intentional repeated passage of feces into inappropriate places (e.g., clothing or floor); Borowitz *et al.* (2008), also encopresis is known as overflow incontinence of feces due to unresolved constipation that can lead to fecal retention and impaction. Other criteria for diagnosis are a frequency of at least once a month for at least 3 months and patient age of 4 years or more (American Psychiatric Association, 1994, 2000; Rintala, 2002).

Encopresis affects 1-3% of the general pediatric population; by a child aged 4 years or older without a history of faecal retention. It is much more common in boys than in girls (male-to-female ratio 4:1) and appears to have a familial component (Hatch, 1988; Di-Lorenzo and Benninga, 2004).

Encopresis has been attributed to a range of factors, including faulty toilet training techniques, stress, trauma, disturbed parental-child relationships, sexual and physical child abuse, limited attention and concentration span, high level of motor activity, impaired rectal and sigmoid sensation and abnormal defecation dynamics (Loening-Baucke, 1984, 1990; Nolan and Oberklaid, 1993; Buttross, 1999; Joinson *et al.*, 2007). Psychosocial problems are far more common among children with encopresis than among normal children (VanDer Wal *et al.*, 2005; Bharucha *et al.*, 2006).

Functional encopresis may be associated with other neuro-developmental problems, including easy distractibility, short attention span coordination (Joinson *et al.*, 2007). Occasionally, the child has a special fear of using the toilet. Functional encopresis may also be precipitated by life events, such as a move to a new home (Kaplan and Sadock, 1984).

Pre-school children present with a history of constipation and with holding maneuvers. The school-age child may have constipation and fecal soiling for some times prior to detection. In some children encopresis is associated with enuresis and urinary tract infection (Behrman and Kliegman, 1998; Patel and Pratt, 1999).

Encopresis as a symptom can be viewed and understood from different aspects: physiologically, it represents faulty defecation dynamics, so that treatment is directed at clearing the bowel and correcting the dysfunctional mega colon (Loening-Baucke, 1990, 1996a); behaviorally, encopresis represents inappropriate behavior that warrants a change (Ayllon *et al.*, 1975); dynamically, it can be viewed as a reversion to an immature mode of behavior and an inappropriate way of expressing emotions which involves interlocking relationships with significant others (Bemporad *et al.*, 1971; Amsterdam, 1979). The principal differential diagnoses of encopresis, after Kuhn *et al.* (1999); were shown in Table 1.

As functional encopresis is fecal soiling past the time bowel control is physiologically possible and after toilet training should have been accomplished. The Diagnostic and Statistical Manual of Mental Disorders (American Psychiatric Association, 1987, 2000) revised criteria for functional encopresis, also specified a primary type and a secondary type of functional encopresis. Encopretic children are classified as primary type if the encopresis continues after both chronological and mental ages have reached at least 4 years and there has not been a prior period of fecal continence lasting at least one year, i.e., the child never had control over his defecation. Encopresis that develops any time after a year-long period of continence is termed secondary encopresis i.e., the child had control but reverted and lost it (Fennig and Fennig, 1999; Behrman *et al.*, 2000).

Lack of appropriate toilet training or inadequate training may delay the child's attainment of continence. There is also evidence that, some encopretic children suffer from lifelong

Table 1: The principal differential diagnoses of encopresis are listed in the following block after Kuhn *et al.* (1999)

Retentive encopresis
Functional constipation (95%)
Organic causes (5%)
<ul style="list-style-type: none">• Anal causes<ul style="list-style-type: none">• Fissures• Stenosis/atresia with fistula• Anterior displacement of anus• Trauma• Postsurgical repair• Neurogenic causes<ul style="list-style-type: none">• Hirschsprung's disease• Chronic intestinal pseudo-obstruction• Spinal cord disorders• Cerebral palsy/hypotonia• Pelvic mass• Neuromuscular disease• Endocrine/metabolic causes<ul style="list-style-type: none">• Hypothyroidism• Hypercalcemia• Lead intoxication• Drugs<ul style="list-style-type: none">• Codeine• Antacids• Others
Non-retentive encopresis
Non-organic (99%)
Organic (1%)
<ul style="list-style-type: none">• Severe ulcerative colitis• Acquired spinal cord disease (i.e., sacral lipoma, spinal cord tumor)• Recto-perineal fistula with imperforate anus• Postsurgical damage to anal sphincter

inefficient and ineffective gastrointestinal motility. Either of these factors alone but especially the two in combination offers an opportunity for a power struggle between the child and the parent over issues of autonomy and control; such battles often aggravate the disorder, frequently causing secondary behavioral difficulties. Many encopretic children, however, do not have behavioral problems, when behavioral problems do occur; they are social consequences of soiling (Kaplan and Sadock, 1984).

Encopretic children who are clearly able to control their bowel function adequately and who deposit feces of relatively normal consistency in abnormal places usually have a psychiatric difficulty (Kaplan and Sadock, 1984; Bharucha *et al.*, 2006; Joinson *et al.*, 2007).

Secondary encopresis sometimes appears to be a regression after such stresses as the birth of a sibling, a parental separation, a change in domicile, or the start of school (Kaplan and Sadock, 1984; Di-Lorenzo and Benninga, 2004).

This multi-centers study was designed to review of the literature and patients tickets to evaluate the diagnostic benefits of combining anal manometry, defecography and endosono-graphy and recently magnetic resonance image (MRI) scan, in the assessment of encopretic children and to recognize the specific type from which they suffer and to implement the best modality of treatment in addition to evaluate the rule of surgery in their management. We propose a multi-disciplinary approach with a somatic and psychological evaluation of the encopretic child. This study in addition to define encopresis, identify associated characteristics and clinical presentation; it also, describes diagnosis and treatment plans.

MATERIALS AND METHODS

Eighty-five children with encopretic symptoms were picked up from the attendant children presented or referred to surgery department; at Al-Azher University Hospitals, Biala Hospital, Kafer El-Sheikh Health Insurance Clinics and Mansoura International Hospitals; at the period from October 2002 to December 2008. Twenty patients of them had surgical problems (five of them was corrected previously, while other fifteen were presented without any surgical interference); the last twenty patients were without any surgical problem (idiopathic type) The admission criteria included complete medical work up: Careful History, Physical Examination, Both allow the physician to make a decision regarding requirements for blood studies (e.g., deficiency or excess of thyroid or adrenal hormones, electrolyte imbalances and calcium level). Urine analysis and culture, stool analysis, complete blood picture, plain X-Ray abdomen (which was very helpful in assessing the presence or absence of retained stool, its extent and whether the lower spine is normal in encopretic children), abdominal ultra sonography; P/R examination, barium enema (Fig. 1) and rectal biopsy for suspected case of Hirschsprung's disease to confirm diagnosis and fulfillment of the criteria for encopresis (involuntary or intentional repeated passage of feces into inappropriate places e.g., clothing or floor); with frequency of at least once a month for at least 3 months and patient age of 4 years or more. All children were subjected to anal manometry (Ano-rectal manometry that was performed using a triple lumen catheter attached to a hydraulic manometry infusion system (Fig. 2) (intact recto-anal inhibitory reflex); Fig. 3 indicating Anorectal Manometry Report: Maximum Resting Pressure: 58 mm Hg (Hypertonia) and Fig. 4 indicating Anorectal Manometry Report: Maximum Squeeze Pressure: 78 mm Hg; Fig. 5 indicating Anorectal Manometry Report: Maximum Squeeze Pressure: 65, 48 and 55 mm Hg; Fig. 6 indicating Anorectal Manometry Report: Maximum Squeeze Pressure: 65, 48 and 55 mm Hg and Fig. 7 indicating Anorectal Manometry Report: Maximum Resting Pressure: 22 mm Hg (Hypotonia); defecography and some for rectal endosonography and MRI scan.

We were dealing with organic causes firstly, with follow up of those patients and other associated psychosomatic pathologies were recorded. The treatment protocol adopted in these cases was:

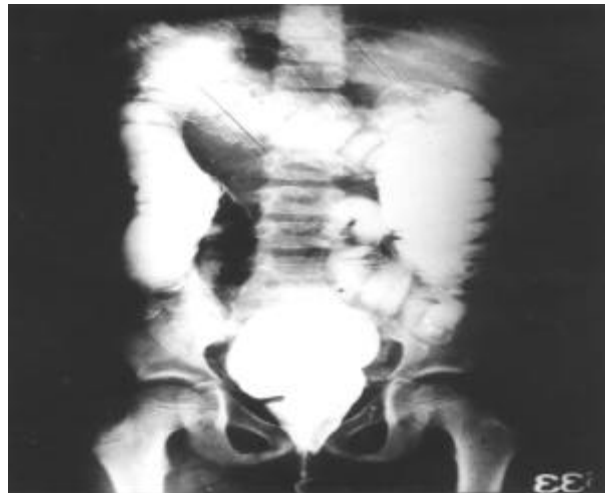

Fig. 1: Barium Enema of Hirsh Sprung's Encopretic child

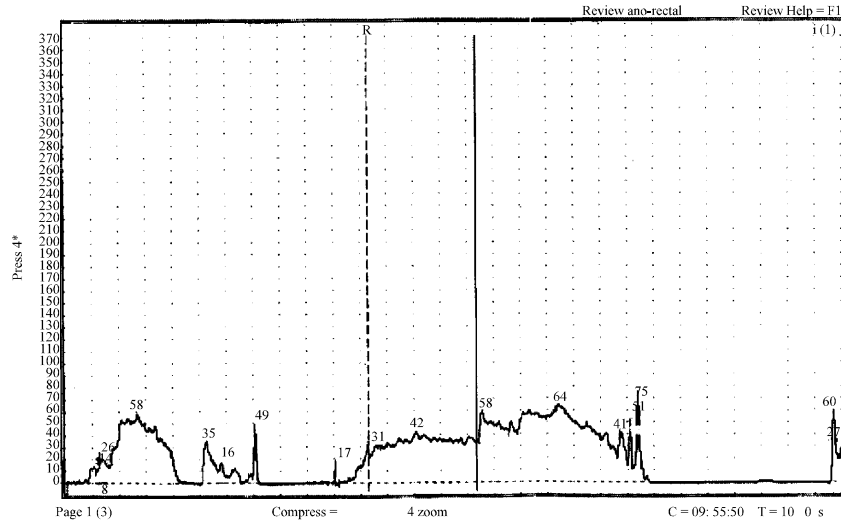


Fig. 2: Anorectal manometry report: Intact Recto-anal Inhibitory reflex (younger child)

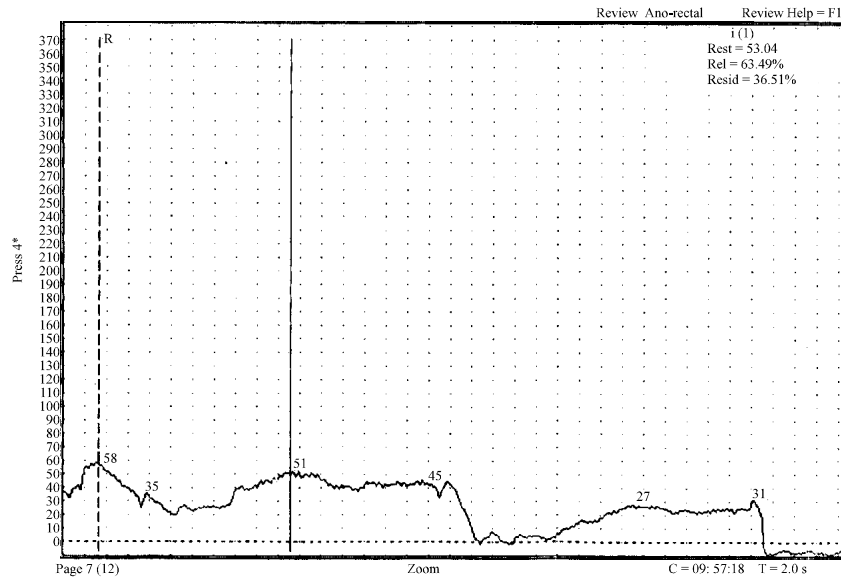


Fig. 3: Anorectal Manometry report: Maximum resting pressure: 58 mm Hg-Hypertonia (Normal R.P.:35-43 mm Hg)

Surgical Approach

Forty-five cases were underwent surgical procedures, 8 cases of anal fissures were operated upon by lateral sphinctrotomy under general anesthesia; 3 cases of anal stenosis were operated upon by cut back (posterior division to remove about 1 cm of fibrous ring with a triangular piece of the skin removed, its apex above in such a way as to ensure complete and adequate enlargement of stenosed region); the 6 cases of Hirsch Sprung's disease were operated upon by modified stapled Duhamel's operation to preserve rectal sensation and

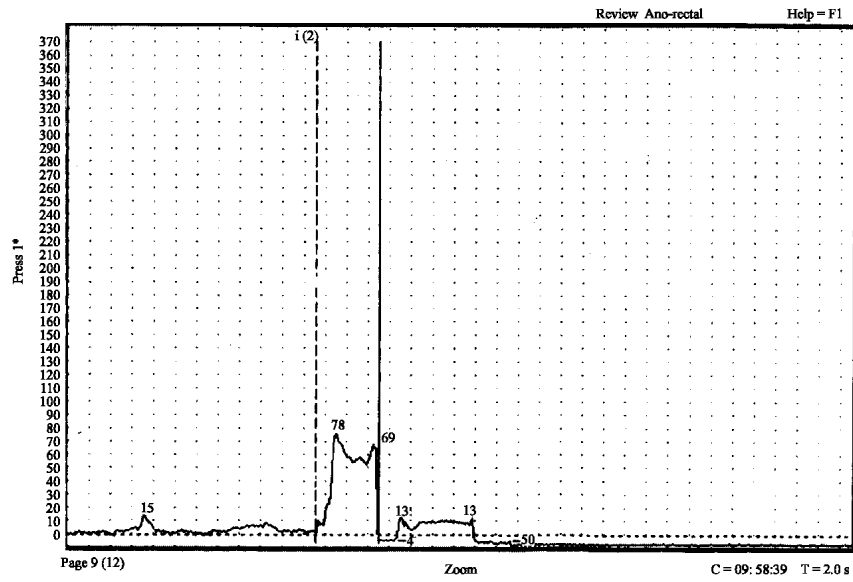


Fig. 4: Anorectal Manometry report: Maximum squeeze pressure: 78 mm Hg Hypotonia (Normal SQZP: 90-105 mmHg)

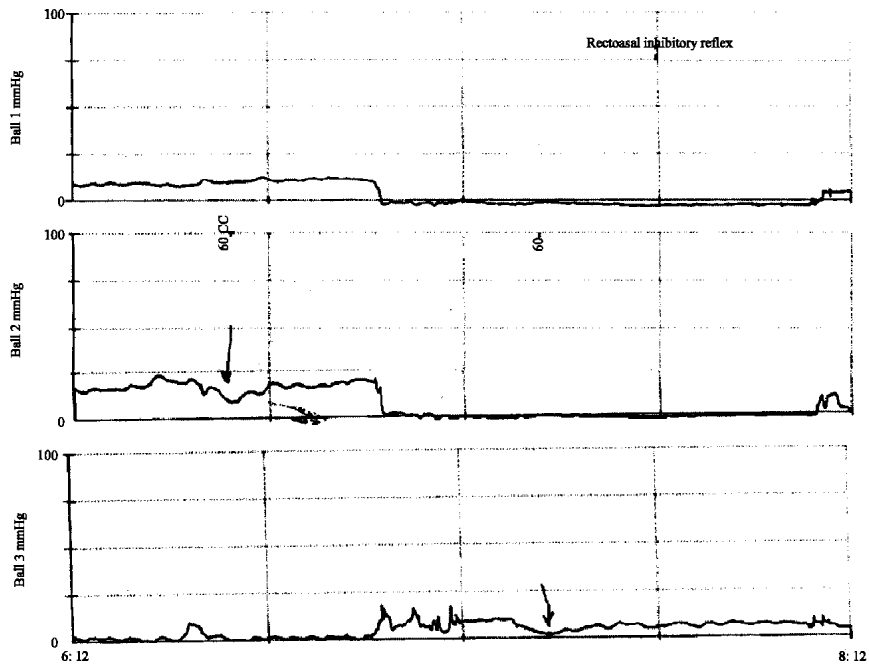


Fig. 5: Anorectal Manometry report: Maximum squeeze pressure: 65, 48 and 55 mmHg- Hypotonic (Normal SQZP: 100-180 mmHg)

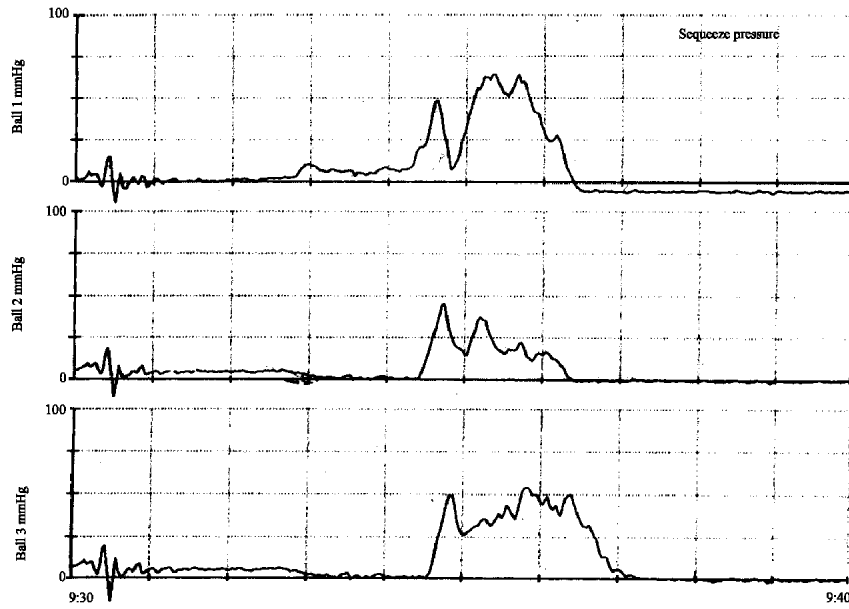


Fig. 6: Anorectal Manometry Report: Maximum squeeze pressure: 65, 48 and 55 mm Hg- Hypotonic (Normal SQZP: 100-180 mmHg)

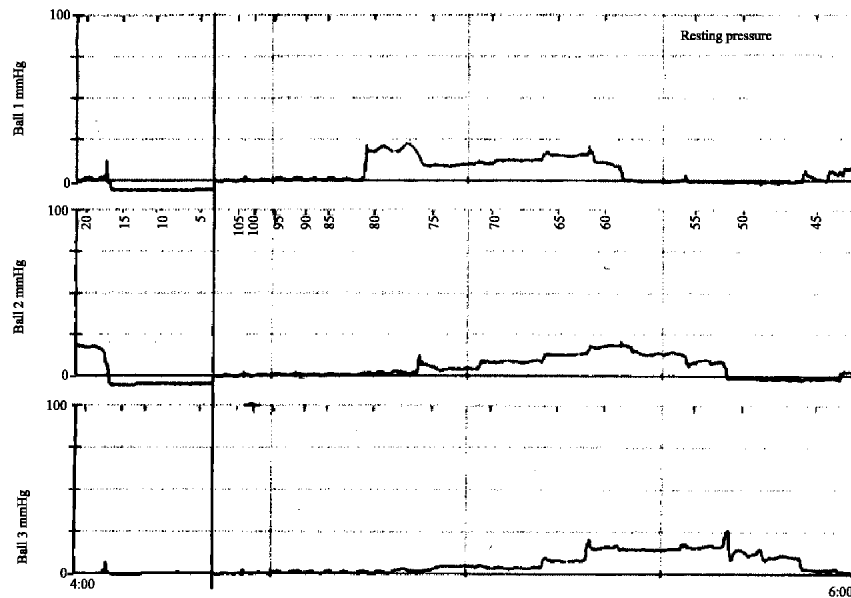


Fig. 7: Anorectal manometry report: Maximum resting pressure: 22 mm Hg-Hypotonia (Normal R.P.:50-90 mm Hg)

storage capacity, the colon was seized and brought down to present at the anus through 2 cm an opening in the rectum, 2 cm above the dentate line by the EEA stapler size 21 was

used to allow free communication between the colon and rectum; while the last 2 cases of rectovestibular fistula with imperforate anus (ectopic anus) were operated upon by modified midline perineal anorectoplasty with anal transposition to normal anal site through anal sphincters: the child in knee-elbow position with a sandbag under the pelvis, using a midline perineal incision continues around the fistula into the vestibule in a rocket like fashion: multiple 5/0 sutures are placed circumferentially at the fistula site, while traction is placed on these sutures, the rectum is dissected in a circumferential manners. The rectum must be mobilized as previously described to gain enough length to perform a tension free bowel skin anastomosis. The perineal body is then reconstituted by bringing together the anterior limit of the external sphincter. The anterior edge of the muscle complex is re-approximated. The levator muscle is usually not exposed and thus does not to be reconstructed. The muscle complex must, however, be reconstructed posterior to the rectum.

Medical Approach

To achieve complete evacuation of the bowels, i.e., disimpaction of the fecal mass via medical roots, which may need from 2-5 days (Croffie and Fitzgerald, 1996; Loening-Baucke, 1996a; Abi-Hanna and Lake, 1998); hypertonic phosphate enema was used. Some children needed to be hospitalized. In majority of children, 1-3 enemas were enough to achieve disimpaction. Soap water enemas were avoided as they may cause many complications as perforation and necrosis of the bowel (Loening-Baucke, 1996a). Also tap water enemas were avoided as they may cause water intoxication, hypo-natremia and seizures (Loening-Baucke, 1996a). Once dis-impaction and complete evacuation was achieved, the next step was to prevent re-accumulation of the stool. This was achieved by regular use of stool softness and laxatives such as lactulose (in dose: 1-3 mL/kg/day in two divided doses) and senna syrup (in dose: 5-10 mL with breakfast and maximum 10 mL bid). In addition to these laxatives regimen, dietary fiber, that contains cellulose and psyllium, was increased appropriately. The goal of this medical approach is to allow sufficient time for colon to return to normal caliber and tone in order to maintain regular bowel movements and prevent re-accumulation of stools (Loening-Baucke, 1996b; Abi-Hanna and Lake, 1998). After six months the children were weaned from laxatives gradually and at the same time encouraged to use toilet regularly after breakfast or evening meal to take advantage of the gastro-colic reflex.

A Modified Form of Psychiatric and Behavioral Approach

It described by Boon and Singh (1991), Howe and Walker (1992), Levin *et al.* (1992) and Kuhn *et al.* (1999), which included:

- Full description of treatment plan was introduced to the child and his parents, making clear that behavioral component is an integral part of the medical procedure
- Consent of children and their parents was taken to participate in the program
- Every child was examined clinically and completed with P/R, all previous medical workup was reviewed, especially the plain X-Ray abdomen to determine the presence of a severely impacted colon; if findings were positive (Retentive type encopresis); the patient was given an enema once daily for 5 days, followed in cases of failure by a more aggressive approach; paraffin oil was given 15-30 c.c. daily, adjusted for weight
- Diet was formulated based on high consumption of liquids (at least 2 L a day), fresh fruit juices and fiber, with a decrease in dairy products. An attempt must be done to fix diet and serve meals at fixed hours

- Parents were instructed to sit the child on toilet after each meal and ask him/her to defecate. After 10 min the parents were called to document the quantity and consistency of the feces
- If during the program, parents noted a smell of passed stool, the child was instructed to clean him/herself, wash his / her cloths and stay in his/her room alone for the duration of activity he/she was participating in at the time, like TV watching. Cooperation was noted and recorded
- If the patient had no bowel movement during the day, an enema was administered after the last meal (6 pm). The child was made aware that the enema was not a punishment, but a means to help the bowel regain normal activity
- Progress in control of bowel movements was rewarded by moving the patient to a higher level of the program gifts such as more television time, movies etc.
- Parents were instructed to avoid any criticism or comments regarding their child's progress or regression and to differentiate the child's behavior involving bowel movements from his/her other social or academic activities
- The child was discharged from the program after he/she achieved a successful week free of soiling and with regular defecation; but follow-up was continued for 3 months, 6 months and for one year

RESULTS

Eighty-five children, confirmed to be encopretic, were the subjects of our study, 64 males (75.3%) and 21 females (24.7%), their ages ranged from 4 to 13 years; 61 children < 10 years (71.8%) and 24 children > 10 years (28.2%); 22 of them were children for divorced parents (25.9%); 33 of them were the oldest of their parents (38.8%) and the last 30 were the youngest of their parents (35.3%); these demographic data were shown in Table 2.

Children in the present study were classified, on the bases of clinical examination and plain X-Ray at the time of presentations, into two sub groups: group A of 26 children (30.6%): primary encopresis (non-retentive type) and group B of 59 children (69.4%): secondary encopresis (retentive type), where conservative approaches were succeeded in 34 patients (57.6%) to evacuate the colon, but failed in 25 patients (42.4%); where cleaning procedure under general anesthesia (operative evacuation) was done; the procedure was successful in 21 patients (35.6%), but 4 children (6.8%) needed a series of repeated enemas; Table 3.

As regard results of anal manometry, defecography, endosonography and magnetic resonance image scan (MRI); in group (A): resting incontinence was associated with a hypo-tonic external sphincter in 7 of 26 children (26.9%), 5 (19.2%) of whom had internal anal

Table 2: Demographic data in the present study

Items	No.	%
Age		
<10 years	61	71.8
>10 years	24	28.2
Sex		
Male	64	75.3
Female	21	24.7
Family status		
Children for divorced parents	22	25.9
Oldest child for parents	33	38.8
Youngest child for parents	30	35.3

Table 3: Classification of encopretic children in this study

Groups	No.	%
Group (A): Primary encopresis (non-retentive type)	26	30.6
Group (B): Secondary encopresis (Retentive type):		
Conservative evacuation:	59	69.4
Operative evacuation (under general anesthesia):	34	57.6
Successful evacuation:		
Failed and need frequent enemas:	25	42.4
	21	35.6
	4	6.8
Total	85	100

Table 4: Results of manometry, defecography, endosonography and mri scan in this study

Item	No.	%
1-Group (A): (26 children)		
Hypo-tonic external sphincter	7	26.9
Thinning internal sphincter	5	19.2
2-Group (B): (59 children)		
Hypo-tonic external sphincter	19	32.2
Thinning internal sphincter	11	18.6
Total (85 children)	26	30.6
	16	18.8

sphincter thinning, while in group (B) resting incontinence was associated with a hypo-tonic external sphincter in 19 (32.2%) of 59 patients, 11 (18.6%) of whom had internal anal sphincter thinning; i.e., 26 children (30.6%) of total 85 encopretic children had sphincters problems in the form of hypotonic external sphincter; 16 (18.8%) of them had thinning of the internal sphincter. These data were shown in Table 4.

As regard the surgical management, Forty-five children in group B (76.3%) were due to surgical causes, 15 postoperative (25.4%) and 30 without operation (50.8%): 11 of them with anal fissures (18.6%), 3 with anal stenosis (5.1%), 13 with Hirsch Sprung's disease (22.0%), while the last 3 cases were with recto-perineal fistula and imperforate anus (5.1%). The 15 patients (25.4%) presented postoperatively with encopresis, had residual surgical problems in 10 patients (16.9%) and free for the last 5 patients (8.5%). For 10 patients group with residual surgical problems, surgical redo correction for these patients were taken place in the form of revision for 5 cases with improper correction of recto-vaginal and vestibular fistulas, 4 cases with recurrent symptoms after surgical repair of Hirsch Sprung's disease that need revision of the surgery; two cases of them were with retraction of rectum and anal stenosis that needed another pull through operation. The last case was fibrous anal stenosis that needed V-Y flap anoplasty. These results were shown in Table 5 and 6.

The Therapeutic Integrative Program (TIP) which was based on full parents and patients cooperation and involved medical intervention combined with modified behavioral therapy with parental education and guidance; i.e., multi-modal therapy. By revision of "Child Behavior Chick List"(CBCL) before randomization in the therapeutic program at and after follow-up. We found that, in group (A) of 26 children with primary non-retentive encopresis, 23 children (88.5%) were completely free of symptoms and soiling after 6 months of beginning of the program and reaching to 25 children (98.2%) after completion of the first year; while in the second group (B) of 59 children with secondary retentive encopresis, 10 cases from the surgically managed group (45 children) were added to our therapeutic program, so this group was consisted of these 10 patients in addition to 14 patients, added from the start (24 patients); 6 children (25%) were completely free of symptoms and soiling after 6 months from the beginning of the program and was reaching to 17 children (70.8%)

Table 5: Surgical indications in our study

Items	No.	%
Needs surgical management	30	50.8
Anal fissures	11	18.6
Anal stenosis	3	5.1
Hirschsprung's disease	13	22.0
Recto-perineal fistula and imperforate anus	3	5.1
Needs surgical correction	15	25.4
Residual surgical problems	10	16.9
Free postoperative	5	8.5
Total	45	76.3

Table 6: Results of surgical treatment in 45 cases

Clinical diagnosis	No. %	Surgical treatment	Cured %
Needs surgical management			
Anal fissures	11 24.4	• Sphinctrotomy	11 24.4
Anal stenosis	3 6.7	• Cut Back	0 0
Hirschsprung's disease	13 28.9	• Modified stapled Duhamel op.	11 24.4
Recto-perineal fistula and imperforate anus	3 6.7	• Modified ant. Sag. Ano-rectoplasty.	3 6.7
Needs surgical correction			
Residual surgical problems	10 22.2	• Repair	10 22.2
• Correction of recto-vaginal and vestibular fistulas	5	• Another pull-through	
• Revision of the surgery after H.S	4	• Tight anoplasty with V-Y flap repair	
• Fibrous anal stenosis:	1		
Free postoperative	5 11.1		5 11.1
Total	45 100	Total	40 88.8

Table 7: Success results of multi-modal therapeutic program in our study

Item	After 6 month		After one year	
	No.	%	No.	%
1-Group (A): (26 patients)	23	88.5	25	98.2
2-Group (B): (24 patients)	6	25.0	17	70.8
Total	29/50	58.0	42/50	84.0

Table 8: Rate of remission after long-term follow-up (mean 30 months)

Item	No.	%
1-Group A (26)	0	0
2-Group B (59)	3	6.0
Total (85)	3/85	3.5

Table 9: Failure rate of encopresis therapy

Item	No.	%
Total (85)	9/85	10.6

after completion of the first year. The total result of the multi-modal therapy was 29 patients response (58.0%) of 50 patients including 10 cases from the surgically managed group after 6 months and increased to 42 patients response (84.6%) after one year. These figures were shown in Table 7.

As regard the long-term results (> 36 months); measures consisted of regular recording and analysis of clinical follow-up charts and parents reports (C B C L) of child soiling status. At follow-up (mean duration 30 months, range 15 to 49 months); 3 children (6.0%) were in remission, all in the group (B) of secondary retentive encopretic children; while the 9 children (18.0%) whom did not respond to therapy still soiling with general un-responding rate of 9/85 children (10.6%); the general remission rate was 3/85 (3.5%); this was shown in Table 8 and 9.

DISCUSSION

The reported prevalence of encopresis in childhood is 2-3% in boys and 0.3-0.7% in girls at age 7-8 years (Biswas and Berg, 1986) and 1.3 and 0.3% in boys and girls, respectively, at ages 10-12 years (Rutter *et al.*, 1970). Precise figures for adolescents are not available (Fennig and Fennig, 1999). Yet most parents are unaware of the condition. Parents frequently view encopretic symptoms as deliberate actions and react punitively. Children with encopresis live constant fear of ridicule about a problem over which they have no control (Chaney, 1995).

As regard radiological investigations, Varea-Calderon *et al.* (2000) stated that anal manometry, defecography and endosonography are complementary procedures in the assessment of this group of encopretic children, while Sutphen *et al.* (1997) concluded that ano-rectal manometric examination in encopretic children is very essential especially to detect anal sphincters spasm and associated patho-physiologic abnormalities e.g., mega-colon. Also, Stuhldreier *et al.* (1997) stated several advantages of the three-dimensional endosonography compared with conventional examination, as this new system is able to produce an image of the entire pelvic floor including the sphincter muscles and the rectal wall even in small children.

Most of the present study; patients underwent previous treatment for encopresis, using enemas, laxatives, or medications; frequently, they were given in an indiscriminate manner. Not only did they fail to keep the patient clean, but many times they actually worsened the patient situation. Many factors contribute to fecal continence; the importance of the levator ani muscle and the external sphincter has been appropriately emphasized. However, other factors that may contribute to fecal continence preclude sensation and proprioception.

In present study according to the options mentioned by Freeman (1989) and Malone *et al.* (1990), modified Duhamil's procedure was preferred for treating patients with Hirsch Sprung's disease, with least pelvic dissection around the rectum, to keep the normal anatomical relation between it and the surrounding pelvic musculature, that was lost in other available surgical procedures for Hirsch Sprung's disease and preserving rectal mucosa that contains sensory never ending for proprioceptive sensation for rectal contents as wind and solid. However, the role of the internal anal sphincter fecal continence is still debatable. Yoo *et al.* (1995) found that the Internal Anal Sphincter (IAS) was contributory to resting anal tone, but not essential for anal incontinence. Some investigators have attempted to isolate the contribution of the IAS to the resting tone by various pressure measurements. Whatever the IAS is preserved or not, abnormal bowel function after operation on ano-rectal malformation is still present in significant number of patients. Reported that the preservation of the IAS could rather result in severe constipation by inhibition or rectal propulsion. However, patients treated with modified Duhamel's reconstruction had 32% of them reported difficulty of defecation with constipation associated with fecal soiling post operatively; (Bill *et al.*, 1996). Also, Rintala (2002) explained that the constipation after ano-rectoplasty might be caused by not only the partially denervated distal rectum during operation, the histologic change of the ectopic anal canal and the congenital rectal dilatation, but also by the well preserved IAS and External Anal Sphincter (EAS).

Fecal incontinence can be devastating to the emotional and social development of children. Ano-rectal malformation affects 1 in 5000 newborns and at least 30% of these children will be fecal incontinent after corrective surgery. In addition, approximately one half of children who have spine bifida suffer from fecal incontinence as do some children who have Hirsch Sprung's disease with intractable constipation (Fennig and Fennig, 1999). The same was detected in other literature, as adolescents with ano-rectal anomalies often present

with impaired fecal control, even if the external sphincter are anatomically present and there are no neurological abnormalities present. Also, some degree of local incontinence may occur often surgery for Hirsch Sprung's disease, this lead to an adverse effect on quality of life, which may lead to profound psycho-emotional disturbance so they need starting an anal reeducation progress, while is now offend to all children with fecal incontinence often surgery (Patel and Pratt, 1999). Some patients who have fecal incontinence may improve significantly with an operation. Those who do not improve, have three alternatives to deal with fecal incontinence. If nothing is done, the child will soil their clothing or diaper and incur social or psychological squeals. A diverting colostomy is a second option, in which case the family is burdened by the need for colostomy care as well as the emotional drain inflicted on a child who most live with a colostomy. A third option involves the implementation of a bowel management program whereby, through the use of a daily enema, manipulation of diet and some medication, children can remain clean 24 h a day. In present study experience, this program has proven effective for the most majority of focally incontinent children (Hedlined and Pena, 1990).

The therapeutic means directed towards the different etiologic and symptomatic features. Explanations of patho-physiology of the symptoms and discussion with the child and parents must be accomplished first. The primary non-retentive type of encopresis, in the present study, represented 14/25 (56%) of children, which referred to inappropriate soiling without evidence of fecal constipation and retention. In the literature, this form of encopresis accounted for up to 20% of all encopretic cases (Kuhn *et al.*, 1999), characteristics included soiling accompanied by daily bowel movements that are normal in size and consistency.

An organic cause for this type (non-retentive encopresis) is rarely identified, the present study reported only mild hypo-tonic external sphincter in 3 cases (12%) and thinning internal sphincter in 2 cases (8%); also the medical assessment was normal and signs of constipation were noticeably absent. Full developmental and behavioral assessments were made, this to establish that the child was ready for intervention to correct encopresis and to identify any barriers to success. The reported success rate for our multi-modal therapy of 12/14 children (85.7%) after one year follow-up without relapse or remission. These results were better than reported by Patel and Pratt (1999), who reported a rate up to 50-60% of children with acceptable bowel control and free of soiling within a year and near to results of Reid and Bahar (2006) who reported 95% rate (38\40 children) for successful mode of psychologically based therapy for these children. While Taubman and Buzby (1997) reported only 1 of 12 children (8.3%) with primary encopresis was free of soiling and no longer receiving therapeutic medication at one year.

The secondary retentive encopresis, where there was constipation, impaction of stool and subsequent leakage of fecal material; as the child had control but reverted and lost it. For all techniques, aggressive preoperative bowel preparation is essential to facilitate the initial postoperative enema and broad-spectrum antibiotics, to cover bowel flora, are recommended (Griffin *et al.*, 2008).

The present study reported a success rate for the multi-modal therapy in this type: 5/11 children (45.5%) after one year follow-up. This rate was less than reported by Stark *et al.* (1997); who reported 86% stopping soiling by the end of treatment and did not require further treatment and also less than reported by Taubman and Buzby (1997) who reported 21 of 37 children (56.9%) were free of soiling after one year.

Other surgical options may focus on correction of sphincteric defects. In patients with ano-rectal malformations, reassessment and re-do ano-rectal pull-through surgery are commonly performed. Keshtgar *et al.* (2007) stated that excision of mega-rectum or

mega-sigmoid has resulted in improved symptoms of constipation and overflow faecal continence in children with previous ano-rectal malformation. Such symptoms are particularly likely to improve in low ano-rectal malformations with the presence of a good internal anal sphincter and an absence of neuropathy. High anomalies with poorer sphincters and associated sacral anomalies are more likely to benefit from the stasis of a dilated rectum to enhance continence.

As regard Bio-feed-back training or Balloon defecation options for management of encopresis cases many reports in the literature stated that Biofeedback training had no additional effect on success rate or behavior scores (Loening-Baucke, 1995, 1996b; VanDer Plas *et al.*, 1996; Brazzelli and Griffiths, 2006). In contrast; Sutphen *et al.* (1997), Faure *et al.* (1999), Iwata *et al.* (1995), Cox *et al.* (1996) and Griffiths *et al.* (1999) all reported that biofeedback training and treatment represents an interesting role in management of such children.

All patients in the present study had undergone years of treatment with medical measures. Under the multi-model treatment program for encopretic children, 84% of children (42\50 children) stopped soiling after one year (25\26 in group A: 98.2%) and (17\24 in group B: 70.8%). Those responded children were symptoms-free after this period and no relapse was observed on follow-up in group (A) while 3\59 cases (5.1%) were in remission in group (B); with total remission rate 3\85 cases of 3.5%.

Observations in this study that patients in group (B) of retentive type were showed no shame or stress regarding their symptoms and they were initially reluctant to cooperate and demonstrated detachment, isolation and passive-aggressive tendencies. They were more difficult to motivate and their participation in the program was passive. These characteristics are similar to those described by Bemporad *et al.* (1971) and Brazzelli and Griffiths (2006). However, we found that once therapeutic contact was made, we received full cooperation.

In this study there were only 22 encopretic children for divorced parents (25.9%) and this did not agree with that in literature (may be because of Islamic nature of our community that refuse and discard divorce); which showed an unexpectedly high rate of parental divorce or separation (Bemporad *et al.*, 1971; Baird, 1974; Ringdahl, 1980; Brazzelli and Griffiths, 2006) and all the couples exhibited a high level of hostility and inability to work together and to cooperate with the treatment program. Owing to this high level of conflict and hostility, this work with the parents focused on the child's symptoms and the way to help him\her according to the condition.

This study try to reduce the family tension and parental animosity induced by symptoms, this by emphasizing to the parents that although the encopresis might have been the route their son/daughter took to express his/her frustration, anger, hostility and opposition in childhood, so in adolescence it had become autonomous and a distinct entity.

None of the therapeutic modes and interventions, we used, were by themselves new and most had already been presented to the families in earlier treatments. We attributed our percent (84% after one year) of success of the program to implication of the psychological impact, which confirming that change is needed as the disconnection from daily routine and the familial environment facilitated the change. The adolescent child was made aware that he or she alone was responsible for elimination of the symptoms.

Seth and Heyman (1994), it was found that parents viewed the soiling with anger and frustration and the parent-child relationships were contentious. Also, it was agreed with Nolan and Oberklaid (1993) that "home-administered enemas or suppositories are vastly superior to the frequently traumatic ritual of bowel washouts or naso-gastric polyethylene glycol infusion in the hospital. While, in contrast to this, Fennig and Fennig (1999) found

that these procedures to be far less traumatic when done by professional nurses than by the parents and they reported 100% response to their therapeutic program on admission bases; as parents would find it disturbing to administer an enema to their children and performing the procedure in the hospital avoided the tension and conflicts around both soiling and the medical treatment. Also, Ringdahl (1980) concluded that the inpatient setting for encopretic children was advantageous because it stopped the hostile power struggle between children and parents.

CONCLUSIONS

Problems such as encopresis are perceived as “normal“, for some populations. Encopresis is the involuntary loss of formed, semi-formed or liquid stool into the child’s underwear in the presence of functional (idiopathic) constipation in a child 4 years of age or older. Physical examination and plain x-ray abdomen assess in diagnosis and classification. Anal manometry, defecography, endosonography and recently MRI scan are complementary procedures in the assessment of this group of patients. The multi-modal integrative therapy program was based on full patients and parents cooperation with using medical intervention combined with modified behavior therapy. This new approach will improve the knowledge of the pathogenesis of these disorders in children. Treatment is considered effective when the child has been “clean” for 6 months. The integrative multi-therapeutic program is very effective (98.2% without remission) in management of primary non-retentive encopretic children while surgery is the way to manage the secondary retentive encopretic children (84%). Relapses may occur. However, further studies are needed to find out a new tool especially in surgical field to deal with the non-responded cases (10.6%) and to obtain conclusive evidence.

REFERENCES

- Abi-Hanna, A. and A.M. Lake, 1998. Constipation and encopresis in children. *Paediatr. Rev.*, 19: 23-31.
- American Psychiatric Association, 1987. *Diagnostic and Statistical Manual of Mental Disorders. 4th Edn., (DSM-IV)*. American Psychiatric Association, Washington, DC.
- American Psychiatric Association, 1994. *Diagnostic and Statistical Manual of Mental Disorders. 4th Edn., (DSM-IV)*. American Psychiatric Association, Washington, DC.
- American Psychiatric Association, 2000. *Diagnostic and Statistical Manual of Mental Disorders. 4th Edn., Text Revised (DSM-IV)*. American Psychiatric Association, Washington, DC.
- Amserdam, B., 1979. Chronic encopresis: A system based psychodynamic approach. *Child Psychiatry Hum. Dev.*, 3: 139-144.
- Ayllon, T., J. Simon and R.W. Wildman, 1975. Instructions and reinforcement in the elimination of encopresis: Case study. *J. Behav. Ther. Exp. Psychiatry*, 6: 235-238.
- Baird, M., 1974. Characteristic interaction patterns in families of encopretic children. *Bull. Menninger. Clin.*, 38: 144-153.
- Behrman, R.E. and R.M. Kliegman, 1998. *Nelsson Essentials of Paediatrics. 3rd Edn.*, W.B. Saunders, USA.
- Behrman, R.E., R.M. Kliegman and H.B. Jenson, 2000. *Nelson Textbook of Paediatrics. 16th Edn.*, W.B. Saunders, USA.

- Bemporad, J.R., C.M. Pfeifer, L. Gibbs, R.H. Cortner and W. Bloom, 1971. Characteristics of encopretic patients and their families. *J. Am. Acad. Child psychiatry*, 10: 272-292.
- Bharucha, A.E., A. Wald, P. Enck and S. Rao, 2006. Functional anorectal disorders. *Gastroenterology*, 130: 1510-1518.
- Bill, J.R.D.P., D. Tapper and J.M. Anderson, 1996. Does postero-sagittal anrectoplasty in patients with high imperforate anus provide superior fecal continence?. *J. Redic. Surg.*, 31: 26-32.
- Biswas, S. and I. Berg, 1986. Childhood encopresis extended into adult life. *Br. J. psychiatry*, 149: 494-499.
- Boon, F.F. and N.N. Singh, 1991. A model for the treatment of encopresis. *Behav. Modif.*, 15: 355-371.
- Borowitz, S., L.M. Ritterband, J.C. Magee, F. Thorndike and D. Cox, 2008. Treatment of childhood encopresis with an Internet-based intervention. Poster Session Presented At The Annual Meeting of the Pediatric Academic Societies, Honolulu, HI.; (E-PAS2008:5802.3).
- Brazzelli, M. and P. Griffiths, 2006. Behavioral and cognitive interventions with or without other treatments for the management of faecal incontinence in children. *Cochrane Database Syst. Rev.*, 19: CD002240-CD002240.
- Buttross, S., 1999. Encopresis in the child with a behavioral disorder: When the initial treatment does not work. *Pediatr. Ann.*, 28: 317-321.
- Chaney, C.A., 1995. A collaborative protocol for encopresis management in school-aged children. *J. School Health*, 65: 360-364.
- Cox, D.J., J. Sutphen, W. Ling, W.J. Quillian and S. Borowitz, 1996. Additive benefits of laxative, toilet training and biofeedback therapies in the treatment of pediatric encopresis. *J. Pediatr. Psychol.*, 21: 659-670.
- Croffie, J.M.B. and J.F. Fitzgerald, 1996. Idiopathic Constipation. In: *Paediatric Gastrointestinal Disease*, Walker, W.A., R.R. Durie, J.R. Hamilton, J.A. Walker-Smith and J.B. Watkins (Eds.). 2nd Edn., Mosby-Yearbook, St. Louis, USA., pp: 984-99.
- Di Lorenzo, C. and M.A. Benninga, 2004. Pathophysiology of pediatric fecal incontinence. *Gastroenterology*, 126: S33-S40.
- Faure, C., O. Goulet, S. Ategbro, A. Breton and P. Tounian *et al.*, 1999. Chronic intestinal pseudoobstruction syndrome: Clinical analysis, outcome and prognosis in 105 children. *Dig. Dis. Sci.*, 44: 953-959.
- Fennig, S. and S. Fennig, 1999. Management of encopresis in early adolescence in a medical-psychiatric unit. *Gen. Hosp. Psychiatry*, 21: 360-367.
- Freeman, N.V., 1989. Ano-rectal problems in childhood. *Progr. Surg.*, 3: 86-100.
- Freeman, N.V., 1993. Other pediatric functional disorders. *Surg. Anus*, 74: 2415-2425.
- Griffin, S.J., E.J. Parkinson and P.S.J. Malone, 2008. Bowel management for paediatric patients with faecal incontinence. *J. Pediatr. Urol.*, 4: 387-392.
- Griffiths, P., S. Dunn, A. Evans, D. Smith and M. Bradnam, 1999. Portable biofeedback apparatus for treatment of anal sphincter dystonia in childhood soiling and constipation. *J. Med. Eng. Technol.*, 23: 96-101.
- Hatch, T.F., 1988. Encopresis and constipation in children. *Pediatr. Clin. N. Am.*, 35: 257-280.
- Hedlined, H. and A. Pena, 1990. Does the distal rected muscle in anorectal malformation have the functional properties of a sphincter?. *J. Pediatr. Surg.*, 25: 985-998.
- Howe, A.C. and C.E. Walker, 1992. Behavioral management of toilet training, enuresis and encopresis. *Pediatr. Clin. North Am.*, 39: 413-432.

- Iwata, G., N. Iwai, M. Nagashima and R. Fukata, 1995. New biofeedback therapy in children with encopresis. *Eur. J. Pediatr. Surg.*, 5: 231-234.
- Joinson, C., J. Heron, R. Butler, A. Von Gontard, U. Butler, A. Emond and J. Golding, 2007. A United Kingdom population-based study of intellectual capacities in children with and without soiling, daytime wetting and bed-wetting. *Pediatrics*, 120: e308-e316.
- Kaplan, H.I. and J.B. Sadock, 1984. *Elimination Disorders: Synopsis of Psychiatry*. 8th Edn., Williams and Wilkins, Baltimore, pp: 764-768.
- Keshtgar, A.S., H.C. Ward, C. Richards and G.S. Clayden, 2007. Outcome of excision of megarectum in children with anorectal malformation. *J. Pediatr. Surg.*, 42: 227-233.
- Kuhn, B.R., B.A. Marcus and S.L. Pitner, 1999. Treatment guidelines for primary non-retentive encopresis and stool toileting refusal. *Am. Fam. Physician*, 59: 2171-2178, 2184-2186.
- Levin, M.D., W.B. Carey and A.C. Crocker, 1992. *Developmental-Behavioral Paediatrics*. 2nd Edn., W.B. Saunders, Philadelphia, pp: 394.
- Loening-Baucke, V., 1990. Modulation of abnormal defecation dynamics by biofeedback treatment in chronically constipated children with encopresis. *J. pediatr.*, 116: 214-222.
- Loening-Baucke, V., 1995. Biofeedback treatment for chronic constipation and encopresis in childhood: Long-term outcome. *Pediatrics*, 96: 105-110.
- Loening-Baucke, V., 1996a. Biofeedback training in children with functional constipation. A critical review. *Dig. Dis. Sci.*, 41: 65-71.
- Loening-Baucke, V., 1996b. Encopresis and soiling. *Pediatr. Clin. North Am.*, 43: 279-298.
- Loening-Baucke, V.A., 1984. Sensitivity of the sigmoid colon and rectum in children treated for chronic constipation. *J. Pediatr. Gastroenterol. Nutr.*, 3: 454-459.
- Malone, P.S., P.G. Ransley and E.M. Kiely, 1990. Preliminary report: The antegrade continence enema. *Lancet*, 336: 1217-1218.
- Nolan, T. and F. Oberklaid, 1993. New concepts in the management of encopresis. *Pediatr. Rev.*, 14: 447-455.
- Patel, D.R. and H.D. Pratt, 1999. Encopresis. *Indian J. Pediatr.*, 66: 439-446.
- Reid, H. and R.J. Bahar, 2006. Treatment of encopresis and chronic constipation in young children: Clinical results from interactive parent-child guidance. *Clin. Pediatr.*, 45: 157-164.
- Ringdahl, I.C., 1980. Hospital treatment of the encopretic child. *Psychosomatics*, 21: 65-71.
- Rintala, R., 2002. Fecal incontinence in anorectal malformation, neuropathy and miscellaneous conditions. *Semin. Pediatr. Surg.*, 11: 75-82.
- Rutter, M., J.R. Tizard and K. Whitmore, 1970. *Education, Health and Behavior*. Longman Publication, London.
- Seth, R. and M.B. Heyman, 1994. Management of constipation and encopresis in infants and children. *Gastroenterol. Clin. North Am.*, 23: 621-636.
- Stark, L.J., L.C. Opiari, D.I. Donaldson, M.B. Danovsky, D.A. Rasile and A.F. DelSanto, 1997. Evaluation of a standard protocol for retentive encopresis: A replication. *J. Pediatr. Psychol.*, 22: 619-633.
- Stuhldreier, G., H.J. Kirschner, W. Astfalk, P. Schweizer, P.E. Huppert and J. Grunert, 1997. Three-dimensional endosonography of the pelvic floor: An additional diagnostic tool in surgery for continence problems in children. *Eur. J. Pediatr. Surg.*, 7: 97-102.
- Sutphen, J., S. Borowitz, W. Ling, D.J. Cox and B. Kovatchev, 1997. Anorectal manometric examination in encopretic-constipated children. *Dis. Colon. Rectum.*, 40: 1051-1055.
- Taubman, B. and M. Buzby, 1997. Overflow encopresis and stool toileting refusal during toilet training: A prospective study on the effect of therapeutic efficacy. *J. Pediatr.*, 131: 768-771.

- Van Der Plas, R.N., M.A. Benninga, W.K. Redekop, J.A. Taminiou and H.A. Buller, 1996. Randomized trial of biofeedback training for encopresis. *Arch. Dis. Child*, 75: 367-374.
- Van Der Wal, M.F., M.A. Benninga and R.A. Hirasing, 2005. The prevalence of encopresis in a multicultural population. *J. Pediatr. Gastroenterol. Nutr.*, 40: 345-348.
- Varea-Calderon, V., L. Delgado-Carbajal, E. Camacho-Diaz, M. Estringana-Perez and E. Alert-Casas, 2000. Role of manometry, defecography and endosonography in the evaluation of colorectal disorders. *Rev. Esp. Enferm. Dig.*, 2: 147-159.
- Yoo, S.Y., K.S. Bae, S.J. King, S.Y. Kim and E.H. Hmany, 1995. How important is the role of the internal and sphincter in fecal continence? An experimental study in Dog. *J. Pediatr. Surg.*, 30: 687-691.