



Trends in
Medical Research

ISSN 1819-3587



Academic
Journals Inc.

www.academicjournals.com

Research Article

Pericapsular Nerve Group (PENG) Block for Hip Fracture Surgeries: An Observational Study

Sangeeta Khanna, Krishna Prasad and Vipin Sharma

Department of Anaesthesia, Military Hospital in Pune, Maharashtra, India

Corresponding Author: Krishna Prasad (drkaypee99@yahoo.com)

ABSTRACT

Background: Pericapsular Nerve Group (PENG) Block is a relatively new technique for postoperative pain blockade. This is a simple method of the plane block where the pain pathway is blocked by using a simple injection on accessory obturator nerve and femoral nerve that mainly innervates anterior hip capsule. This observational study aimed to evaluate the efficacy of Pericapsular Nerve Group (PENG) Block in patients undergoing hip surgeries.

Materials and Methods: A total of 50 patients with different hip pathologies such as femur head fracture, intertrochanteric fractures etc who are scheduled for hip surgeries were included. After the completion of surgery as a post-operative analgesia, every patient received PENG block (0.25% Ropivacaine with 25 mcg of Dexmedetomidine). Paracetamol IV was given along with the PENG block every 8 hrs. In patients who had a pain score of more than 4 a tramadol injection is given as rescue analgesia. Various demographic information, pain score, heart rate, systolic and diastolic blood pressure was measured before and after the operation. **Results:** In this observational study total of 50 patients of ASA Grades I, II, III and IV were included who came with hip trauma and were scheduled for hip surgery. The mean age of the study participants was 70.8 years. No significant difference was recorded between pre and posts operative heart rate, systolic and diastolic blood pressures. Only after 24 hrs of the surgery, the pain score reached 3.6. Only 6 patients required rescue analgesia after almost 700 min post-surgery. No such adverse events were recorded for any of the patients. **Conclusion:** This study has shown the PENG

block can be effectively used as a post-operative analgesia in patients undergoing hip trauma surgeries. Moreover, this study has also shown that this technique is simple and safe to use in geriatric patients.

KEYWORDS

Pericapsular nerve group (PENG) block, adverse effect, heart rate, post-operative analgesia, geriatric population

INTRODUCTION

The hip surgery is a common emergency orthopedic condition that is frequently encountered by the physicians. Hip surgery is common for the elderly population with severe hip trauma. According to a recent report, the number of hip trauma cases has been increased significantly in the past decade among the older population¹. In a report published in the UK National Hip Fracture Database (NHFD) it was found that hip fracture is the most common finding in patients who are over 70 years old and the majority of them are females².

In elderly patients, the importance of postoperative analgesia that also has minimum adverse events has significant importance. Usually, in hip surgery patients regional analgesic methods that include nerve blocks are used because of these of their opioid-sparing effects and less adverse postoperative complications³.

In most of the studies conducted in the past different methods of postoperative pain management was described. Studies have advocated using multimodal analgesia in these patients to reduce the postoperative pain⁴. Moreover, studies have also mentioned that in

addition to spinal anesthesia using fentanyl or sufentanil or morphine it was reported that the pain management is not significantly improved⁵.

Recently, in a study by Girón-Arango *et al.*⁶, a new method of peripheral nerve block named pericapsular nerve group or PENG block was used in patients undergoing orthopedic surgery. This is a method of the plane block where the pain pathway is blocked by using a simple injection on the accessory obturator nerve and femoral nerve⁶.

This obturator nerve supply signal to the anterior hip capsule along with two other nerves namely, femoral nerve and the accessory obturator nerve. Previous studies have shown that this section of the hip capsule has a higher amount of nerve supply and can be used as the main target for the analgesia in hip surgery. In a recent study, it was reported that these are three main nerves responsible for innervations of the anterior hip section. Previously many studies have conducted that have shown the effect of femoral nerve supply block in patients undergoing orthopedic surgery⁷.

However, other than a single study conducted on the PENG block in patients undergoing orthopedic surgery no such studies have been done on hip surgery patients. Moreover, to the best of the author's knowledge, none of the studies have evaluated the efficacy of PENG block on the patient undergoing hip surgery. Therefore, his study was carried out to evaluate the efficacy of PENG block in hip trauma patients who are undergoing hip surgery.

MATERIAL AND METHODS

This observational study was conducted in the Department of a service hospital over a period of 04 months in patients with hip trauma including neck of femur fracture, intertrochanteric fractures, etc. The patients who were scheduled for hip surgery within the study period were included in this study. A total of 50 patients were included in the study.

Before the start of the study, ethical clearance was obtained from the institutional ethical committee. The inclusion and exclusion criteria of the study are described below.

Inclusion criteria

Patients with hip fractures were included in this study.

Exclusion criteria

Any patient who was unwilling for the experiment was excluded along with patients who have a previous history of any adverse effect related to the nerve block and patients with neurological disorders.

Informed written consent was obtained from all the patients before their inclusion in the study. All the patients received spinal anesthesia for surgery with 0.5% bupivacaine. After the completion of surgery as a post-operative analgesia, every patient received PENG block (0.25% Ropivacaine with 25 mcg of Dexmedetomidine). Paracetamol IV was given as rescue analgesia after every 8 hrs. In patients who had a pain score of more than 4 tramadol injection is given to relieve pain.

The regional anesthesia was administered in patients in a supine position. A low-frequency ultrasound probe was placed over the anterior inferior iliac spine in a transverse plane. This was then aligned with the pubic ramus. In this way, the femoral artery, iliopsoas muscle and tendon and pectineus muscles were evaluated. After this, a needle (22-gauge, 80 mm) was inserted such as it faces musculofascial plane anteriorly and posteriorly the pubic ramus. The local anesthetic solution was injected in 5 mL increments (total volume 20 mL).

Demographic information, pain score, heart rate and systolic and diastolic blood pressure was measured before and after the operation. The data from this study were collected systematically and were compiled. The compiled data were then analyzed using the SPSS 17.0 software for the relevant conclusion. The data was reported in percentages and numbers. The particulars about the patients including the heart rate, SBP and DBP and pain score was also analyzed in this way.

RESULTS

In this observational study total of 50 patients of ASA Grades I, II, III and IV (Table 1) were included who came with hip trauma and were scheduled for hip surgery. The

Table 1: Distribution of study participants based on ASA class

	Frequency	Percent
I	2	4.0
II	19	38.0
III	20	40.0
IV	9	18.0
Total	50	100.0

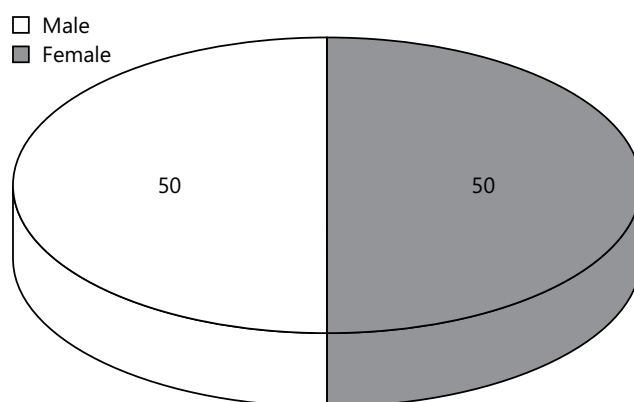


Figure 1: Distribution of study participants based on gender

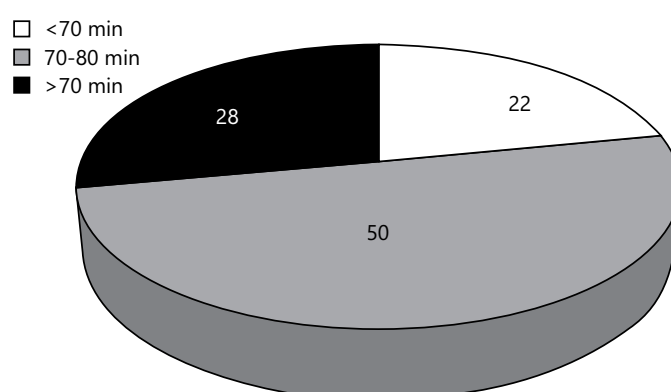


Figure 2: Distribution of study participants based on duration of surgery

Table 2: The descriptive result of pain score

		Postop Pain 0 hrs	Pain 2 hrs	Pain 4 hrs	Pain 6 hrs	Pain 8 hrs
N	Valid	50	50	50	50	50
	Missing	0	0	0	0	0
Mean		1.02	1.50	1.86	2.14	2.22
		Pain 10 hrs	Pain 12 hrs	Pain 14 hrs	Pain 16 hrs	
N	Valid	50	50	50	50	50
	Missing	0	0	0	0	0
Mean		2.56	2.78	2.46	2.70	
		Pain 18 hrs	Pain 20 hrs	Pain 22 hrs	Pain 24 hrs	
N	Valid	50	50	50	50	50
	Missing	0	0	0	0	0
Mean		3.18	3.38	3.56	3.64	

mean age of the study participants was 70.8 years. Among these patients (Figure 1), 25 patients were male (86%) and 25 patients were female (14%). Among these patients maximum of them had surgery duration around 70-80 min (50%) (Figure 2). Only 22% patients had duration of <70 min and 28% had duration of >70 min. The preoperative heart rate, systolic blood pressure and diastolic blood pressure of the study participants showed that a maximum of them had normal blood pressure. Only 7 people had a systolic blood pressure of >140 mm Hg⁻¹.

The post-operative systolic and diastolic blood pressure along with the heart rate of the study participants showed no significant change. Only 16% of the participants had a heart rate that is greater than 80. The mean of post-operative pain score showed that in most of the patient's post-operative mean pain score was in the lower category (Table 2). Only after 24 hrs of the surgery, the pain score reached 3.6 (Figure 3). Only 6 patients required rescue analgesia after almost 700 min post-surgery. No such adverse events were recorded for any of the patients.

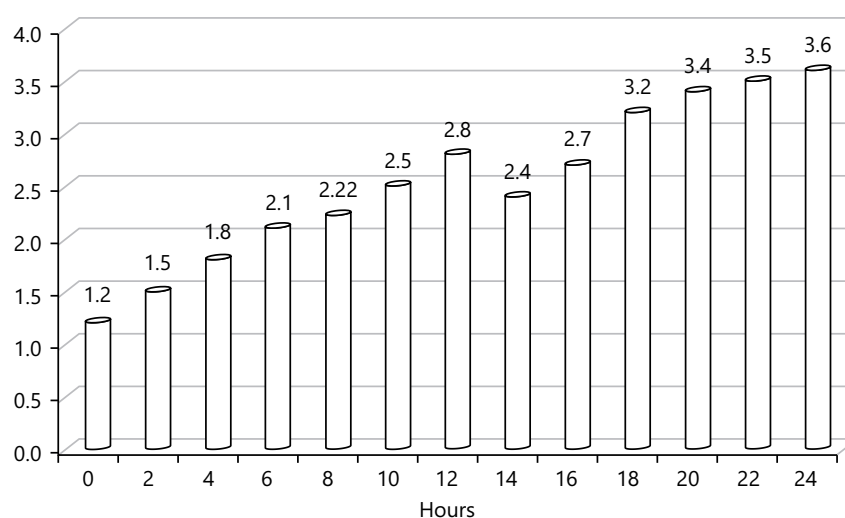


Figure 3: Shows mean pain score at different time interval post-operatively

DISCUSSION

Regional anesthesia methods have been proved to be useful for elderly patients or patients with comorbid conditions. Recently, Peripheral Nerve Blocks (PNB) are extensively used by anesthetists across the globe. Depending on the clinical condition PNBs are used for both perioperative and non-surgical analgesia. These are proved to be having more benefits over neuraxial or General Anesthesia (GA) and provide a superior outcome⁸.

Among the regional anesthesia, the pericapsular nerve (PENG) block is a relatively new anesthetic technique of nerve blockade that has been used by orthopedic surgeons for post-operative analgesia. Recently a study has shown that this method can be successfully used as the post-operative analgesia in patients undergoing orthopedic surgery. However, the study was conducted a small sample size of only 5 patients and hence the limitation of the study was several⁶. The present study has evaluated the effect of PENG block in hip surgery patients. A total of 50 patients were included in this study with a mean age of 70.8 years. This finding indicates that most of this study population is old. This study targeted the articular branches of the accessory obturator nerve and the femoral nerve that lies between the pubic ramus and anterior inferior iliac spine. However, the spread of the local anesthetics in this region was not studied in details and this was beyond the scope of the present research. Another study also shown that PENG blockade can effectively block the femoral and obturator nerve sensation in patients undergoing hip surgery⁹.

The result of this study showed no significant change in the heart rate and systolic and diastolic blood pressure in

patients after surgery. The post-operative pain score has shown that PENG block provides a good post-operative analgesia in combination with paracetamol IV administration. Patients reported a pain score of less than 4 in the first 24 hrs post-surgery. This finding is in accordance with the previous finding of Orozco *et al.*¹⁰. In this study the authors reported a pain score of 3 even after 24 hrs post surgery¹⁰. Moreover, the administration of the PENG block is a simple plane technique that can be administered by using ultrasonography technique.

Previously many studies have pointed out that in geriatric patients post-operative use of opioids results in several adverse events¹¹.

This study has shown that in these patients PENG block can be successfully used as an alternative for post-operative analgesia. Moreover, this nerve block technique targets only the sensory branches of the nerves thereby it has potential motor sensory sparing effects that are reported for previous nerve blockade processes.

The only limitation of the study includes the absence of comparative data where the efficacy of the PENG block can be compared with the efficacy of other established regional anesthesia techniques used for hip surgeries. However, this limitation cannot overshadow the several merits of the study and its huge prospects.

CONCLUSION

This study has shown the PENG block can be effectively used as a post-operative analgesia in patients undergoing hip trauma surgeries. Moreover, this study has also shown that this technique is simple and safe to use in geriatric patients.

CONFLICTS OF INTEREST

The authors declare no conflicts of interest.

FUNDING

The authors did not receive any grant from any commercial, governmental, or non-profit organizations related to this work. The study was self-funded together with contribution from the Institute.

DISCLAIMERS

The opinions expressed in this article are the authors' personal views and do not represent that of their affiliated organizations, employers or associations.

DATA AVAILABILITY STATEMENT

Not Applicable.

AUTHOR CONTRIBUTIONS

SK conceived the review idea. KP conducted the literature search. VS prepared the first draft of the manuscript. KP reviewed, edited and revised the manuscript substantially on the key intellectual content. SK finalized and approved the current version agreed to be accountable for accuracy and integrity and decided to submit the manuscript to Trends in Medical Research.

HIGHLIGHTS OF THE STUDY

- PENG block done with local anaesthetic provides excellent post-op analgesia.
- Hemodynamic stability and very least complications.
- Preprocedural or pain relief on arrival to the hospital.
- Early physiotherapy and mobilization when compared to epidural analgesia.

REFERENCES

1. Fernandez, M.A., X.L. Griffin and M.L. Costa, 2015. Management of hip fracture. *Br. Med. Bull.*, 115: 165-172.

2. Rath, S., L. Yadav, A. Tewari, T. Chantler and M. Woodward *et al.*, 2017. Management of older adults with hip fractures in India: A mixed methods study of current practice, barriers and facilitators, with recommendations to improve care pathways. *Arch. Osteoporosis*, Vol. 12. 10.1007/s11657-017-0344-1.
3. Morrison, S.R., J. Magaziner, M.A. McLaughlin, G. Orosz, S.B. Silberzweig, K.J. Koval and A.L. Siu, 2003. The impact of post-operative pain on outcomes following hip fracture. *Pain*, 103: 303-311.
4. Fabi, D.W., 2016. Multimodal analgesia in the hip fracture patient *J. Orthop. Trauma*, 30: S6-S11.
5. Abou-Setta, A.M., L.A. Beaupre, S. Rashid, D.M. Dryden and M.P. Hamm *et al.*, 2011. Comparative effectiveness of pain management interventions for hip fracture: A systematic review. *Ann. Intern. Med.* 155: 234-245.
6. Girón-Arango, L., P.W.H. Peng, K.J. Chin, R. Brull and A. Perlas. 2018. Pericapsular nerve group (PENG) block for hip fracture. *Reg. Anesth. Pain Med.*, 43: 859-863.
7. Gerhardt, M., K. Johnson, R. Atkinson, B. Snow, C. Shaw, A. Brown and C.T. Vangsness, 2012. Characterisation and classification of the neural anatomy in the human hip joint. *HIP Int.*, 22: 75-81.
8. Attari, M.A., S.A. Mirhosseini, A. Honarmand and M.R. Safavic, 2011. Spinal anesthesia versus general anesthesia for elective lumbar spine surgery: A randomized clinical trial. *J. Res. Med. Sci.*, 16: 524-526.
9. Ueshima, H. and H. Otake, 2018. Pericapsular nerve group (PENG) block is effective for dislocation of the hip joint. *J. Clin. Anesth.*, 52: 83-83.
10. Orozco, S., D. Muñoz, S. Jaramillo and A.M. Herrera, 2020. Pericapsular nerve group (PENG) block for perioperative pain control in hip arthroscopy. *J. Clin. Anesth.*, 59: 3-4.
11. Kim, J.Y., J.H. Kim, J. Yee, S.J. Song and H.S. Gwak, 2018. Risk factors of opioid-induced adverse reactions in elderly male outpatients of Korea Veterans Hospital. *BMC Geriatr.*, Vol. 18. 10.1186/s12877-018-0990-1.